



iJRASET

International Journal For Research in
Applied Science and Engineering Technology



INTERNATIONAL JOURNAL FOR RESEARCH

IN APPLIED SCIENCE & ENGINEERING TECHNOLOGY

Volume: 5 Issue: X Month of publication: October 2017

DOI: <http://doi.org/10.22214/ijraset.2017.10076>

www.ijraset.com

Call: ☎ 08813907089

E-mail ID: ijraset@gmail.com

Effect of Aqueous Extract of Some Indian Medicinal Plants against Aspirin Induced Gastric Ulcer in Rats

Lakshmi Priya.G¹, Dr. Mary Josephine Rani.A², Ragamath Bee.A³, Sandhya. C⁴

^{1, 2, 3, 4} Dept of Zoology, Auxilium college, Vellore, Tamil Nadu, India.

Abstract: *The antiulcer activity of the poly herbal formulation (composed of the leaf extracts from Lantana camara, Annonamuricata, Kalanchoepinnata) was evaluated in aspirin induced ulcer model in rats. The extract at dose of 1000mg/kg produced significant inhibition of gastric lesion induced by above mentioned method. The extract reduced ulcerative lesion, gastric volume, free and total acidity and pH of gastric juice in the model. The result obtained suggesting that extract possesses significant anti-ulcer activity.*

Keywords: *Antiulcer, gastric lesion, Lantana camara, Annonamuricata, Kalanchoepinnata, free acidity, total acidity, ulcer index, gastric juice.*

I. INTRODUCTION

Peptic ulcers are open sores in mucous lining of the stomach and duodenum. The annual mortality rate due to peptic ulcer is low and deaths are largely due its complications such as hemorrhage and perforation (16). The risk of developing an ulcer depends upon the specific type of NSAID, dose, duration of use and individual patient factors (3). The pathogenesis of peptic ulcer is far from clear and so also the mechanism of anti ulcer drugs (1). NSAID stimulate HCl secretion and cause weakness of mucous gel layer which act as barrier by decreasing mucin production and increasing the secretion of bicarbonate from gastric and duodenal mucosa (15). Non steroidalanti inflammatory drugs block COXI activity and reduce gastric mucosal prostaglandin results in decrease mucosal blood flow, decrease secretion of mucus nd bicarbonate (7).

Gastric ulcers are common and serious diseases, which have been a major cause of morbidity and mortality for more than a century (14). The pathophysiology of gastric ulcer disease is based on an imbalance between aggressive and protective factors in the stomach (42). Gastric ulcers are caused by psychological and physiological stress, excessive acid, free radicals, alcohol use, side effect of NSAIDs, Helicobacter infection or free radicals or a combination

of two or more of these causes (13). Currently the NSAIDs such as aspirin and indomethacin are preferred drugs for various diseases like arthritis, inflammation, and cardiovascular protection. However, they cause gastrointestinal complications such as ulcers and erosions. NSAIDs also generates oxygen free radicals that are known to play a role in the pathogenesis of mucosal injury (6). Aspirin exerts its effect through inhibition of cyclooxygenase the enzyme responsible for the synthesis of prostaglandin. The most adverse effect of aspirin is irritation of the gastric mucosa. Various synthetic anti-ulcer drugs are presently available and some of these like misoprostol esomeprazole, omeprazole, lansoprazole, pantoprazole are specifically used to cure the NSAID induced gastric ulcer. However, each of these drugs confers simpler to severe side effects, warranting a search for non-toxic and inexpensive antiulcer medication (22,45).

Peptic ulcer disease is ulceration of mucous membrane penetrating through the muscular is mucosa and occurring in areas bathed by acid and pepsin in stomach and duodenum. If ulceration occurs in stomach it is known as gastric ulcers and when in the duodenum, it is named as duodenal ulcers. Peptic ulcer disease is a common medical emergency with an annual incidence of approximately 100 per 100,000 adults and an overall mortality of 10 to 15% in recent studies. In about two third of cases, the bleeding sources are acid related lesions(44). Peptic ulcer therapy had under gone many studies over past few years and a number of synthetic drugs are now available for treatment. Reports on clinical evaluation of these drugs shows that there are incidence of relapses and adverse effects and danger of drug interactions during ulcer therapy. Hence the search for an ideal anti-ulcer drug continues and has also been extended to herbal drugs in search for new novel molecule which affords better protection and decreases the incidence of relapse. The plant products are becoming more popular than the synthetic drugs due to its low toxicity and effectiveness. According to recent survey, herbal therapy or use of natural products other than vitamins and minerals, was the most commonly used complementary

and alternative medicines (cam) therapy(18.96%). This is mainly attributed due to their long standing experience of exposure of these drugs in ethnic medicine system of Ayurvedha.

The importance of natural phenolic compounds from plants materials is also raising interest due to their redox properties which allow them to act as reducing agents, hydrogen donators and singlet oxygen quenchers. In addition, they have metal chelating properties as well (28, 5). Polyphenolic compounds are secondary plant metabolites found in numerous plant species and they are reported to have multiple functions to counteract the free radicals and they also inhibit different types of oxidizing enzymes (33).

Medicinal plants represent an important source of medically important compounds. Since ancient time, medicinal plants are used to cure several types of health problems. Systemic analysis of these plants provides a variety of bioactive molecules for the development of newer pharmaceutical products. Recently, there is a growing interest in the pharmacological evaluation of various plants used in different traditional system of medicine. In last few decades, many of traditionally known plants have been extensively studied by advanced scientific techniques and reported for various medicinal properties viz, anticancer activity, anti-inflammatory activity, antidiabetic activity, anthelmintic, antibacterial activity, antifungal activity, hepatoprotective activity, antioxidant activity, larvicidal activity etc (31,17,36).

Lantancamaraintroduced in India as an ornamental plant but entirely naturalized and found throughout India. However, it is listed as one of the significant medicinal plants of the world (35).The plant *Lantana camara* (Verbanaceae), generally known as wild or red sage is the most widespread species of this genus and it is a woody straggling plant with various flower colors, red, pink, white, yellow and violet. It is an ever green strong smelling shrub, with stout recurved prickles, leaves opposite, ovate, acute or sub- acute, crenate -serrate, scab rid on both side (40).

A. Scientific classification

Kingdom: Plantae
Order : Lamiales
Family : Verbenacea
Genus : *Lantana*
Species : *camara*

L. camara is a low erect or subscandent vigorous shrub with tetragonal stem, stout recurved prickles and a strong odour of black currents. Plant grows up to 1 to 3 meters and it can spread to 2.5 meter in width. Leaves are ovate or ovateoblong, acute or sub acute crenate serrate, rugose above, scabrid on both sides. The leaves are 3-8 cm long by 3-6 cm wide and green in colour. Leaves and stem are covered with rough hairs. Small flower held in clusters (called umbels). Colour usually orange, sometime varying from white to red in various shades and the flower usually change colours as they age. Flowers are having a yellow throat, in axillary head almost throughout the year. The calyx is small, corolla tube slender, the limb spreading 6 to 7 mm wide and divided into unequal lobes. Stamen four in two pairs, included and ovary two celled, two ovuled. Inflorescences are produced in pairs in the axils of opposite leaves. Inflorescences are compact, dome shaped 2-3 cm across and contain 20-40 sessile flowers. Root system is very strong and it gives out new fresh shoots even after repeated cuttings (37).

Annona muricata L. belongs to the family of Annonaceae has a widespread pantropical distribution and has been proudly known as corossol. It is a widespread small tree and has its native in Central America (2). Intensive chemical investigations of the leaves and seeds of this species have resulted in the isolation of a great number of acetogenins. The isolated compounds display some of the interesting biological or the pharmacological activities, such as antitumoral, cytotoxicity, antiparasitic and pesticidal properties. Roots of these species are used in traditional medicine due to their antiparasitical and pesticidal properties (9).

B. Scientific classification

Kingdom: Plantae-Plants
Class: Magnoliopsida
Order: Magnoliales
Family: Annonaceae
Genus: *Annona*
Species: *muricata*

The genus name 'Annona' is from the Latin word 'anon', meaning 'yearly produce', referring to the fruit production habits of the various species in this genus. *Annona muricata* is a slender, evergreen tree, 5-10 m in height and 15 cm in diameter; trunk straight; bark smooth, dull grey or grey-brown, rough and fissured with age; inner bark pinkish and tasteless; branches at first ascending with the crown forming an inverted cone, later spreading; crown at maturity spherical due to lack of apical dominance; twigs brown or grey, bearing minute raised dots (lenticels); root system extensive and superficial, spreading beyond the diameter of the crown although shallow rooted; juvenile plants have a taproot that is eventually lost. Leaves alternate, 7.6-15.2 cm long, 2.5-7.6 cm wide, leathery, obovate to elliptic, glossy on top, glabrous on underside, simple; stipules absent; blade oblanceolate, green on top, paler and dull on under side with fine lateral nerves; a strong, pungent odour; petioles short, 3-10 mm long (4).

The knowledge of traditional medicine and medicinal plants and their study of scientific chemical principles may lead to the discovery of newer and cheaper drugs. *Kalanchoe pinnata* (Lam., syn. *Bryophyllum pinnatum*, B. calycinum; Local name: Pathorkuchi, Coughpatha; English name: Air plant; Family: Crassulaceae) is an herb found ubiquitously in Bangladesh. It has tall hollow stems, fleshy dark green leaves that are distinctly scalloped and trimmed in red, and bell-like pendulous flowers (10). *Kalanchoe pinnata* (K. pinnata) has become naturalized in temperate regions of Asia, Australia, New Zealand, West Indies, Macaronesia, Mascarenes, Galapagos, Melanesia, Polynesia, and Hawaii. It is also widely distributed in the Philippines, where it is known as *katakataka* or *katakatakawhich* means astonishing or remarkable (10). The leaves of K. pinnata have a variety of uses in the traditional system of medicine in Bangladesh. They are eaten for diabetes, diuresis, dissolving kidney stones, respiratory tract infections, as well as applied to wounds, boils, and insect bites (10). It is useful for preventing alcoholic, viral and toxic liver damages. The aqueous extract of this plant has shown anti-inflammatory, anti-diabetic, anti-tumor and cutaneous leishmanicidal activities (38,39,41,24).

C. Scientific classification

Kingdom: Plantae-Plants

Class: Magnoliopsida

Order: Saxifragales

Family: Crassulaceae stonecrop family

Genus: *Kalanchoe*

Species: *pinnata*

Kalanchoe pinnata (Family: Crassulaceae) is an important plant which has many traditional medicinal uses. *Kalanchoe pinnata* (Family: Crassulaceae) is an erect, succulent, perennial shrub that grows about 1.5 m tall and reproduces through seeds and also vegetatively from leaf buds. It has a tall hollow stems, fleshy dark green leaves that are distinctively scalloped and trimmed in red and dark bell-like pendulous flowers. This plant can easily be propagated through stems or leaf cutting. It is an introduced ornamental plant that is now growing as a weed around plantation crop. K. pinnata is used in ethnomedicine for the treatment of earache, burns, abscesses, ulcers, insect bites, whitlow, diarrhoea and cithiasis (26). In traditional medicine, *Kalanchoe* species have been used to treat ailments such as infections, rheumatism, and inflammation (25) and have immunosuppressive effect as well (21).

II. MATERIALS AND METHODS

A. Collection And Extraction Of The Plant

The leaves of *L. camara*, *A. muricata* and *K. pinnatum* were collected around Vellore district. After washing the plant with running water, the leaves were separated and dried in shade for 20 days at room temperature. After shade drying, the leaves were grinded through blender and converted into coarse powder. The powder was extracted by continuous hot extraction using the Soxhlet apparatus. The extracts were collected and preserved in a desiccator until used for further studies.

B. Test animal

Adult healthy wistar rats weighing 150 g were used and kept in the animal house. The animals were kept in plastic cages (34 × 47 × 18 cm³) at animal house, in an air conditioned environment with four rats in each cage and maintained at room temperature of (25 ± 2) °C with relative humidity (60% ± 10%) under 12 h night and light cycle. The animals used for the experiment were approved by animal ethics committee.

The dose of the test drug was calculated by the method of Miller and Tainter (1944) (23), found to be 1000mg/kg the dose of the extract was calculated with reference, the aqueous extract of the drug was used in the dose of 150mg/kg. Standard drug, Rabepazole (Manufactured in India by Cipla Laboratories Ltd.) was used in the dose of 20mg/kg.

C. Phytochemical analysis

The preliminary phytochemical analysis of *L.camara*, *A.muricata*, *K.pinnata* leaves aqueous extract was carried out for carbohydrate, saponins, flavonoids, triterpenoids, tanins and alkaloids.

D. Acute Toxicity Study

The oral acute toxicity study of aqueous extract of *L.camara*, *A.muricata*, *K.pinnatum* were evaluated according to Organization for Economic Cooperation and Development (OECD) guideline 420 on wistar rats, where the limit test dose of 1000 mg/kg was used. All the animals were kept at overnight fasting before to every experiment with free excess to water. The test drug was administered and observed for 14 days to determine urea, creatinine, SGOT, SGPT level.

III. EXPERIMENTAL DESIGN

The rats were randomly divided into 6 groups, of 4 rats each as follows

Group-I: Control group animals received no treatment.

Group-II: animals received 20mg/kg body weight of Indomethacin (Negative control).

Group-III: animals received 1000 mg/kg body weight of freshly prepared *L.camara*.

Group-IV: animals received 1000 mg/kg bodyweight of freshly prepared *A.muricata*.

Group-V: animals received 1000 mg/kg body weight of freshly prepared *K.pinnatum*.

Group-VI: animals received 20mg/kg body weight of Rabepazole.

All treatments were administered orally for 11 days. Score of mucosal damage were microscopically observed.

A. Histological observation

In the 11th day, after 24 h fasting the animals were sacrificed and stomach of each animal was opened along the greater curvature. Specimens of the gastric tissue were fixed in 10% buffered formalin and were processed in the paraffin tissue-processing machine. Sections of the stomach were sectioned at 5µm and stained with hematoxylin and eosin for histological evaluation (12). Paraffin sections were stained with toluidine blue. The effect of drugs was evaluated through assessment of inflammatory and necrotic changes in the mucosal tissue.

B. Aspirin-induced Gastric Ulceration and Its Protection Studies

Before ulcer induction animals of both control and experimental groups kept separately in standard controlled conditions were fasted for 24 h with free access to water. Acute gastric ulcers were induced by oral administration of aspirin at a dose of 20 mg kg⁻¹ body weight and rats were sacrificed after 4 h of aspirin treatment. The control group received the vehicle only, whereas the experimental group received aspirin for gastric ulceration. After 4 h, the animals were sacrificed, and gastric lesions in the fundic stomach were scored and expressed as ulcer index. *L.camara*, *A.muricata*, *K.pinnata* leaves aqueous extract was administered orally 30 min prior to aspirin treatment to see the gastroprotective effect. Rabepazole were administered orally at a dose of 20 mg/ kg body weight respectively.

C. Assessment of gross mucosal damage

The lesion in the glandular portion was examined under a 10 x magnifying glass and length was measured using a divider and scale and gastric lesion was scored as follows:

Scoring of ulcer was made as follows:

Normal stomach..... (00)

Red coloration..... (0.5)

Spot ulcer..... (01)

Hemorrhagic streak... (1.5)

Ulcers..... (02)

Perforation..... (03)

Ulcer index of each animal was calculated by adding the values and their mean values were determined and percentage inhibition was calculated (20).

D. Formula for Ulcer Protection

$$\% \text{ Protection} = \frac{(\text{Ulcer index Control} - \text{Ulcer index Test})}{\text{No. of Animals}} \times 100$$

E. Determination of pH and volume of gastric juice

Gastric juice (1 mL) was diluted with 1 mL distilled water and was measured using a pH meter and the volume of gastric juice also measured by measuring tubes.

F. Free and Total Acidity

Free and total acidity were determined by titrating with 0.01 N NaOH using Topfer's reagent and phenolphthalein as indicator. The free and total acidity were expressed as $\mu\text{equiv}/100 \text{ g}$.

$$\text{Acidity} = \frac{\text{Volume of NaOH} \times \text{Normality of NaOH} \times 100}{0.1 \text{ N}}$$

IV. RESULTS

A. Preliminary phytochemical screening

The phytochemical screening of the plant extract revealed the presence of various bioactive constituents like alkaloids, flavonoids, saponins and tanins.

B. Acute Toxicity Study

The oral acute toxicity study of aqueous extract of *L.camara*, *A.muricata*, *K.pinnatum* Were evaluated according to Organization for Economic Cooperation and Development (OECD) guideline 420 on wistar rats, where the limit test dose of 1000 mg/kg was used. No mortality observed for 14days.

C. Aspirin-induced Gastric Ulceration

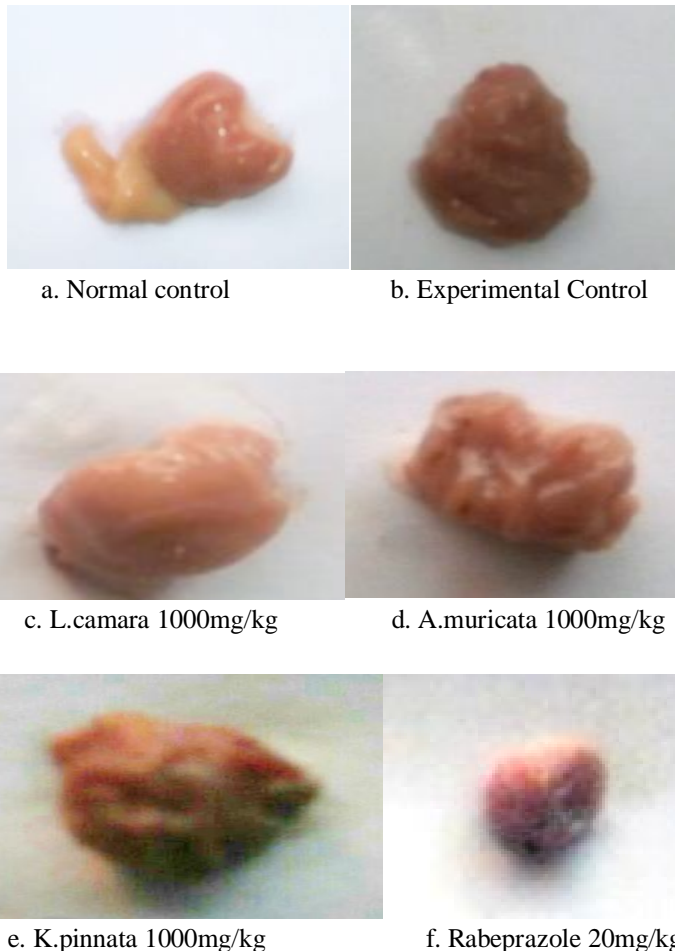
In the present study the anti-ulcer activity of leaves of *L.camara*, *A.muricata*, *K.pinnatum*. Revealed that the minimum ulcer index was observed with Rabeprazole.

Table:1 Effect of *L.camara*, *A.muricata*, *K.pinnatum* leaves aqueous extract gastric juice volume, pH, total acidity, free acidity, total ulcer index and ulcer protection.

Group	Gastricjuice volume in ml	Gastricjuice pH	Free acidity (mEq/dl)	Total acidity (mEq/dl)	TotalUlcer index	Ulcer protection(%)
Control	3.78±0.12	3.1±0.30	54.6±0.04	61.35±0.06	0.01±0.00	99
Disease control	1.1±0.04	1.35±0.07	96.12±0.88	117.32±1.25	3.87±0.19	9
<i>L.camara</i> 150mg/kg	1.62±0.12	1.75±0.07	40.35±1.10	69.14±2.18	2.15±0.19	48
<i>A.muricata</i> 150mg/kg	2.47±0.19	2.04±0.17	27.53±0.74	53.5±0.91	1.85±0.19	54
<i>K.pinnata</i> 150mg/kg	2.32±0.07	2.55±0.09	25.15±0.86	50.27±0.86	1.62±0.12	75
Rabeprazole 20mg/kg	3.43±0.09	3.32±0.12	29.6±1.89	49.05±1.18	1.22±0.09	87

Values are expressed as mean \pm SEM. $P > 0.05$ when compared to normal control group by Statistical analysis by One-way ANOVA followed by Dunnett's method.

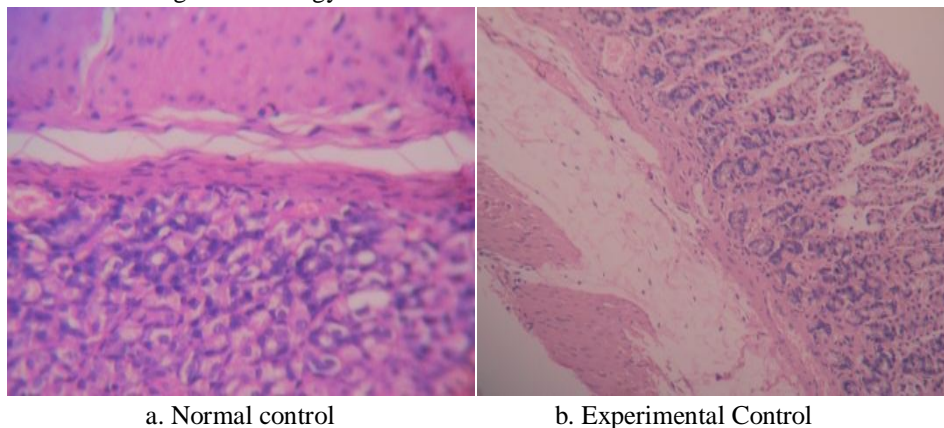
Fig: 9 Morphological Features of Stomach in Ethanol Induced Ulcer

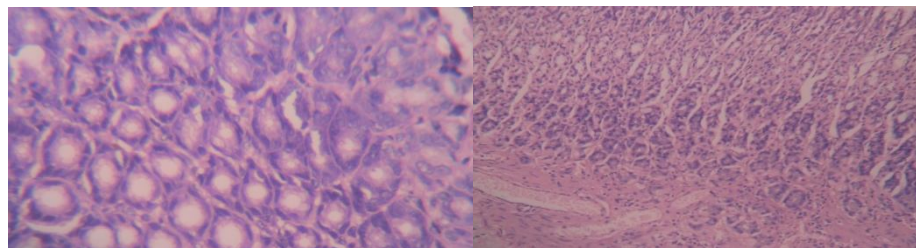


D. Morphological study of stomach

In normal group stomach integrity was maintained and appeared normal. In control group severe bleeding, perforation, spot ulcer were observed but, in standard group and extract treated groups, animal showed less ulceration and stomach integrity was maintained.

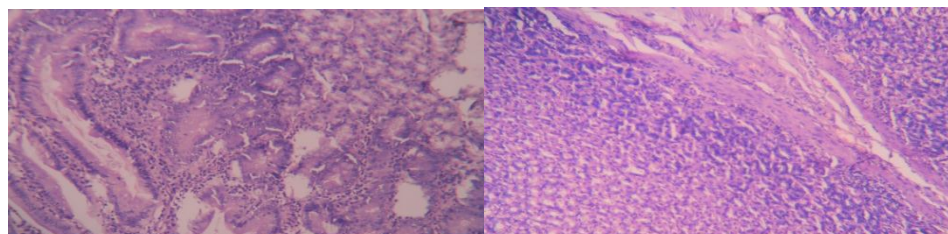
Fig: 11 Histology of Stomach in Indomethacin induced Ulcer





c. L.camara 1000mg/kg

d. A.muricata 1000mg/kg



e. K.pinnata 1000mg/kg

f. Rabeprazole 20mg/kg

E. Histopathological study

Histopathological examination of gastric mucosa in the normal control group showed intact gastric mucosa and continuous epithelial surface. Experimental control revealed mucosal ulceration. In L.camara (1000mg/kg) group, superficial erosions and few ulcers accompanied with mild inflammatory was observed. In A.muricata (1000mg/kg) group, slight ulcer with inflammatory infiltrate and congestion in few areas was observed. In K.pinnata (1000mg/kg) group, section revealed intact mucosa with no inflammation. In Rabeprazole (20mg/kg) group, showed intact gastric mucosa without any inflammatory.

V. DISCUSSION

Phytochemical analysis on the leaves aqueous extract gave positive results for flavonoids, alkaloids, saponins, carbohydrate, tanins and triterpens. The obtained results strongly suggest that flavonoids and alkaloids are the major components of the extract and therefore some of the pharmacological effects could be attributed.

The anti-ulcer activity of the leaves aqueous extract of L.camara, A.muricata, K.pinnatum was evaluated against gastric lesions induced by Indomethacin. The use of nonsteroidal anti-inflammatory drugs (NSAIDs) is considered to be the major risk factor in gastric ulcers. The mechanisms suggested for the gastric damage caused by NSAIDs are inhibition of prostaglandin synthesis and inhibition of epithelial cell proliferation in the ulcer margin, which is critical for the re epithelization of the ulcer crater (18). There has been a considerable interest in finding natural antioxidants from plant materials to replace synthetic ones for effective management of therapeutic drug toxicity such as peptic ulcer (30).

The volume of acid present in gastric secretion which encompasses HCl, pepsinogen, mucus, biocarbonates, intrinsic factor and protein reflects acid volume. Exposure of unprotected lumen of the stomach to accumulating acid could facilitate ulceration (27). Another major aggressive factor responsible for ulcers is the content of acid present in gastric juice. Over secretion of histamine contributes to increased secretion of gastric juice (11). When the concentration of hydrogen ions in gastric juice decreases, it is reflective of high pH. The genesis of ulcer and gastric damage is facilitated by hydrogen ions which serve as another aggressive factor (19).

These results could be explained by that prostaglandins normally protect the gastrointestinal mucosa from damage by maintaining blood flow and increasing mucosal secretion of mucous and bicarbonate

(43). Synthetic non-steroidal anti-inflammatory (NSAIDS) like aspirin causes mucosal damage by interfering with prostaglandin synthesis, increasing acid secretion and block diffusion of H⁺ (34). Aspirin blockade of cyclooxygenase-1 (Cox-1) and (Cox-II) results in reduction of prostaglandin synthesis. The interruption of prostaglandin synthesis results in impairment of mucosal damage repair, thus facilitating mucosal injury (7). Aspirin and related non-steroidal anti-inflammatory drugs and alcohol can aggravate or interfere with the healing of peptic ulcers.

Oral administration of RABI (Rabeprazole) significantly reduced ulcer index, gastric juice free and total acidity and pepsin activity. However, the drug has not produced any significant quantitative change in the mucin content. Rabeprazole was reported to significantly increase the production of mucin (a defense factor) in rats. It prevented or reduced the size of gastric ulcers. Rabeprazole caused dose-dependent inhibition of the gastric proton pump. It causes dose-dependent inhibition of acid secretion and has a more rapid onset of indomethacin-induced ulceration. R(+)-rabeprazole appears to be the major isomer having anti-ulcer activity (8).

Gastric mucus (mucin) is an important protective factor for the gastric mucosa and consists of a viscous, elastic, adherent and transparent gel formed by 95% water and 5% glycoproteins that cover the entire gastrointestinal mucosa. Moreover, mucus is capable of acting as an antioxidant, and thus can reduce mucosal damage mediated by oxygen free radicals (32). The protective properties of the mucus barrier depend not only on the gel structure but also on the amount or thickness of the layer covering the mucosal surface (29).

VI. CONCLUSION

Herbal products are well thought-out to be symbols of safeguard in comparison to the synthetic product that are regarded as unsafe to human life and environment. While herbs had been prized for their medicinal significance. The three plants extracts and anti-ulcer drug that RABI compared. Among these, the anti-ulcer drug Rabeprazole and *K.pinnatum* were more effective than the *L.camara*, *A.muricata*.

REFERENCE

- [1] Akimoto, M., H. Hashimoto, M. Shigemoto and I. Yakoyama. Relationship between recurrence of gastric ulcer and the microcirculation. *J. Cardiovascul. Pharmacol.* 1998; 31(1):5507.
- [2] AlassaneWele, Yanjun Zhang, ChristelleCaux, Jean-Paul Brouard, Jean-Louis Pousset, Bernard Bodo, Annonamuricin C., "A novel cyclohexapeptide from the seeds of *Annonamuricata*", *C R Chimie*, 2004; 7: 981-988.
- [3] Andrew H.S., M.W. Wilfred, K. John, and D. McCarthy. Nonsteroidal Anti-inflammatory Drugs and Peptic Ulcer Disease. *Ann Intern Med.* 1991; 114: 307-319.
- [4] Anon., "The useful plants of India", Publications & Information Directorate, CSIR, New Delhi, India, 1986.
- [5] Apak R, Guclu K, Demirata B, et al. Comparative evaluation of various total antioxidant capacity assays applied to phenolic compounds with the CUPRAC assay. *Molecules* 2007; 12(7): 1496-1547.
- [6] Biswas K, Bandyopadhyay U, Chattopadhyay I, Varadaraj A, Ali E, Banerjee RK et al. A novel antioxidant and antiapoptotic role of omeprazole to block gastric ulcer through scavenging of hydroxyl radical. *Journal of Biological Chemistry* 2003; 278:10993-11001.
- [7] Burke, A., E. Smyth and G.A. Fitzgerald. Analgesic-Antipyretic Agents, Pharmacotherapy of Gout. In: Brunton, L.L., J.S. Lazo and K.L. Parker (Eds.), Goodman and Gilman. *Pharmacological Bases of Therapeutics*. 11th Edn., McGraw Co. Inc., New York, 2006; 671-715.
- [8] Cao H, Wang M, Jia J, Wang Q, Cheng M. Comparison of the effects of pantoprazole enantiomers on gastric mucosal lesions and gastric epithelial cells in rats. *Health Sci* 2004; 50:1-8.
- [9] Christophe Gleye, Alain Laurens, Reynald Hocquemiller, Olivier Laprevote, Laurent Serani and Andre Cave, Cohibins A and B., "Acetogenins from roots of *Annonamuricata*", *Phytochemistry*, 1997; 44(8): pg1541 -1545.
- [10] Ghani A. "Monographs of the recorded medicinal plants", Medicinal Plants of Bangladesh. 2nd ed. Asiatic Society of Bangladesh, 2003; p. 271-272.
- [11] Grossman, M.I. Control of gastric secretion in gastrointestinal disease, Patho physiology- diagnosis and management. Sleisenger, M.H, Fordtran, J.S., editors. 2nd ed. W B Saunders Co, Philadelphia. 1978; p.640-659.
- [12] Hajrezaie M, Golbabapour S, Hassandarvish P, Gwaram NS, Hadi AH, Ali HM, et al., Acute toxicity and gastroprotection studies of a new Schiff base derived copper(II) complex against ethanol induced acute gastric lesions in rats. *PLoSOne* 2012; doi: 10.1371/journal.pone.0051537.
- [13] Hrbison SP, Dempsey DT. Peptic ulcer disease. *Current problems in surgery* 2005; (42):346-454.
- [14] Hogerwerf WA, Pasricha PJ. Pharmacotherapy of Gastric Acidity, Peptic Ulcers, and Gastroesophageal reflux Disease, The pharmacological basis of therapeutics, McGraw-Hill Company. New York, 2006; 967-981.
- [15] Huang, J.Q., S. Scidher and R.H. Hunt. Role of *Helicobacter pylori* infection and non steroidal anti inflammatory drugs in peptic ulcer. *Ameta-Analysis. ancet.* 2002; 539 (9300): 14-22.
- [16] Iseberg, J.I. and A.H. Soll, 1996. Epidemiology, Clinical Manifestation and Diagnosis of Peptic Ulcer. In *Cecil Textbook of Medicine*, Bonnet, J.C. and F.P. Flum (Edn.). Vol. 2, 20th Edn., W.B. Publ. Sounder Company, USA, pp: 664.
- [17] Kumar SV, Sankar P and Varatharajan R. Anti-inflammatory activity of roots of *Achyranthes aspera*. *Pharmaceutical Biology*. 47 (10); 2009: 973-975.
- [18] Levi, S., Goodlad, R.A. and Lee, C.Y. Inhibitory effect of NSAIDs on mucosal cell proliferation associated with gastric ulcer healing. *Lancet*. 1990; 336(8719):840-843.
- [19] Lüllmann, H., Mohr, K., Ziegler, A. and Bieger, D. *Color Atlas of Pharmacology*. 2nd ed. Thieme Stuttgart, New York. 2000; p.166.
- [20] Malairajan P, Gopalakrishnan G, Narasimhan S, Veni K.J, Kavimani S. *J. Ethnopharmacol.*, 2007; 110, 348-351.
- [21] McKenzie RA, Dunster PJ., "Hearts and flowers: Bryophyllum poisoning of cattle", *Aust. Vet. J.*, 1986; 63: 222.
- [22] Miederer SE. Will Anti-ulcer Drugs Differ only in their Side Effects? *Fortschritte Medicine* 1986; (104):918-920.
- [23] Miller L C and Tainter M L, *Proc. Soc Expt. Biol, Med*, 1944; 57-261

- [24] Muzitano MF, Falcão CAB, Cruz EA, Bergonzi MC, Bilia AR, Vincieri FF, et al., "Oral metabolism and efficacy of Kalanchoepinnataflavonoids in a murine model of cutaneous leishmaniasis", *Planta Med*, 2009; 75: 307-11.
- [25] Nayak BS, Marshall JR, Isitor G., "Wound healing potential of ethanolic extract of KalanchoepinnataLam. Leaf-A preliminary study", *Indian J. Experim. Biol*, 2010; 48: 572-576.
- [26] Okwu DE, NnamdiFU., "Two novel flavonoids from Bryophyllumpinnatumand their antimicrobial Activity", *J. Chem. Pharm. Res*, 2011;3(2):1-10.
- [27] Olsen, C.E. Glutathione modulates toxic oxygen metabolite injury of canine chief cellmonolayers in primary culture. *Am. J. physiol*. 1988; 254: G49-G56.
- [28] Ozsoy N, Candoken E, Akev N. Implications for degenerative disorders: antioxidative activity, total phenols, flavonoids, ascorbic acid, beta-carotene and beta-tocopherol in *Aloe vera*. *Oxid Med Cell Longev* 2009; 2(2): 99-106.
- [29] enissi, A. and Piezzi, R. Effect of dehydroleucodine on mucus production: A quantitative study. *Dig. Dis. Sci*. 1999; 44 (4):708-712.
- [30] Pratt, D.E. Natural antioxidants from plant material. In: Huang, I.M.T., Ho, C.T., Lee, C.Y., editors. *Phenolic compounds in food and their effects on health*. New York: American Chemical Society. 1992; p.54-72.
- [31] Rajkumar V et al. Evaluation of cytotoxic potential of *Acoruscalamus*rhizome. *Ethnobotanical Leaflets*. 13 (6); 2009: 832-839.
- [32] Repetto, M.G. and Llesuy, S.F. Antioxidant properties of natural compounds used in popularmedicine for gastric ulcers. *Braz. J. Med. Biol. Res*. 2002; 35(5):523-534.
- [33] Rezaeizadeh A, Zuki ABZ, Abdollahi M. Determination of antioxidant activity in methanolic and chloroformic extracts of *MomordicaCharantia*. *Afr J iotech.*, 2011; 10 (24): 4932-4940.
- [34] Roa, C.V., R.N. Maiti and R .K. Goel. Effect of mid irritant on gastric mucosal offensive and defensive factors. *Med. J. Physiol. Pharmacol*. 1999; 44:185-191
- [35] Ross IA., "Medicinal plants of the world. Chemical constituents, traditional and modern medical uses", New Jersey, Humana Press, 1999.
- [36] Sabu MC and Kuttan R. Anti-diabetic activity of medicinal plants and its relationship with their antioxidant property. *Journal ofEthnopharmacology*. 81 (2); 2002; 155-160.
- [37] Sastri BN., "The wealth of India", CSIR New Delhi, India. 1962.
- [38] Sidhartha PA, ChandhuriKW., "Anti-inflammatory action of Bryophyllumpinnatumleaf extract", *Fitoterapia*, 1990; 41: 527-533.
- [39] Supratman UT, Fujita K, Akiyama H, Hayashi A, Murakami H, Sakai K, et al., "Anti-tumor Promoting Activity of Bufadienolides from *Kalanchoepinnata*and *K. daigremontianabutiflora*", *BiosciBiotechnolBiochem*, 2000; 165: 947-949.
- [40] Thamotharan G, Sekar G, Ganesh T, Saikatsen, Raja Chakraborty, Senthil.kumar N., "Antiulcerogenic effect of *Lantana camara*Leaves on in vivo test models in Rats", *Asian. Jour. Pharm.Clinical. Res*, 2010; 3: 57-60.
- [41] Torres-Santos ECS, Da Silva AG, Costa APP, Santos APA, Rossi- Bergmann B., "Toxicological analysis and effectiveness of oral *Kalanchoepinnata*on a human case of cutaneous leishmaniasis", *Phytother Res*, 2003; 17: 801-803.
- [42] Vell V. Drug-induced Peptic Ulcer Disease. *MCP* 2005; 10:15-19.
- [43] Voutilainen, M., T. Mantynen, M. Farkkila, M. Juhola and P. Syponene. Impact of non steroidal anti-inflammatory drug and aspirin use on the prevalence of dyspepsia and uncomplicated peptic ulcer. *Scand J. Gastroenterol*. 2001; 36(8): 817-821.
- [44] Wang J. Gastro intestinal mucosal repair and Experimental therapeutics. *Frontiers of gastro intestinal res* 2002;25:251.
- [45] Yesilada E, Gurbuz I. In: A Compilation of the studies on the antiulcerogenic effects of medicinal plants in recent progress in medicinal plants. *Phytochemistry and pharmacology* 2003; 2:111-174.



10.22214/IJRASET



45.98



IMPACT FACTOR:
7.129



IMPACT FACTOR:
7.429



INTERNATIONAL JOURNAL FOR RESEARCH

IN APPLIED SCIENCE & ENGINEERING TECHNOLOGY

Call : 08813907089  (24*7 Support on Whatsapp)