



# **iJRASET**

International Journal For Research in  
Applied Science and Engineering Technology



---

# **INTERNATIONAL JOURNAL FOR RESEARCH**

IN APPLIED SCIENCE & ENGINEERING TECHNOLOGY

---

**Volume: 2      Issue: XII      Month of publication: December 2014**

**DOI:**

**[www.ijraset.com](http://www.ijraset.com)**

**Call: ☎ 08813907089**

**E-mail ID: [ijraset@gmail.com](mailto:ijraset@gmail.com)**

# Analysis of Human Retinal Images for Automated Glaucoma Screening

Prakash.H.Patil<sup>1</sup>, Seema.V.Kamkhedkar<sup>2</sup>

<sup>1</sup>Professor, <sup>2</sup>Research scholar, <sup>1,2</sup>Department of Electronics & Telecommunication,  
Indira College of Engineering & Management, Pune, India

**Abstract** — Automatic retinal image analysis is emerging and important screening tool for early detection of eye diseases. Glaucoma is chronic & progressive eye disease that damages the optic nerve due to increase in intraocular pressure of eye. It is the second leading cause of blindness globally. Current tests which are used to detect Glaucoma using intraocular pressure (IOP) are not sensitive enough for population based glaucoma screening. The assessment of Optic nerve head damage in retinal fundus images is more promising and superior. The manual examination of optic disc (OD) is a standard procedure used for detecting glaucoma. In this paper we proposes a system of automatic optic cup and optic disk segmentation using super pixel classification for glaucoma screening. The SLIC (Simple Linear Iterative Clustering) algorithm is incorporated to segment the fundus retinal image into compact and nearly uniform super pixels. It divides an image into a grid of regular pixels, as super pixels have the important property of preserving local boundaries. For optic disk & optic cup segmentation K-means clustering pixel technique, Gabor wavelet transform & thresholding is used. Then segmented optic disc and optic cup are used to compute the cup to disc ratio for glaucoma screening. The Cup to Disc Ratio (CDR) of the color retinal fundus camera image is the primary identifier to confirm Glaucoma for a given patient.

**Keywords** — CDR, Fundus Image, Gabor Filter, Glaucoma, Intraocular pressure, Optic disc, Segmentation

## I. INTRODUCTION

### A. Overview of Glaucoma

Glaucoma is a chronic eye disease in which optic nerve is progressively damaged. it slowly starts to cause sight loss. In its early stages, there is no pain and patients often have no symptoms. Over time glaucoma starts to affect your side/peripheral vision and slowly works its way to the middle if left undetected [1]. According to World Health Organization (WHO), Glaucoma is the second leading cause of vision loss; that contributes to approximately 5.2 million cases of blindness (15% of total blindness cases reported) and can potentially affect ~80 million people in the next decade [2]. To date, there is no cure for glaucoma. Fortunately, it is usually a slow progressing condition, and if it is detected early, it can be treated successfully. Early detection is key for preventing sight loss. It is characterized by the progressive degeneration of optic nerve fibers and leads to structural changes of the optic nerve head, which is known as optic disk, the nerve fiber layer and a simultaneous functional failure of the visual field. Progression of the disease leads to loss of vision, which occurs gradually over a long period of time. As the symptoms only occur when the disease is quite advanced, so glaucoma is called as silent thief of sight. Glaucoma cannot be cured, but its progression can be slowed down by treatment. Therefore, detecting glaucoma in time is critical. However, many glaucoma patients are unaware of the disease until it has reached its advanced stage. In India, there are now an estimated 12 million people affected by glaucoma, the majority of whom are undiagnosed. By 2020, this is expected to be 16 million.[1]. Since glaucoma progresses with few signs or symptoms and the vision loss from glaucoma is irreversible, screening of people at high risk for the disease is vital.

### B. Existing System

Currently, ophthalmologists use three methods to detect glaucoma. One is the assessment of increased pressure inside the eyeball. Second is the assessment of abnormal vision The third method is assessment of the damage to the head of the optic nerve The first method is not sensitive enough to detect glaucoma early and is not specific to the disease, which sometimes occurs without increased pressure. The assessment of abnormal vision requires specialized equipment rendering it unsuitable for widespread screening. It is the most reliable but requires a trained professional and is time consuming, expensive and highly subjective. Third assessment of the damaged optic nerve head is more promising and superior to IOP measurement or visual field testing for glaucoma diagnosis. Optic nerve head assessment can be done by a trained professional [3].

### C. Proposed System

In this paper, we proposes analysis of human retinal images for automated Glaucoma screening based on superpixel classification in which optic disc and optic cup are segmented for Glaucoma diagnosis. The technique uses SLIC (Simple Linear Iterative Clustering) algorithm that divides the images into hundreds of segments called superpixels and classifies each

## International Journal for Research in Applied Science & Engineering Technology (IJRASET)

segment as part of either the optic cup or the optic disc[5]. In this for automatic optic nerve head assessment we can use the image features for a binary classification between glaucomatous and healthy subjects. These features are normally computed at the image level. Cup to disc ratio (CDR) is commonly used because of its accuracy and simplicity. When CDR is greater than 0.65 then it indicates a high risk of glaucoma and can be then tested using other techniques to confirm the disease [10]. Currently 2D color fundus images are still referred to by most clinicians the 3-D images are not easily available, Due to high cost of obtaining 3-D images make it inappropriate for a large-scale screening program. This paper focuses on automatic glaucoma assessment using CDR from 2-D fundus images. The CDR is computed as the ratio of the vertical cup diameter (VCD) to vertical disc diameter (VDD) clinically. Figure 1.shows major structures of the optic disc in this region enclosed by the blue line is the optic disc; the central bright zone enclosed by the red line is the optic cup; and the region between the red and blue lines is the neuroretinal rim.

The paper is organized as follows. Section I describes about Overview of glaucoma, Existing & Proposed system. Section II deals with problem definition. Section III discuss about the various stages of the proposed system . Section IV shows experimental results. Conclusion and future work is presented in section V. Acknowledgement is given in section VI.

### II. PROBLEM STATEMENT

An early detection of glaucoma is particularly significant as it allows timely treatment to prevent major visual field loss. A functional test through vision loss requires special equipments only present in territory hospitals and therefore unsuitable for screening. The diagnosis of glaucoma can be done through measurement of CDR (cup-to-disc ratio). Currently, CDR evaluation is manually performed by trained ophthalmologists or expensive equipment such as Heidelberg Retinal Tomography (HRT). However, CDR evaluation by an ophthalmologist is subjective and the availability of HRT is very limited. Thus, this paper proposes an intuitive, efficient and objective method for automatically classifying digital fundus images into either normal or glaucomatous types in order to facilitate ophthalmologists.

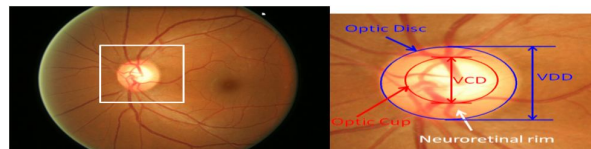


Figure 1. Major structures of the optic disc

### III. LITERATURE SURVEY

Several studies are reported in literature for detection of optic disk and detection and classification of glaucoma. The work is as follows:

- A. R. bock et al. [4], proposes a novel automatic acquisition of glaucoma detection system is inexpensive and widely circulated on digital color fundus images using a cataract after preprocessing various specific generic feature types a narrowed decrease presence-based technology dimension
- B. J. Meier et al. [5], proposes a set of features that are computed from the Colour Fundus Imaging (CFI) and two-class classification is employed to declare a given image as normal or glaucomatous. These features are computed at the image-level without performing OD and cup segmentation selection of features and classification strategy is difficult and challenging.
- C. Osareh et al. [6], proposed a method based on template matching for localizing the center of optic disc. In this algorithm, some of retinal images in dataset were used to create a template and the correlation between each image and template is computed. The point which has the maximum correlation value is selected as the center of optic disc.
- D. Zhuo Zhang et al. [7], presented work on An Online Retinal Fundus Image Database for Glaucoma Analysis and Research which aims to share clinical retinal images with the public. Author had updated the system continuously with more clinical ground-truth images.
- E. Gopal Joshi et al. [8], proposes a disk parameterization with monocular CFI in which a monocular CFI gives a 2-D projection of retinal structures where OD appears as a bright circular or elliptic region partially occluded by blood vessels which highlight both optic cup & optic disk regions.
- F. R. Geetha Ramani et al. [9] , performed a work, Automatic Prediction of Diabetic Retinopathy and Glaucoma through Retinal Image Analysis and Data Mining Techniques This paper proposed a novel approach for automatic disease detection. Retinal image analysis and data mining techniques are used to accurately categorize the retinal images as either

## International Journal for Research in Applied Science & Engineering Technology (IJRASET)

Normal, Diabetic Retinopathy and Glaucoma affected.

- G. K. Narasimhan et al. [10] proposed a semi automated method for glaucoma detection using CDR and ISNT ratio of a fundus image.
- H. T. Nakagawa, A. Sawada et al. [11], proposed work on glaucoma detection with disk parameterization using stereo CFI, OD and cup regions are segmented to estimate the relevant disk parameters. As against monocular CFI, a stereo set of CFI allows capture of partial depth information which helps in better characterizing the region inside the OD such as the cup, neuroretinal rim .and Considerable body of work in disk parameterization has been carried out using stereo CFI.
- I. M. L. Huang et al.[12] Adaptive neuron-fuzzy inference system (ANFIS) normal and glaucomatous eyes optical coherence tomography (OCT) in Chinese Taiwan Stratus summary data report quantitative assessment on the basis of the difference between developing an automatic classifier, Adaptive neuron fuzzy inference system using glaucoma screening introduced populations.

### IV. PROPOSED METHODOLOGY

This paper focuses on automated glaucoma diagnosis using Cup to disk ratio(CDR) from 2D fundus images. This paper proposes superpixel classification based disc and cup segmentations for glaucoma screening. In this proposed approach, preprocessing such as image filtration, color contrast enhancement are performed which is followed by a combined approach for image segmentation and classification using texture, thresholding and morphological operation. Multimodalities including K-Means clustering, Gabor wavelet transformations are also used to obtain accurate boundary delineation. We incorporate prior knowledge of the cup by including location information for cup segmentation. Based on the segmented disc and cup, CDR is computed for glaucoma screening [8]. The framework for proposed system is as shown in figure 1.

In this , firstly the image level and data level processing are carried out in order to analyze the glaucoma risk of a patient. In image level processing fundus eye image is used as input. Fundus image processing involves preprocessing and feature extraction. Image level classification makes use of SVM classifier and classify image as normal or glaucoma suspect. Data level processing uses patient's personal data as input.

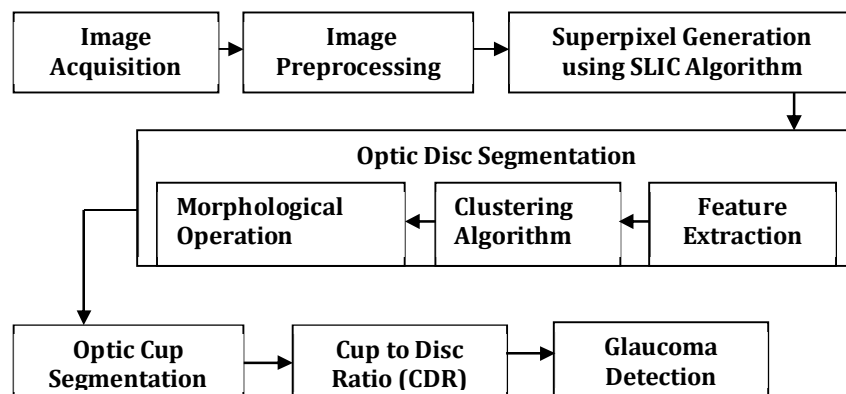


Fig 1. Block Diagram of Proposed System

The risk calculator is used for patient data analysis. Patient data involves age, race, family history and medical examination records of the person being examined. Data level classification classifies the patient into one of the three classes, low risk, medium risk, high risk. The results of image level classification and data level classification is used for final glaucoma risk analysis [11].

#### A. Image Preprocessing

Firstly Input image is taken from Fundus camera for analyzing retina image. The fundus eye image represents the interior surface of the eye and is used as the input for processing. A sample input image is shown in Fig 2

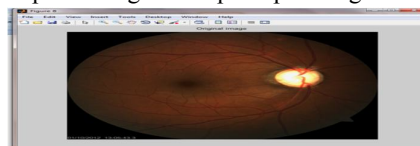


Figure 2. Input color fundus Image.



## International Journal for Research in Applied Science & Engineering Technology (IJRASET)

Image Preprocessing, involves preparing the images for feature selection and correspondence. first we have to enhance the image that we are going to use. We can either apply basic filter techniques or we can use histogram equalization techniques for image enhancement [10]. Image Processing involves adjustment, noise removal, and segmentation can be performed by preprocessing. When pixel sizes in the images to be registered are different but known, one image is resample to the scale of the other image.

We also found some techniques to generate too noisy images for glaucoma detection (histogram equalization adaptive histogram equalization or color normalization). Thus, we have selected methods which are well-known in medical image processing and preserve image characteristics [12]. Naturally, the proposed system can be improved in the future with adding new methods. In detecting abnormalities associated with fundus image, the images have to be preprocessed in order to correct the problems of uneven illumination problem, nonsufficient contrast between exudates and image background pixels and presence of noise in the input fundus image. Preprocessing method also responsible for color space conversion and image size standardization for the system. One of the problems associated with fundus images is uneven illumination i.e. some areas of the fundus images appear to be brighter than the other. Areas at the centre of the image are always well illuminated, hence appears very bright while the sides at the edges or far away are poorly illuminated and appears to be very dark. In fact the illumination decreases as distance from the centre of the image increase[13]. Many methods were tried in resolving this problem of un-even illumination, among which are the use of Naka Rushton method and Adaptive Histogram Equalization Method (AHM). AHM gives better performance, higher processing speed and work well for all images of different sizes, hence the reason for it being used as method of correcting un-even illumination.

### *B. Superpixel generation*

Many algorithms are proposed for superpixel classification. It is useful in image segmentations in various images of human, scene, animal etc. The superpixel algorithms represent a very useful and increasingly popular preprocessing step for a wide range of computer vision applications. The grouping of spatially coherent pixels sharing similar low-level features leads to a major reduction of image primitives, which results in an increased computational efficiency[14].

In this paper, we proposed the simple linear iterative clustering algorithm (SLIC) to aggregate nearby pixels into superpixels in retinal fundus images. Compared with other superpixel methods, SLIC is fast, memory efficient and has excellent boundary adherence. SLIC is also simple to use with only one parameter, i.e. the number of desired superpixel  $k$ . We introduced a new superpixel algorithm, which adapts a k-means clustering technique which efficiently generate superpixels. Along with its simplicity, SLIC adheres to boundaries which better than previous methods. At the same time, it is faster and more memory efficient, improves segmentation performance and is straightforward to extend to superpixel generation. SLIC is simple to use and understand i.e. the number of desired superpixels  $k$ . In SLIC,  $k$  initial cluster centers  $C_k$  are sampled on a regular grid spaced by  $S = \frac{\sqrt{N}}{k}$  pixels apart from the image with  $N$  pixels. The centers are first moved towards the lowest gradient position in a  $3 \times 3$  neighborhood then clustering is applied [15]. For each  $C_k$ , SLIC iteratively searches for its best matching pixel from the  $2s \times 2s$  neighborhood around  $C_k$  based on color and spatial proximity and then compute the new cluster centre based on the found pixel. The iteration continues until the distance between the new centers and previous ones is small enough. Finally, a post-processing is applied to enforce connectivity.

### *C. Optic disc segmentation*

Localization and segmentation of disc are very important in many computer aided diagnosis systems, including glaucoma screening. The localization focuses on finding an disc pixel, very often the centre. It is studied for applications in diabetic screening [13]. Our work focuses on the segmentation problem and the disc is location, The segmentation estimates the disc boundary, which is a challenging task due to blood vessel occlusions, pathological changes around disc, variable imaging conditions, etc. Feature Extraction techniques like clustering algorithm and morphological operations are used for optic disc segmentation. Circular Hough transform is also used to model the disc boundary because of its computational efficiency.

we propose a superpixel classification based method and combine it with the deformable model based methods. Superpixels are local, coherent and provide a convenient primitive to compute local image features. They capture redundancy in the image and reduce the complexity of subsequent processing.[16]. In the proposed method, superpixel classification is used for an initialization of disc boundary and the deformable model is used to fine tune the disc boundary i.e. a superpixel classification based disc initialization for deformable models. The flow chart of the proposed disc segmentation method is summarized in Fig 3. The segmentation consist of a superpixel generation step to divide the image into superpixel, a feature extraction step to compute features from each superpixel, a classification step to determine each superpixel as a disc or non-disc superpixel to estimate the boundary, a deformation step using deformable models to fine tune the disc boundary which is illustrated in fig 3.

## International Journal for Research in Applied Science & Engineering Technology (IJRASET)

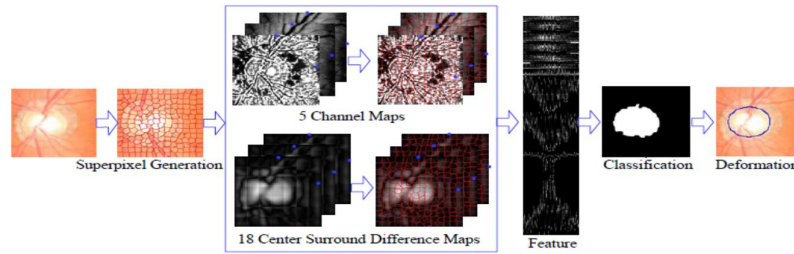


Fig. 3. Superpixel based Optic Disc Segmentation

### D. K-means clustering Technique

K-means clustering plays a vital role in the feature extraction stage to compute one of the features CDR. It is an unsupervised learning algorithm that solves the well-known clustering problem. The procedure follows a simple and easy way to classify a given data set through a certain number of clusters (k clusters) fixed a priori. The main idea is to define k centroid, one for each cluster. The next step is to take each point belonging to a given data set and associate it to the nearest centroid. At this point k new centroid are calculated as the mean of the clusters resulting from the previous step. As a result of repetitive application of these two steps, the k centroid change their location step by step until no more changes take place [17]. In other words centroid do not move any more. Finally, this algorithm aims at minimizing an objective function (squared error function). The objective function is

$$\sum_{j=1}^K \sum_{i=1}^N \|x_i^{(j)} - c_j\|^2$$

where  $\|x_i^{(j)} - c_j\|^2$  is a chosen distance measure between a data point and the cluster center is an indicator of the distance of the n data points from their respective cluster centers.

### E. Feature Extraction

1) *Gabor Filter*: The problem with cup and disc segmentation is that the visibility of boundary is usually not good especially due to blood vessels. Gabor wavelets can be tuned for specific frequencies and orientations which is useful for blood vessels. They act as low level oriented edge discriminators and also filter out the background noise of the image. Since vessels have directional pattern so 2-D Gabor wavelet is best option due to its directional selectiveness capability of detecting oriented features and fine tuning to specific frequencies. Gabor filters are directly related to Gabor wavelets, since they can be designed for a number of dilations and rotations [18]. However, in general, expansion is not applied for Gabor wavelets, since this requires computation of bi-orthogonal wavelets, which may be very time consuming. Therefore, usually, a filter bank consisting of Gabor filters with various scales and rotations is created. The filters are convolved with the signal, resulting in a so-called Gabor space. This process is closely related to processes in the primary visual cortex. Jones and Palmer showed that the real part of the complex Gabor function is a good fit to the receptive field weight functions found in simple cells in a cat's striate cortex. The Gabor space is very useful in image processing applications such as optical character recognition, iris recognition and fingerprint recognition [20].

### F. Optic Cup Segmentation

Detecting the cup boundary from 2-D fundus images without depth information is a challenging task as depth is the primary indicator for the cup boundary. In 2-D fundus images, one landmark to determine the cup region is the pallor, defined as the area of maximum color contrast inside the disc [12]. Another landmark is the vessel bends at the boundary of the cup. Compared with disc segmentation, fewer methods have been proposed for cup segmentation from 2-D fundus images. Thresholding is used to determine the cup in relying on intensity difference between cup and neuroretinal rim. A level set based approach is used in it relies on the edges between cup and neuroretinal rim [17]. This method and thresholding based methods are essentially based on pallor information [8]. This process will convert the given image into a threshold or binary image where we can easily get our Optic Cup. Binary images are produced from color images by segmentation. Segmentation is the process of assigning each pixel in the source image to two or more classes. If there are more than two classes then the usual result is several binary images. The simplest form of segmentation is probably Otsu thresholding which assigns pixels to foreground or background based on grayscale intensity. Another method is the watershed algorithm. Edge detection also often creates a binary image with some pixels assigned to edge pixels, and is also a first step in further segmentation [14].

## International Journal for Research in Applied Science & Engineering Technology (IJRASET)

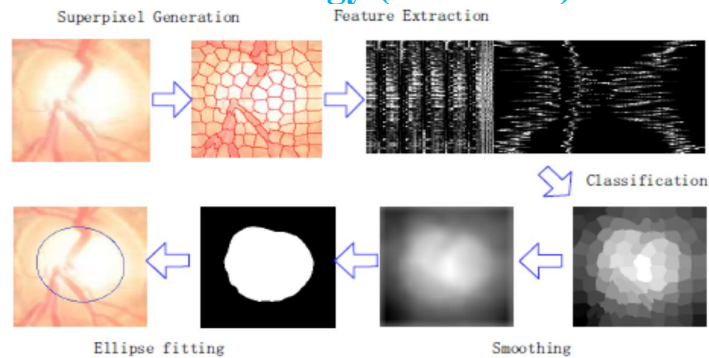


Figure 4. Superpixel based optic cup segmentation in which each disc image is divided into superpixel.

### G. Cup to Disc Ratio (CDR):

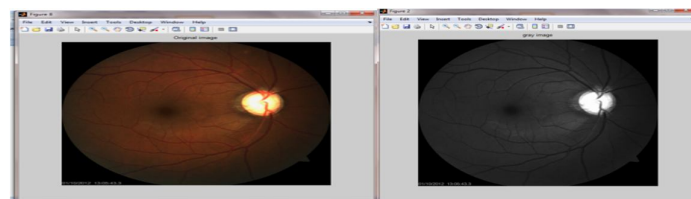
After obtaining the disc and cup, various features can be computed. We follow the clinical convention to compute the CDR. As mentioned in the introduction, CDR is an important indicator for glaucoma detection which is computed as follows.

$$\text{CDR} = \text{VCD} / \text{VDD}$$

Where VCD is vertical cup diameter and VDD is vertical disk diameter. The computed CDR is used for glaucoma screening. When CDR is greater than a threshold, it is glaucomatous, otherwise, it is healthy [15].

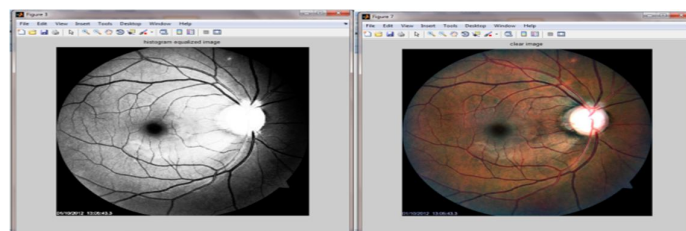
## V. EXPERIMENTAL RESULTS

For evolution, we took fundus retinal images from clinical data base . As a part of image processing technique for glaucoma diagnosis, First we have to preprocess the image Hence We have implemented first stage of Image preprocessing and histogram equalization technique for image enhancement . Then we used SLIC algorithm and k-means clustering technique for the segmentation of optic disc and results are as follows.



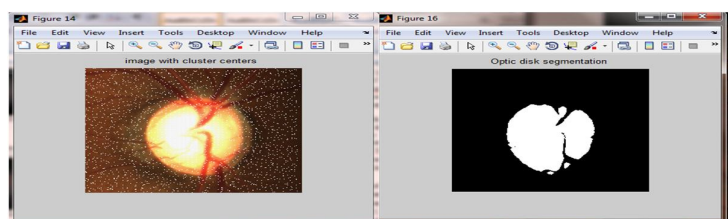
(a) Original Image

(b) Gray Image



(c) Histogram Equalized Image

(d) Clear Image



(e) Image with cluster centers

(f) Optic disc Segmentation

# International Journal for Research in Applied Science & Engineering Technology (IJRASET)

## VI. CONCLUSION

In this paper, We have proposed the system for glaucoma assessment based on superpixel classification for segmentation of optic disc and optic cup. We have discussed the methods to calculate the CDR from fundus images using segmentation of optic disc and optic cup. We concluded that for detection and diagnosis of glaucoma, firstly, optic disk need to be segmented. After image acquisition, preprocessing is done by applying thresholding, illumination and histogram equalization. The optic disk is segmented using k-means clustering and SLIC algorithm. In future work for diagnosis of glaucoma optic cup need to be segmented. After obtaining Optic Disc & Optic Cup, CDR is calculated for deciding whether condition of eye is normal or glaucomatous.

## VII. ACKNOWLEDGEMENT

The Author would like to thanks to their guide for their valuable guidance and also express sincere thanks to Dr R. Kolte and Atharva Eye Care Hospital, Pune for providing the fundus images and related data for our work and also acknowledge the medical personnel for their guidance.

## REFERENCES

- [1] R.Thomas, "Glaucoma in India: Current status and the road ahead" Indian journal of Ophthalmology, Jan 2011.
- [2] H. A. Quigley and A. T. Broman, "The number of people with glaucoma worldwide in 2010 and 2020," *Br. J. Ophthalmol.*, vol. 90(3), pp. 262–267, 2006
- [3] J. Meier, R. Bock, G. Michelson, L. G. Nyl, and J. Horneegger, "Effects of preprocessing eye fundus images on appearance based glaucoma classification," *Proc. CAIP*, pp. 165–172, 2007.
- [4] R. Bock, J. Meier, G. Michelson, L. G. Nyl, and J. Horneegger, "Classifying glaucoma with image-based features from fundus photographs," *Proc. of DAGM*, pp. 355–364, 2007.
- [5] A Osareh, Automated identification of diabetic retinal exudates and the optic disc. Ph.D. dissertation (Department of Computer Science, Faculty of Engineering, University of Bristol, Bristol, UK, 2004.
- [6] R. Bock, J. Meier, L. G. Nyl, and G. Michelson, "Glaucoma risk index: Automated glaucoma detection from color fundus images," *Med. Image Anal.*, vol. 14, pp. 471–481, 2010.
- [7] G. D. Joshi, J. Sivaswamy, and S. R. Krishnadas, "Optic disk and cup segmentation from monocular color retinal images for glaucoma assessment," *IEEE Trans. Med. Imag.*, vol. 30, pp. 1192–1205, 2011.
- [8] T. Damms and F. Dannheim, "Sensitivity and specificity of optic disc parameters in chronic glaucoma," *Invest. Ophth. Vis. Sci.*, vol. 34, pp. 2246–2250, 1993.
- [9] D. Michael and O. D. Hancox, "Optic disc size, an important consideration in the glaucoma evaluation," *Clinical Eye and Vision Care*, vol. 11, pp. 59–62, 1999.
- [10] N. Harizman, C. Oliveira, A. Chiang, C. Tello, M. Marmor, R. Ritch, and JM. Liebmann, "The isnt rule and differentiation of normal from glaucomatous eyes," vol. 124, pp. 1579–1583, 2006.
- [11] R. R. Allingham, K. F. Damji, S. Freedman, S. E. Moroi, and G. Shafranov, *Shields' Textbook of Glaucoma, 5th Edition*, Lippincott Williams & Wilkins, 2005.
- [12] J. Xu, O. Chutatape, E. Sung, C. Zheng, and P.C.T. Kuan, "Optic disk feature extraction via modified deformable model technique for glaucoma analysis," *Pattern Recognition*, vol. 40, pp. 2063–2076, 2007.
- [13] M. D. Abramoff, W. L. M. Alward, E. C. Greenlee, L. Shuba, C. Y. Kim, J. H. Fingert, and Y. H. Kwon, "Automated segmentation of the optic disc from stereo color photographs using physiologically plausible features," *Invest. Ophthalmol. Vis. Sci.*, vol. 48, pp. 1665–1673, 2007.
- [14] J. Cheng, J. Liu, Y. Xu, F. Yin, D.W. K. Wong, N. M. Tan, D. Tao, C.Y. Cheng, T. Aung, and T. Y. Wong, "Superpixel Classification Based Optic Disc and Optic Cup Segmentation for Glaucoma Screening," *IEEE Transactions on Medical Imaging*, vol.32, no. 6, pp.1019-1032, June. 2013.
- [15] Z. Hu, M. D. Abramoff, Y. H. Kwon, K. Lee, and M. K. Garvin, "Automated segmentation of neural canal opening and optic cup in 3-d spectral optical coherence tomography volumes of the optic nerve head," *Inv Ophthalmol Vis Sci.*, vol. 51, pp. 5708–5717, 2010.
- [16] K. Stapor, A. Sacutewitonski, R. Chrastek, and G. Michelson, "Segmentation of fundus eye images using methods of mathematical morphology for glaucoma diagnosis," in *Proc. ICCS*, pp. 41–48, 2004.
- [17] N. Inoue, K. Yanashima, K. Magatani, and T. Kurihara, "Development of a simple diagnostic method for the glaucoma using ocular fundus pictures," *Int. Conf. of IEEE Eng. in Med. and Bio. Soc.*, pp. 3355–3358, 2005.
- [18] D. W. K. Wong, J. Liu, J. H. Lim, X. Jia, H. Li F. Yin and, and T. Y. Wong, "Level-set based automatic cup-to-disc ratio determination using retinal fundus images in argali," pp. 2266–2269, 2008.
- [19] Y. Hatanaka, A. Noudo, C. Muramatsu, A. Sawada, T. Hara, T. Yamamoto, and H. Fujita, "Automatic measurement of vertical cup-to disc ratio on retinal fundus images," in *Proc. ICMB*, pp. 64–72, 2010.
- [20] J. Staal, M. D. Abramoff, M. Niemeijer, M. A. Viergever, and B. Ginneken, "Ridge-based vessel segmentation in color images of the retina," *IEEE Trans. Med. Imaging*, vol. 23, no. 4, pp. 501–509, 2004.





10.22214/IJRASET



45.98



IMPACT FACTOR:  
7.129



IMPACT FACTOR:  
7.429



# INTERNATIONAL JOURNAL FOR RESEARCH

IN APPLIED SCIENCE & ENGINEERING TECHNOLOGY

Call : 08813907089  (24\*7 Support on Whatsapp)