

Diabetic Retinopathy, an Eye Disease Prediction System: Survey

Sheetal Mutha¹, Mrs. G. J. Chhajed²

^{1,2}Department of Computer Engineering, VPKBIET, Baramati, India

Abstract: Diabetic retinopathy is the most common complication caused by the diabetes, which affects the eyes and results in blindness. It's due to damage of the arteries and veins located in the fundus of the eye (retina) that are composed of light sensitive tissues. Although DR can be prevalent now days, its prevention remains challenging. Ophthalmologists typically diagnose the presence and severity of DR through visual assessment of the funds by direct examination and by evaluation of colour photographs. There are a large number of diabetes patients globally, this process is expensive as well as time consuming. The automated DR system is developed to predict various related diseases that are analysed. The Digital Retinal Fundus image is analysed for the classification of various stages of Diabetic Retinopathy (DR).

Keywords: Diabetic retinopathy, Fundus Imaging, Abnormal features, Proliferative DR, Non-Proliferative DR, SVM, NN.

I. INTRODUCTION

Diabetic retinopathy (DR) can cause due to the improper blood sugar influence in the body namely diabetes. Diabetes causes a major problem in the eyes and it is the important factor to cause blindness all over the world. It is caused when diabetes causes damage to blood arteries and vessels of the retina. DR is the frequent micro vascular complications of diabetes and most causes of blindness and vision loss in the world and actually there are no early symptom of DR. DR affects the retinal vascular structure and leads as progressive retinal damage.

II. DIABETIC RETINOPATHY HAS FOLLOWING MAJOR SYMPTOMS

- A. Double vision.
- B. Development of a shadow in your field of view.
- C. Eye floaters and spots.
- D. Blurry and additionally misshaped vision.
- E. Fluctuating vision.
- F. Eye torments.
- G. Near vision issues disconnected to presbyopia.

Diabetic retinopathy's occurrence will bring about the increase of visual ability and can eventually lead to visual damage. When high glucose harms arteries in the retina, eyes can spill drain or fluid. This can cause the retina to swell and shape stores in the early phase of diabetic retinopathy.

III. DIABETIC RETINOPATHY PREDICTION

Diabetic retinopathy may grow through mainly four stages:

DR prediction is the process of identifying whether the patient is affected by DR, given the set of the patient's input fundus images. This process makes use of a huge corpus of fundus images with labels varied from 0 to 4:

0 No DR	1 Mild	2 Moderate	3 Severe	4 Proliferative DR
---------	--------	------------	----------	--------------------

A. Mild Non-Proliferative Retinopathy

This is the earliest stage of the disease. In this small area of the balloon like swelling in the retina's tiny blood vessels, called smaller scale aneurysms, emerge at this first phase of the illness. These micro aneurysms may release fluid/blood into the retina.

B. Moderate Non-Proliferative Retinopathy

At this stage, as the illness turns out to be more terrible; Blood vessels that nourish the retina may swell and distort. As the disease progresses, they may also lose their capability to transport blood. Both circumstances cause characteristic changes to the presence of the retina and may add to DME.

C. Severe Non-Proliferative Retinopathy

At this stage, Blood supply to areas of the retina is blocked by blood vessels. These influenced areas secrete growth factors that signal the retina to grow new blood vessels.

D. Proliferative diabetic retinopathy (PDR)

During this advanced stage, the new blood vessels are likely to leak and bleed. The retina trigger the expansion of fresh blood vessels, which grows along the inside surface of the retina and into vitreous gel, the liquid/blood that fills the eye. The fresh blood vessels are delicate, that makes them more inclined to spill and drain. Also scar tissue can contract and further be the reason of retinal separation. The pulling without end of the retina from hidden tissues, similar to backdrop peeling is far from a divider. This can cause permanent vision loss due to retinal detachment.

In further stages, spill over from the veins into the eyes, jam like vitreous can bring genuine vision issues and can result in visual damage. In this manner, analysis and identification of diabetic retinopathy (DR) at initial level are critical to maintain a strategic distance from vision problem. Finding of diabetic retinopathy is typically directed by the ophthalmologist.

Ophthalmologist utilizes retinal pictures of patients for analysis and diagnosis prediction. An Ophthalmologist can get retinal pictures from patients to analyse it by using a fundus camera. From these pictures, symptoms will be recognized physically by an ophthalmologist. In this manner, additional time is required to analyse a number of patients.

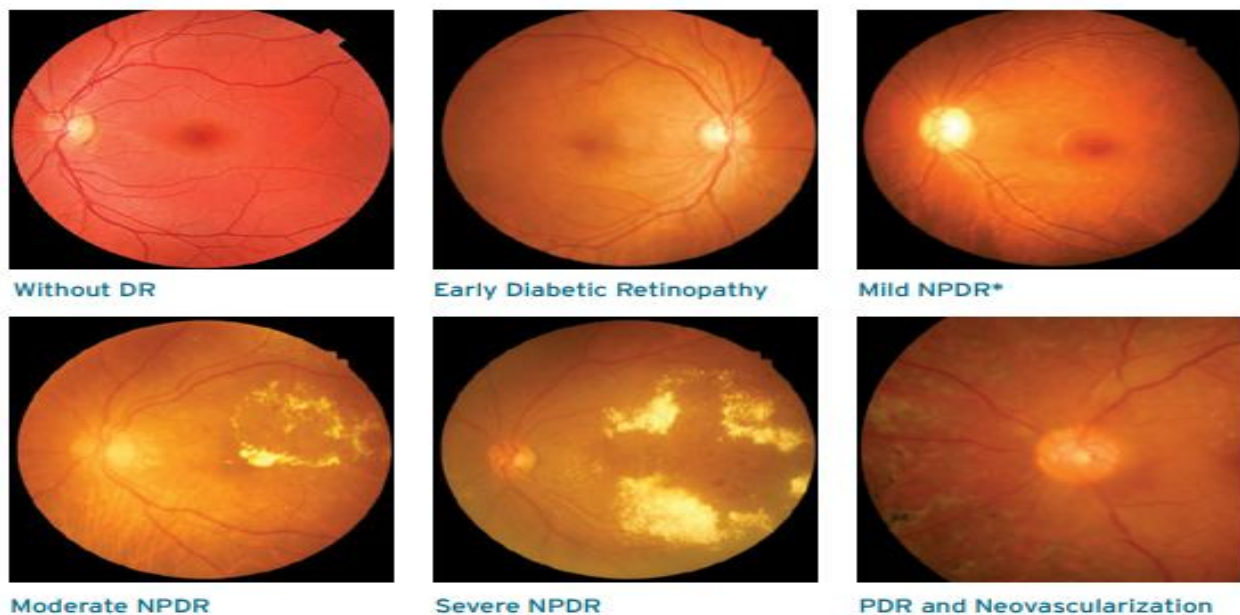


Figure: - Diabetic retinopathy main stages.

Diabetic Retinopathy DR Tool will enable doctors to view variations from multiple fundus camera images with the help of image preprocessing techniques. The tool makes use of the emerging machine learning technology to process fundus images quickly and accurately as manual screening. Most important, it reduces the time period for executing the complete process.

IV. DIABETIC RETINOPATHY DETECTION TECHNIQUES

A. Retinal Image Analysis Using Machine Learning Algorithm.

- 1) “Santhakumar R”, et.al [1] introduces the design and implementation of screening and diagnostic tool for Diabetic Retinopathy was successfully completed. The screening tool has two segments; Image level and patch level prediction. The feature plot using PCA provides visualization of parameter value for the different classes. The different textural features are Scale Invariant Feature Transform (SIFT), Histogram of Gradient (HOG) and Local Binary Pattern (LBP). The patch level prediction using multi class Support Vector Machine is also efficiently implemented for prediction of Hard Exudates and Hemorrhage.
- a) *Advantage:* The different textural features like Scale Invariant Feature Transform (SIFT), Histogram of Gradient (HOG) and Local Binary Pattern (LBP) are implemented. The PCA is used to visualize the features and Windowing method is used for detecting Hard Exudates.

2) “Sohini Roychowdhury”, et al [10] discuss about the Classifiers such as Gaussian Mixture Model (GMM), k-nearest neighbor (KNN), support vector machine (SVM), and Ada Boost are analyzed for classifying retinopathy lesions from non - lesions. Gaussian Mixture Model (GMM) and KNN classifiers are found to be the best classifiers for bright and red lesion classification, respectively. A novel two-step hierarchical classification approach is proposed where the non-lesions or false positives are rejected in the first step. In the second step, the bright lesions are classified as hard exudates and cotton wool spots, and the red lesions are classified as hemorrhages and micro-aneurysms. The detection of neovascularization and vascular beading caused by proliferative DR, and druse caused by macular degeneration.

a) *Advantage: The reduction in the number of features used for lesion classification by feature ranking using Adaboost where 30 top features are selected out of 78.*

B. Neural Network for Detection of Diabetic Retinopathy.

1) “B. Sumathy” et al [2] describes the abnormal features in the fundus images with the performance approaching that of trained clinical observer. A novel combination of image preprocessing technique for retinal anatomical structures and classification with machine learning is a computer based which extracts abnormal features such as micro aneurysms, exudates, hemorrhages and new vessels etc. for grading the severity of Diabetic Retinopathy. It found to reduce the manual effort required for the detection and also the accuracy gets increased. Computationally powerful to detect and diagnose the diseases from the fundus images.

a) *Advantage: The first phase is preprocessing steps are done followed by next phase of removal of normal features with extraction of abnormal features and its statistical values. The third phase is classification stages which includes mild, moderate to severe, severe PDR and neovascularization etc. using neural network.*

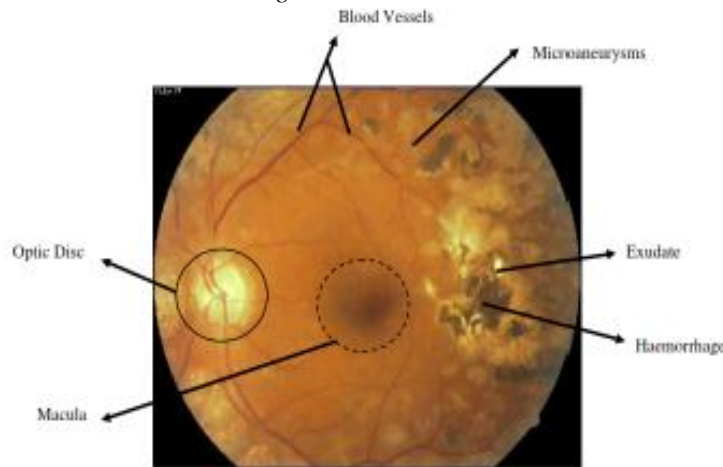


Figure: - Normal and abnormal features of DR image. [2]

2) “Xiyang Liu”, et al [4] focuses on computer vision-based framework for the automatic localization and diagnosis of slit lamp images by identifying the lens region of interest (ROI) and employing a deep learning convolutional neural network (CNN). The performance and effectiveness of the deep features extracted in the CNN, the ROI of the lens was identified with the adoption of twice-applied Candy detection and Hough transform and then it entered into the CNN to investigate the slit-lamp image.

a) *Advantage: Deployment of multi kernel learning and ensemble learning for slit-lamp images.*

C. Features Extracted From Fundus Images Using Svm (Support Vector Machine)

1) “R. Adalarasan”, et al [3] describes the extraction of normal and isolated characteristics or marks in color retinal images. The adaptive filters are tuned to match the lump (part) of vessel to be extracted in green channel images. The soft exudates color and intensity were close to fundus color. The lesions breed of interest was micro aneurysms, haemorrhages, hard exudates, soft exudates and neovascularization. The precision of exudates perception appears to be good since exudate pixels were accurately classified as exudates and further pixels as non-exudates by Biogeography Based Optimization Algorithm.

a) *Advantage: Color based approach for identifying hemorrhages, hard exudates, and soft exudates.*

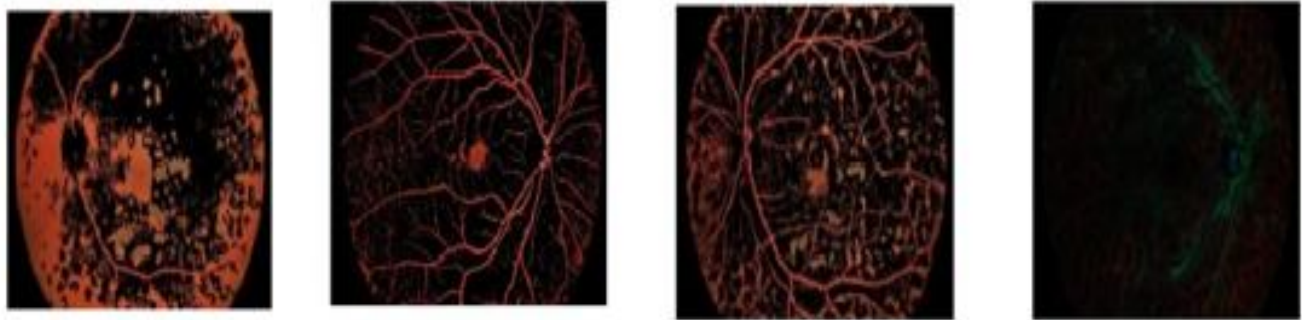


Figure: - Color based approach. [3]

2) “Shishir Maheshwari”, et al [6] introduces an automated diagnosis of glaucoma system. The available scanning methods are Heidelberg Retinal Tomography (HRT), Scanning Laser Polarimetry (SLP) and Optical Coherence Tomography (OCT). These methods are expensive and require experienced clinicians to use them. Present a new methodology for an automated diagnosis of glaucoma using digital fundus images based on Empirical Wavelet Transform (EWT). The EWT is used to decompose the image and correntropy features are obtained from decomposed EWT components. These extracted features are ranked based on t value feature selection algorithm. Extracted features are used for the classification of normal and glaucoma images using Least Squares Support Vector Machine (LS-SVM) classifier.

a) *Advantages*

- i) *The EWT technique is used to decompose the image and correntropy features are obtained from decomposed EWT components.*
- ii) *EWT is less costly as compare to other techniques like HRT, SLP and so on.*

3) “Ramon Pires”, et al [9] focuses bypass lesion detection, and directly train a classifier for DR referral. Novelties are the use of state-of-the-art mid-level features for the retinal images: BossaNova and Fisher Vector. These features extend the classical Bags of Visual Words and greatly improve the accuracy of complex classification tasks. The highlight that directs assessment is new for referable diabetic retinopathy, and has not been developed before.

a) *Advantage: Much simpler to implement, test, and deploy.*

D. *Computer Aided Diagnosis System For Diabetic Retinopathy*

1) “Romany F. Mansour” [8] survey revealed that evolutionary computing methods can play vital role for optimizing DR-CAD functional components, such as pro-processing by enhancing filters coefficient, segmentation by enriching clustering, feature extraction, feature selection, and dimensional reduction, as well as classification. Robust and efficient computer aided diagnosis (CAD) system to enable earlier DR detection and optimal diagnosis decision. The prime objective of these CAD solutions is to identify DR features earlier and identify severity of the DR. To enhance these approaches a number of evolutionary computing algorithms such as GA, PSO, ACO, BFO, DE etc have been applied which primarily functions towards enhancing functional extraction parameters and feature selection. PSO being a stochastic heuristics optimization method takes extracted features from the RR correlation analysis and employs swarm intelligence approach to identify optimal solution by estimating global minima. PSO avoid crossover and mutation processes and thus avoid significant computational overhead.

a) *Advantages*

- i) *Number of technologies developed for diabetic retinopathy (DR) have been studied and respective strength as well as weaknesses has been assessed.*
- ii) *PSO algorithm that significantly reduced time complexity.*

2) “Mike Voets”, et al [7] Replication studies are essential for validation of new methods, and to Development and validation of a deep learning algorithm for detection of diabetic retinopathy in retinal fundus photographs. The deep learning can be used to automatically detect diabetic retinopathy. They re-implemented the method since the source code is not available, and used publicly available data sets. The Kaggle Eye PACS test dataset is used for this work.

V. ANALYSIS

TABLE I: COMPARATIVE ANALYSIS

Title and Author	Advantages	Limitation	Technology Used	Future Scope
<p>“Machine Learning Algorithm for Retinal Image Analysis”.</p> <p>Santhakumar R, Megha Tandur, E R Rajkumar, Geetha K S, Girish Haritz, Kumar Thirunellai Rajamani.</p>	<p>The different textural features like Scale Invariant Feature Transform (SIFT), Histogram of Gradient (HOG) and Local Binary Pattern (LBP) are implemented.</p> <p>The PCA is used to visualize the features and Windowing method is used for detecting Hard Exudates.</p>	<p>Complex function results in dual Quadratic problem.</p>	<p>i. PCA for visualizing the features.</p> <p>ii. Support Vector Machine (SVM)</p>	<p>Different images and large datasets.</p>
<p>“Automated DR and prediction of various related diseases of retinal fundus images”.</p> <p>B. Sumathy, S. Poornachandra.</p>	<p>The initial phase is preprocessing steps are done followed by next phase of removal of normal features with extraction of abnormal features and its statistical values. The third phase is classification stages which includes mild, moderate to severe, severe PDR and neovascularization etc. using neural network.</p>	<p>The non-detection of the soft exudates that occurred in the optic disk.</p>	<p>i. Artificial Neural Networks (ANN).</p> <p>ii. Bayesian Regularized Artificial Neural Networks (BRANNs).</p>	<p>Future works also include;</p> <p>-The application of the proposed method to other imaging modalities and larger data sets.</p> <p>-Stronger algorithm can be developed for neovascularization especially after photocoagulation therapy.</p>
<p>“Localization and diagnosis framework for pediatric cataracts based on slit-lamp images using deep features of a Convolutional Neural Network”.</p> <p>Xiyang Liu, Jiewei Jiang, Kai Zhang, Erping Long, Jiangtao Cui, Mingmin Zhu, Yingying An, Jia Zhang, Zhenzhen Liu, Zhuoling Lin, Xiaoyan Li, Jingjing Chen, Qianzhong Cao, Jing Li, Xiaohang Wu, Dongni Wang, Haotian Lin.</p>	<p>i. Advantage of the deep learning model to enhance the reliability of the diagnosis system with large amounts of accumulated datasets.</p> <p>ii. Deployment of multi kernel learning and ensemble learning for slit-lamp images.</p>	<p>-</p>	<p>Convolutional Neural Network (CNN).</p>	<p>Plan to apply the proposed method to other biomedical images and assess its Performance and robustness using multiple datasets.</p>
<p>“Modular Neural Network for Detection of Diabetic</p>	<p>Modular Feed forward neural network for detection of</p>	<p>The average of the square of the</p>	<p>i. Modular feed forward</p>	<p>Using different multiple datasets for more</p>

Retinopathy in Retinal Images”. Manish Sharma, Praveen Sharma, Ashwini Saini and Kirti Sharma.	diabetic retinopathy by classifying retinal images as normal or abnormal.	difference of the required response and the actual system output	Neural Network (MNN). ii.Database:- DIARETDBO	accuracy.
“DREAM: Diabetic Retinopathy Analysis using Machine Learning”. Sohini Roychowdhury, Dara D. Koozekanani, Keshab K. Parhi	The reduction in the number of features used for lesion classification by feature ranking using Adaboost where 30 top features are selected out of 78.	It is observed that for the red lesion classification problem, where the numbers of negative samples are 4 times more than the number of positive samples.	Classifiers such as; Gaussian Mixture Model (GMM), k-nearest neighbor (kNN), support vector machine (SVM), and AdaBoost.	Future works is to diagnosis of other diseases like diabetes retinopathy, fatty liver disease, thyroid cancer and ovarian cancer etc.
“Beyond Lesion-based Diabetic Retinopathy: a Direct Approach for Referral” Ramon Pires, Sandra Avila, Herbert F. Jelinek, Jacques Wainer, Eduardo Valle, and Anderson Rocha.	Much simpler to implement, test, and deploy.	The limitations of BoVW for retinal images(specifically the semi-soft coding proposed for eye-fundus images), and explore sophisticated approaches for mid-level description, such as Fisher Vector and BossaNova.	i. Bag of Visual Words. ii. BossaNova. iii. Fisher Vector	Future work consists of, studying alternative techniques using very recent approaches such as convolutional neural networks.
“Evolutionary Computing Enriched Computer Aided Diagnosis System For Diabetic Retinopathy: A Survey” Romany F. Mansour	1. Number of technologies developed for diabetic retinopathy (DR) has been studied and respective strength as well as weaknesses has been assessed. 2. PSO algorithm that significantly reduced time complexity.	The limitation like it unable to perform identification of the small clusters contributing exudates segmentation.	i. Computer Aided Diagnosis (CAD). ii. Histogram of Oriented Gradient (HOG) transforms.	Realizing the robustness of deep neural network (DNN) algorithm. The EC schemes can be significant for feature selection.

VI. ADVANTAGES

- A. Early detection of DR can help allow people to retain their sight and enable specialists to focus on treatments.
- B. Relatively lower cost than manual methods.
- C. Highly scalable process with quick response time.

VII. APPLICATIONS

A. To detect the DR (Diabetic Retinopathy) stages.

VIII. CONCLUSION

This paper surveys and analyzes the automatic DR detection and diagnosis applied to human retinal fundus images as input and processes it to identify abnormalities based on aforementioned DR features and assess its severity. Here number of technologies developed for diabetic retinopathy (DR) has been studied. This survey revealed that a significant amount of efforts have been made on enhancing the image quality by optimizing image contrast and background illumination over green channel fundus images.

Thus, observing overall literatures and respective contributions, it can be visualized that evolutionary computing schemes can be of significance to strengthen all the comprising functional components of the diabetic retinopathy, including pro-processing by enhancing filters coefficient, segmentation by enriching clustering or ROI feature selection, feature extraction, feature selection, and dimensional reduction, and classification enhancement by facilitating optimal learning weight parameters regularization parameters (for SVM) etc.

REFERENCES

- [1] Santhakumar R, Megha Tandur, E R Rajkumar, Geetha K S, Girish Haritz, Kumar Thirunellai Rajamani, "Machine Learning Algorithm for Retinal Image Analysis", IEEE, 2016.
- [2] B. Sumathy, S. Poornachandra "Automated DR and prediction of various related diseases of retinal fundus images." Special Section: Artificial Intelligent Techniques for Bio Medical Signal Processing Biomed Res 2018 Special Issue.
- [3] R. Adalarasana and R. Malathib, "Automatic Detection of Blood Vessels in Digital Retinal Images using Soft Computing Technique", International Conference on Processing of Materials, Minerals and Energy 2017 Elsevier.
- [4] Xiyang Liu, Jiewei Jiang, Kai Zhang, Erping Long, Jiangtao Cui, Mingmin Zhu, Yingying An, Jia Zhang, Zhenzhen Liu, Zhuoling Lin, Xiaoyan Li, Jingjing Chen, Qianzhong Cao, Jing Li, Xiaohang Wu, Dongni Wang, Haotian Lin, "Localization and diagnosis framework for pediatric cataracts based on slit-lamp images using deep features of a convolutional neural network," PLOS ONE | DOI:10.1371/journal.pone.0168606 March 17, 2017.
- [5] Manish Sharma, Praveen Sharma, Ashwini Saini and Kirti Sharma, "Modular Neural Network for Detection of Diabetic Retinopathy in Retinal Images", International Conference on Smart System, Innovations and Computing, © Springer Nature Singapore Pte Ltd. 2018.
- [6] Shishir Maheshwari, Ram Bilas Pachori, and U. Rajendra Acharya, "Automated Diagnosis of Glaucoma Using Empirical Wavelet Transform and Correntropy Features Extracted from Fundus Images", 2015 IEEE.
- [7] Mike Voets, Kajsa Mllersen, Lars Ailo Bongo, "Replication study: Development and validation of a deep learning algorithm for detection of diabetic retinopathy in retinal fundus photographs", arXiv:1803.04337v3 [cs.CV] 30 Aug 2018
- [8] Romany F. Mansour, "Evolutionary Computing Enriched Computer Aided Diagnosis System For Diabetic Retinopathy: A Survey" 2016 IEEE.
- [9] Ramon Pires, Sandra Avila, Herbert F. Jelinek, Jacques Wainer, Eduardo Valle, and Anderson Rocha, "Beyond Lesion-based Diabetic Retinopathy: IEEE Journal of Biomedical and Health Informatics 2015 IEEE.
- [10] Sohini Roychowdhury, Dara D. Koozekanani, and Keshab K. Parhi "DREAM: Diabetic Retinopathy Analysis using Machine Learning" IEEE Journal of Biomedical and Health Informatics 2013 IEEE
- [11] Hsin-Yi Tsao, Pei-Ying Chan, and Emily Chia-Yu Su "Predicting diabetic retinopathy and identifying interpretable biomedical features using machine learning algorithms". BMC Bioinformatics. 2018.
- [12] Omolola Ogunyemi, and Dulcie Kermah, MPH "Machine Learning Approaches for Detecting Diabetic Retinopathy from Clinical and Public Health Records" AMIA Annu Symp Proc. 2015
- [13] Rishab Gargeya, Theodore Leng, "Automated Identification of Diabetic Retinopathy Using Deep Learning" 2017 by the American Academy of Ophthalmology Published by Elsevier Inc.