

Detection of Retinal Blood Vessels for Disease Prediction using Machine Learning

Shruti Wagh¹, Saswat Panda², Samriddhi Agrawal³, Akash Agarwal⁴, Asst. Prof. Priyanka Gulhane⁵, Asst. Prof. Priti Wakodikar⁶

^{1, 2, 3, 4}Dept. of Information Technology, MIT College OF Engineering

^{5, 6}Dept. of Information Technology, MAEER's MIT COE, Pune, Maharashtra, India

Abstract: Retinal diseases like glaucoma, diabetic retinopathy, age-related macular degeneration, stargardt's disease, retinopathy of prematurity that can lead to blindness manifest as artifacts in the retinal image. The term Diabetic retinopathy is the serious issue that is caused by the diabetes, which affects the eyes and results in blindness. It's due to damage of the arteries and veins that are present in the fundus of the eye (retina) that is the origin of light sensitive tissues. Although DR can be prevalent now days, its prevention remains challenging. Visual analysis of the funds and consideration of color photographs Ophthalmologists directly examine the existence and severity of DR. This process is expensive as well as time consuming as there are huge number of diabetes patients worldwide. The automatic DR system is expanded to predict various related diseases that are analyzed.

Keywords: Diabetic retinopathy, Fundus Imaging, Abnormal features.

I. INTRODUCTION

MEDICAL image segmentation algorithms label each voxel in a digital diagnostic image to indicate the tissue type and provide information about the underlying anatomical structures. Inconsistent image quality, intensity inhomogeneity, blurred edges, and poorly defined boundaries are some of the inherent challenges encountered in the medical image segmentation task. Nevertheless, recent advances in the medical imaging modalities and computer vision contributed significantly to the growth of image guided diagnosis. In that vein, since the digital image data pertaining to the retina lends itself to the image processing and pattern recognition procedures, the early detection of retinal diseases becomes a reality.

Diabetic retinopathy (DR) can cause due to the improper blood sugar influence in the body namely diabetes. Diabetes causes a major problem in the eyes and it is the important factor to cause blindness all over the world. It is caused when diabetes causes damage to blood arteries and vessels of the retina. DR is the frequent micro vascular complications of diabetes and most causes of blindness and vision loss in the world and actually there are no early symptom of DR. DR affects the retinal vascular structure and leads as progressive retinal damage.

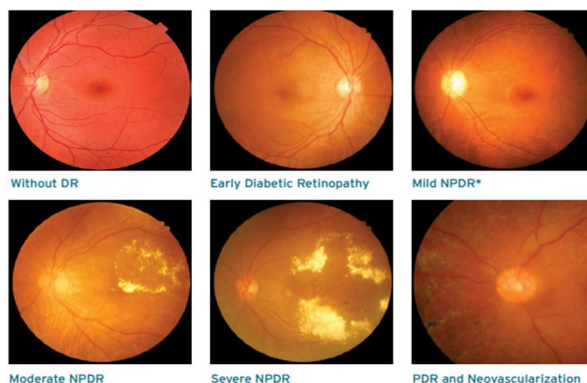


Figure: - Diabetic retinopathy main stages.

Diabetic retinopathy may grow through mainly four stages:

DR prediction is the process of identifying whether the patient is affected by DR, given the set of the patient's input fundus images.

This process makes use of a huge corpus of fundus images with labels varied from 0 to 4:

0 No DR	1 Mild	2 Moderate	3 Severe	4 Proliferative DR
---------	--------	------------	----------	--------------------

Age-related Macular Degeneration (AMD) is a gradual, progressive, painless deterioration of the macula. It is a leading cause of blindness and affects people, who are aged 65 and older. The appearance of spots beneath the retina marks the early stage of AMD. A fundus photograph of an eye with nonvascular AMD is shown in following figure. These spots are small, round lesions called drusen that cause serious loss of vision. The risk is higher when the drusen are large and numerous. Two forms of AMD exist: ‘dry’ and ‘wet’.

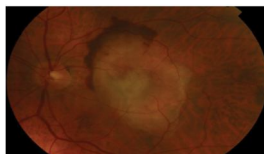


Figure: - Fundus photograph showing an eye with nonvascular Age-related Macular Degeneration

II. RETINOPATHY CONDITIONS

Glaucoma, a chronic disease that affects the optic nerves is the second major cause of blindness in the world leading to losses in the visual field and eventual blindness. If glaucoma is left untreated, it may lead to permanent damage of the optic nerves and cause blindness. This progressive and irreversible damage to the optic nerves is often accompanied by only subtle signs or even no symptoms, and therefore it is nicknamed as the ‘sneak thief of sight’. An early detection of glaucoma is important, which can minimize the damage and the vision loss, and ensure a prompt and adequate treatment.

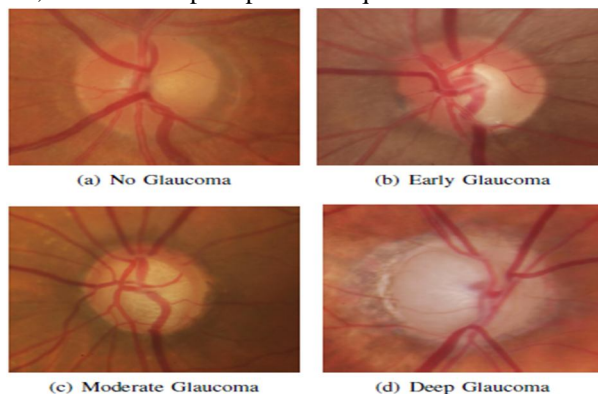


Figure: - Retinal Fundus Images - Normal and Pathological eyes

III. LITERATURE SURVEY

A. Retinal Image Analysis Using Machine Learning Algorithm.

- 1) “Santhakumar R”, et.al [1] introduces the design and implementation of screening and diagnostic tool for Diabetic Retinopathy was successfully completed. The screening tool has two segments; Image level and patch level prediction. The feature plot using PCA provides visualization of parameter value for the different classes. The different textural features are Scale Invariant Feature Transform (SIFT), Histogram of Gradient (HOG) and Local Binary Pattern (LBP). The patch level prediction using multi class Support Vector Machine is also efficiently implemented for prediction of Hard Exudates and Hemorrhage.
 - a) *Advantage:* The different textural features like Scale Invariant Feature Transform (SIFT), Histogram of Gradient (HOG) and Local Binary Pattern (LBP) are implemented. The PCA is used to visualize the features and Windowing method is used for detecting Hard Exudates.
- 2) “Sohini Roychowdhury”, et al [10] discuss about the Classifiers such as Gaussian Mixture Model (GMM), k-nearest neighbor (KNN), support vector machine (SVM), and Ada Boost are analyzed for classifying retinopathy lesions from non - lesions. Gaussian Mixture Model (GMM) and KNN classifiers are found to be the best classifiers for bright and red lesion classification, respectively. A novel two-step hierarchical classification approach is proposed where the non-lesions or false positives are rejected in the first step. In the second step, the bright lesions are classified as hard exudates and cotton wool spots, and the red lesions are classified as hemorrhages and micro-aneurysms. The detection of neovascularization and vascular beading caused by proliferative DR, and druse caused by macular degeneration.
 - a) *Advantage:* The reduction in the number of features used for lesion classification by feature ranking using Adaboost where 30 top features are selected out of 78.

B. Neural Network for Detection of Diabetic Retinopathy.

- 1) "B. Sumathy" et al [2] describes the abnormal features in the fundus images with the performance approaching that of trained clinical observer. A novel combination of image preprocessing technique for retinal anatomical structures and classification with machine learning is a computer based which extracts abnormal features such as micro aneurysms, exudates, hemorrhages and new vessels etc. for grading the severity of Diabetic Retinopathy. It found to reduce the manual effort required for the detection and also the accuracy gets increased. Computationally powerful to detect and diagnose the diseases from the fundus images.
 - a) *Advantage: The first phase is preprocessing steps are done followed by next phase of removal of normal features with extraction of abnormal features and its statistical values. The third phase is classification stages which includes mild, moderate to severe, severe PDR and neovascularization etc. using neural network.*

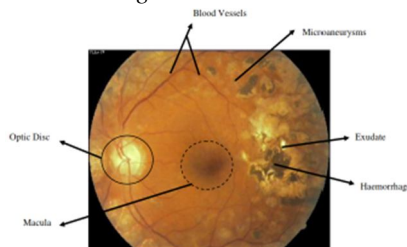


Figure: - Normal and abnormal features of DR image. [2]

C. Features Extracted from Fundus Images Using SVM (Support Vector Machine)

- 1) "R. Adalarasan", et al [3] describes the extraction of normal and isolated characteristics or marks in color retinal images. The adaptive filters are tuned to match the lump (part) of vessel to be extracted in green channel images. The soft exudates color and intensity were close to fundus color. The lesions breed of interest was micro aneurysms, haemorrhages, hard exudates, soft exudates and neovascularization. The precision of exudates perception appears to be good since exudate pixels were accurately classified as exudates and further pixels as non-exudates by Biogeography Based Optimization Algorithm.
 - a) *Advantage: Color based approach for identifying hemorrhages, hard exudates, and soft exudates.*

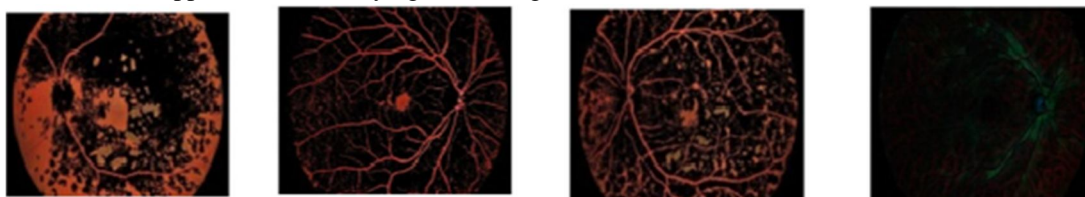


Figure: - Color based approach. [3]

- 2) "Shishir Maheshwari", et al [6] introduces an automated diagnosis of glaucoma system. The available scanning methods are Heidelberg Retinal Tomography (HRT), Scanning Laser Polarimetry (SLP) and Optical Coherence Tomography (OCT). These methods are expensive and require experienced clinicians to use them. Present a new methodology for an automated diagnosis of glaucoma using digital fundus images based on Empirical Wavelet Transform (EWT). The EWT is used to decompose the image and correntropy features are obtained from decomposed EWT components. These extracted features are ranked based on t value feature selection algorithm. Extracted features are used for the classification of normal and glaucoma images using Least Squares Support Vector Machine (LS-SVM) classifier.
 - a) *Advantages*
 - i) The EWT technique is used to decompose the image and correntropy features are obtained from decomposed EWT components.
 - ii) EWT is less costly as compare to other techniques like HRT, SLP and so on.
- 3) "Ramon Pires", et al [9] focuses bypass lesion detection, and directly train a classifier for DR referral. Novelties are the use of state-of-the-art mid-level features for the retinal images: BossaNova and Fisher Vector. These features extend the classical Bags of Visual Words and greatly improve the accuracy of complex classification tasks. The highlight that directs assessment is new for referable diabetic retinopathy, and has not been developed before.
 - a) *Advantage: Much simpler to implement, test, and deploy.*

D. Computer Aided Diagnosis System For Diabetic Retinopathy

1) “Romany F. Mansour” [8] survey revealed that evolutionary computing methods can play vital role for optimizing DR-CAD functional components, such as pro-processing by enhancing filters coefficient, segmentation by enriching clustering, feature extraction, feature selection, and dimensional reduction, as well as classification. Robust and efficient computer aided diagnosis (CAD) system to enable earlier DR detection and optimal diagnosis decision. The prime objective of these CAD solutions is to identify DR features earlier and identify severity of the DR. To enhance these approaches a number of evolutionary computing algorithms such as GA, PSO, ACO, BFO, DE etc have been applied which primarily functions towards enhancing functional extraction parameters and feature selection. PSO being a stochastic heuristics optimization method takes extracted features from the RR correlation analysis and employs swarm intelligence approach to identify optimal solution by estimating global minima. PSO avoid crossover and mutation processes and thus avoid significant computational overhead.

a) Advantages

- i) Number of technologies developed for diabetic retinopathy (DR) has been studied and respective strength as well as weaknesses has been assessed.
- ii) PSO algorithm that significantly reduced time complexity.

IV. PROPOSED SYSTEM

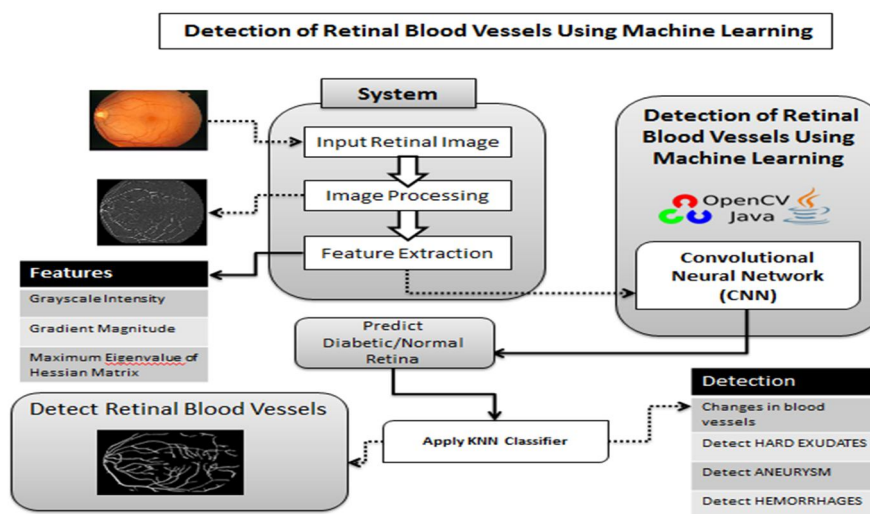


Figure: - System Architecture.

- 1) *Load Retinal Image Dataset*: Get the retinal image dataset for training and testing for detecting blood vessels.
- 2) *Pre-processing*: Preprocessing is done on the raw images. In this stage, image is resized as well as it converts from RGB to gray scale.

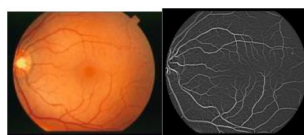


Figure: - (a) Original Retinal Scan (b) Retinal Scan after Image Processing

- 3) *Feature Extraction*: Feature extracted from the preprocessed retinal image. They extract the following features,
 - a) *Gray scale Intensity*: Gray scale intensity values represent the intensity of each pixel.
 - b) *Gradient Magnitude*: It used to represent the gradient magnitude value for every pixel in an image. For calculation they use following formula,

$$\|\nabla F\| = \sqrt{F_x^2 + F_y^2}$$

- c) *Maximum Eigenvalue of Hessian Matrix*: Using the below formula they calculate the Maximum Eigenvalue of Hessian Matrix for each pixel using second derivatives of the matrix.

$$\lambda_+ = \frac{1}{2} \left(F_{xx} + F_{yy} + \sqrt{(F_{xx} - F_{yy})^2 + (2F_{xy})^2} \right)$$

- 4) *Apply SVM Analysis:* SVM apply for detecting the blood vessels in retinal image. The model was trained with the three dimensional feature vectors and data set. SVMs fit this application well because they are designed to maximize the margin between the positive and negative examples.
- 5) *Apply Modified K-NN Analysis:* The k-NN algorithm was modified to be unsupervised by randomly initializing a subset of pixels and their very near neighbors. These clustered points were then used to begin the regular k-NN algorithm which was repeated until convergence. The below formula is used to calculates the distance between two pixels to be the square root of the sum of squares of the difference between each feature of those pixels.

$$d(x_i, x_j) = \|x_i - x_j\|_2$$

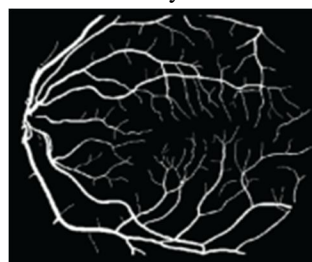
Where,

x = the feature vectors associated with specific pixels.

- 6) *Final Result:* In this stage, the system can show the final result of both SVM and k-NN analysis.

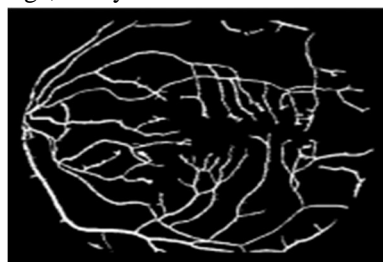

Figure: - (a) SVM Result



(b) k-NN Result

V. ALGORITHMS USED

A. Convolutional Neural Network (CNN)

Traditional feature learning methods rely on semantic labels of images as supervision. They usually assume that the tags are evenly exclusive and thus do not pointing out towards the complication of labels. The learned features endow explicit semantic relations with words.

We also develop a novel cross-modal feature that can both represent visual and textual contents. CNN itself is a technique of classifying images as a part of deep learning. In which we apply single neural network to the full image.

- 1) Accepts a volume of size $W1 \times H1 \times D1$
- 2) Requires four hyper parameters
 - i) Number of filters K
 - ii) Their spatial extent F
 - iii) The stride S
 - iv) The amount of zero padding P
- 3) Produces a volume of size $W2 \times H2 \times D2$ where
 - i) $W2 = (W1 - F + 2P) / S + 1$
 - ii) $H2 = (H1 - F + 2P) / S + 1$ (i.e. width and height are computed equally by symmetry)
 - iii) $D2 = K$

With parameter sharing, it introduces $F * F * D1$ weights per filter, for a total of $(F * F * D1) * K$ weights and K biases.

- 4) In the output volume, the d-th depth slice (of size $W2 \times H2$) is the result of performing a valid convolution of the d-th filter over the input volume with a stride of S, and then offset by d-th bias.
- 5) A common setting of the hyper parameters is $F=3, S=1, P=1$ However, there are common conventions and rules of thumb that motivate these hyper parameters.

VI. RESULT AND DISCUSSION

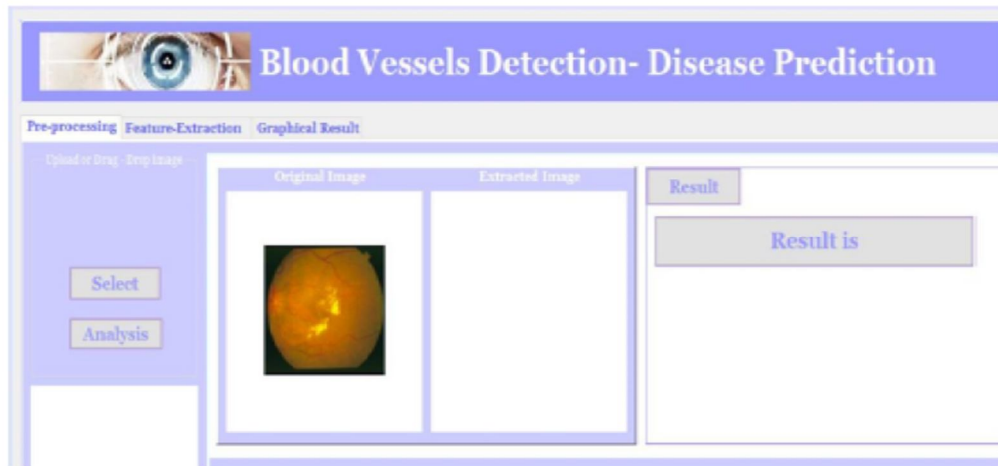


Figure: - System GUI

Algorithm	Accuracy
SVM	88.35
KNN	81.27
Random Forest	72.38

Table: - Algorithm Comparison.

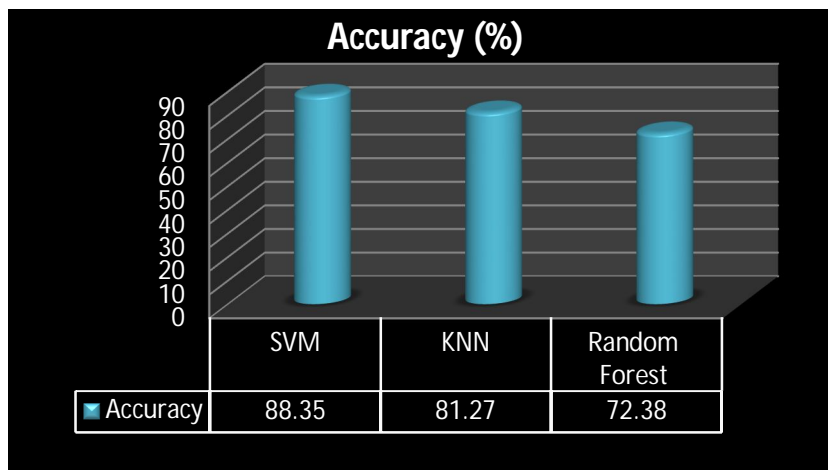


Figure: - Algorithm Comparison with respect to accuracy.

VII. ADVANTAGES

- A. The whole system can be implemented in very low cost and provides better accuracy.

VIII. CONCLUSION

Eye disease detection is a popular exploration area in computer vision and image processing area. The proposed system focuses on to detect the retinal blood vessels from the original retinal images. Here we proposed a system that can able to detect the diabetic image or normal images from retinal input image. Here we are using SVM classification algorithm to predict the normal or abnormal image. Thus, observing overall literatures and respective contributions, it can be visualized that evolutionary computing schemes can be of significance to strengthen all the comprising functional components of the diabetic retinopathy, including pre-processing by enhancing filters coefficient, segmentation by enriching clustering or ROI feature selection, feature extraction, feature selection, and dimensional reduction, and classification enhancement by facilitating optimal learning weight parameters regularization parameters (for SVM) etc.

REFERENCES

- [1] Santhakumar R, Megha Tandur, E R Rajkumar, Geetha K S, Girish Haritz, Kumar Thirunellai Rajamani, "Machine Learning Algorithm for Retinal Image Analysis", IEEE, 2016.
- [2] B. Sumathy, S. Poornachandra "Automated DR and prediction of various related diseases of retinal fundus images." Special Section: Artificial Intelligent Techniques for Bio Medical Signal Processing Biomed Res 2018 Special Issue.
- [3] R. Adalarasana and R. Malathib, "Automatic Detection of Blood Vessels in Digital Retinal Images using Soft Computing Technique", International Conference on Processing of Materials, Minerals and Energy 2017 Elsevier.
- [4] Bhuiyan, A., Nath, B., Chua, J., "An Adaptive Region Growing Segmentation for Blood Vessel Detection from Retinal Images.", Proceedings of the Second International Conference on Computer Vision Theory and Applications, Barcelona, Spain, March 8- 11, 2007, Volume 1
- [5] S. Kankanahalli, P. M. Burlina, Y. Wolfson, D. E. Freund, and N. M. Bressler, "Automated Classification of Severity of Age Related Macular Degeneration from Fundus Photographs," ARVO journals, vol. 54, no. 3, 2013.
- [6] Shishir Maheshwari, Ram Bilas Pachori, and U. Rajendra Acharya, "Automated Diagnosis of Glaucoma Using Empirical Wavelet Transform and Correntropy Features Extracted from Fundus Images", 2015 IEEE.
- [7] Mike Voets, Kajsa Mllersen, Lars Ailo Bongo, "Replication study: Development and validation of a deep learning algorithm for detection of diabetic retinopathy in retinal fundus photographs", arXiv:1803.04337v3 [cs.CV] 30 Aug 2018.
- [9] A. ELBALAOUI, M. FAKIR, K. TAIFI, A. MERBOUHA, "Automatic Detection of Blood Vessel in Retinal Images", 2016 13th International Conference Computer Graphics, Imaging and Visualization.
- [10] Saima Waseem, M. Usman Akram, Bilal Ashfaq Ahmed, "Drusen detection from colored fundus images for diagnosis of age related Macular degeneration", 7th International Conference on Information and Automation for Sustainability, IEEE, 2014.
- [11] Elisa Ricci and Renzo Perfetti "Retinal Blood Vessel Segmentation Using Line Operators and Support Vector Classification", IEEE TRANSACTIONS ON MEDICAL IMAGING, VOL. 26, NO. 10, OCTOBER 2007.
- [12] M. Caroline Viola Stella Mary, Elijah Blessing Rajsingh, Member IEEE and Ganesh R. Naik, Senior Member IEEE "Retinal Fundus Image Analysis for Diagnosis of Glaucoma.
- [13] Ramon Pires, Sandra Avila, Herbert F. Jelinek, Jacques Wainer, Eduardo Valle, and Anderson Rocha, "Beyond Lesion-based Diabetic Retinopathy: IEEE Journal of Biomedical and Health Informatics 2015 IEEE.
- [14] Sohini Roychowdhury, Dara D. Koozekanani, and Keshab K. Parhi "DREAM: Diabetic Retinopathy Analysis using Machine Learning" IEEE Journal of Biomedical and Health Informatics 2013 IEEE.