



iJRASET

International Journal For Research in
Applied Science and Engineering Technology



INTERNATIONAL JOURNAL FOR RESEARCH

IN APPLIED SCIENCE & ENGINEERING TECHNOLOGY

Volume: 3

Issue: V

Month of publication: May 2015

DOI:

www.ijraset.com

Call:  08813907089

E-mail ID: ijraset@gmail.com

Diabetic Retinopathy Screening

Prasad More¹, Shrikant Birari²

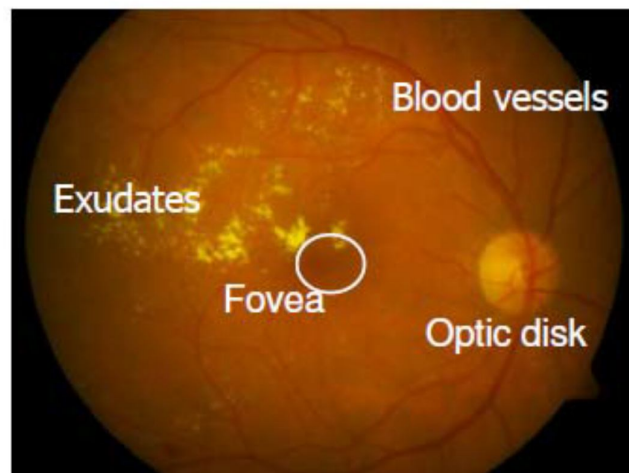
Student, Dept of E&Tc, DR DY Patil School of Engineering, Pune

Abstract – using fundus camera, we capture the images of eye and find out the disorders in retina. These images are to be processed for better diagnosis and planning of treatment. Retinal image segmentation is greatly required to extract certain features that may help in diagnosis and treatment. Also these diagnosis may use or dierenr purposes for eye treatment. This paper introduces a survey for classification and segmentation of real time eye images

Keywords— ANN, SVD, PCA, Image processing.

I. INTRODUCTION

Diabetic retinopathy is a common retinal cause associated with diabetes .In earlier days diabetic is the very wide issue. The early detection of diabetic can help people to reduce the blindness up to 50%. The diabetic for the longer time the person suffering by diabetic retinopathy. The diabetic retinopathy means the causes on the retina. In concert to similar works currently going on, we propose, such as diabetes detection method using Artificial Neural Network (ANN) and a feature set formed adopting Singular Value Decomposition (SVD) and Principal Component Analysis (PCA). Then, we apply a composite feature set adopting Single value decomposition SVD and PCA sample values of the Fundus retinal image for use with an ANN. Color fundus images are used to detect exudates in retinal images. Fig. 1shows a fundus image of an suffer retina with its main features and exudates. if detected during retinal examination, it proceeds for further medical tests.



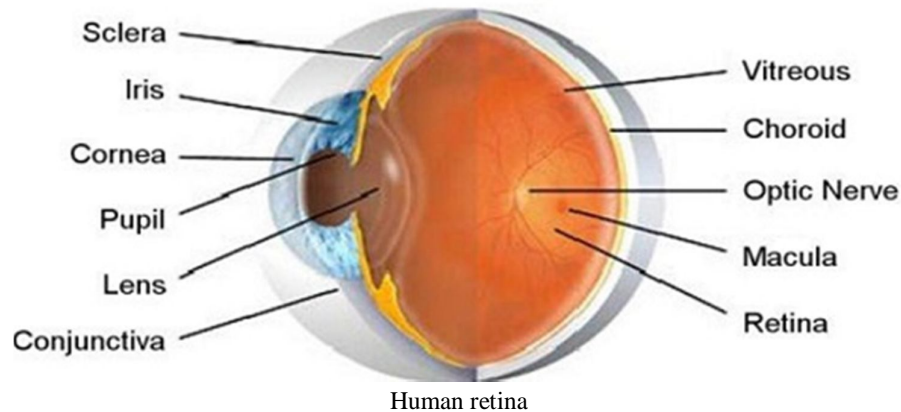
II. LITERATURE SURVEY

Research in retina image analysis have spanned for almost 25 years. It is known to be a complex task because of its variability of the images, anatomical-pathological structures and the appearance of visually similar clinical signs. All these factors can lead to erroneous interpretation of the image. This part of the chapter attempts to define a timeline over the past two decades on the various techniques used to detect both anatomic structures such as optic disc, blood vessels and clinical signs such as micro aneurysms, exudates and haemorrhages.

A. Anatomic Structures Of The Retina

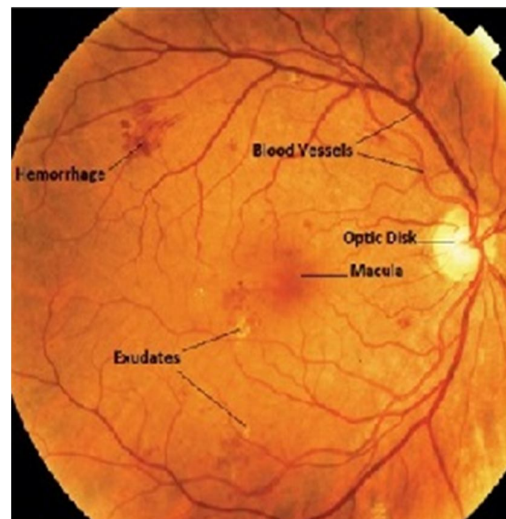
The retina consists of three main anatomic components, the optic disc, blood vessels and the macula. It is essential to detect these components as well and at later stages, use it as a means to remove false positives to facilitate accurate detections of other clinical signs.

International Journal for Research in Applied Science & Engineering Technology (IJRASET)



B. Clinical Signs

DR clinical signs include micro aneurysms, exudates and hemorrhages. In this section, the literature of detecting these DR clinical signs is discussed.



Diabetic retinopathy

C. Optic Disc Detection

Optic disc detection is necessary for diagnosing of any pathological disease in retina images. The advantages for locating the position of the optic disc are numerous. Firstly, the shape and size of the optic disc changes dramatically during the course of the disease denoting the severity of the disease. Secondly, it would help with the locating of other anatomic structure such as the macula and blood vessels. Lastly, locating the actual position of the optic disc will improve the bright lesion detection Performance by removing potential false positive regions as they share similar visual characteristics with other bright pathological signs. On the other hand, because of such similarity, locating the optic disc is challenging when other bright lesions are also present in images and can be mistaken as optic disc. Furthermore, finding the boundary of the optic disc are made difficult by the irregular shapes of the optic disc in pathological cases as well as the appearance of blood vessels within the optic disc. Uneven illumination due to the nature of the retina and the environment in which the image is acquired are also factors that cause problems in detecting the optic disc.

D. Blood Vessel Detection

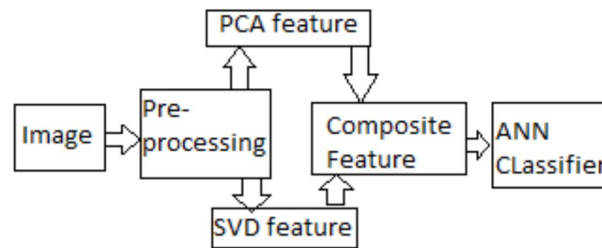
Blood vessels are one of the main components in the retina and it has been found that in several pathological diseases, the changes in the appearances and the structure of the blood vessels such as the diameter or tortuosity can help diagnose the severity of the diseases. Furthermore, the location of the blood vessels can aid in the detection of other anatomical structures such as the optic disc and the macula. Therefore, detection of the blood vessels is imperative in an automated screening system. Their characteristics are such that they appear darker as compared to the background and they gradually decrease in width as

International Journal for Research in Applied Science & Engineering Technology (IJRASET)

they grow from the optic disc. Segmentation of the blood vessel from the background is complex due to the uneven illumination in retinal images. If the image's histogram is bi-modal where there are two distinct peaks, thresholding could be easily applied to segment the blood vessel from the background.

E. EXUDATES

Exudates are lipid and lipoproteins deposits that leak from micro aneurysms and are one of the common clinical signs occurring in early diabetic retinopathy. This makes their early detection imperative to the contribution of retina image analysis. In retina images, exudate appear as small yellowish sharp objects, varies in shape and sizes and are well contrasted with the background. The difficulties in detecting exudates are that they are not the only bright features in the retina image. Other features such as optic disc, cotton wool spots and druses also have very similar characteristics in terms of shape, size and color.



Block diagram of composite SVD and PCA -ANN based approach

F. Principal Component Analysis

Principal component analysis (PCA) is a useful statistical technique to identify patterns within data (image regions). PCA represents the data by aligning a series of axes in the direction of data variance i.e. the first component is aligned to the largest percentage of the total variance and each subsequent axis contains the maximum variance for any axes orthogonal to the previous component. As the importance of information from each subsequent axis diminishes, only the first 10 principal components are used as image features; these are extracted from the green component of the RGB color model, Fourier and Prewitt transforms. To calculate the PCA of an image, the mean of each data dimension is first subtracted from the values in that dimension, producing a data set whose mean is zero. The disparity of each dimension from the mean with respect to each other is determined by calculating the covariance of each dimension pair, thus producing a covariance matrix. The eigenvectors of the covariance matrix extracts lines that characterize the data. Ordering the eigenvectors by eigenvalue, highest to lowest gives the components in order of significance as the eigenvector with the highest eigenvalue is the principal component.

G. Regional Shape Descriptors

Regional features provide discriminating information between similar shaped regions and background. Regional features extracted include: area, perimeter, major and minor axis lengths, compactness, convex area, eccentricity, solidity, and equivalent diameter.

- 1) Area number of pixels contained within boundary
- 2) Perimeter pixel length of the boundary
- 3) Compactness $\text{perimeter}^2 / \text{area}$ dimensionless value that is insensitive to scale and orientation changes.
- 4) Major Axis length of straight line joining two furthest points.
- 5) Minor Axis length of straight line joining two furthest points perpendicular to major axis
- 6) Eccentricity ratio between major and minor axis
- 7) Convex area area of the smallest convex hull encapsulating the boundary.
- 8) Solidity Area/Convex Area proportion of pixels in both convex hull and region.
- 9) Equivalent diameter $\sqrt{4 * \text{Area} / \pi}$ diameter of a circle with the same area as the region

IV. ADVANTAGES

Increase accuracy of retina treatment upto 80% using retinopathy .also within short time give good result. Using PCA and ANN, the feature extraction is very easy and gives a result in short time. retinopathy shows the early stages and last stages of diabetics.

V. CONCLUSION

In this work, a composite feature set is used for detection of diabetes using ANN. The feature set formed using PCA and SVD components provide satisfactory performance. It shows at least 2-3% Improvement in accuracy and 5-8% lowering of

International Journal for Research in Applied Science & Engineering Technology (IJRASET)

processing time compared to the case when the entire Image is used as a feature. The framework thus proposed provides certain insight into the Development of a bloodless diagnostic approach for detection of diabetes.

VI. ACKNOWLEDGMENT

I would like to thank my project guide Mr. B.K. Shiragapur for supporting us and helping us overcoming every problem. I would like to thank my friends and family to supporting me in completing my project successfully.

REFERENCES

- [1] Abandah, G., Younis, K. and Khedher, M. (2008). Handwritten Arabic Character Recognition Using Multiple Classifiers Based on Letter Form, International Conference on Signal Processing, Pattern Recognition, & Applications, pp. 128-133.
- [2] Archana deka & kandarpakumar Sharma "ANN based detection of diabetes using retinopathy".
- [3] U. M Chaskar, M. S. Sutaone "On a Methodology for Detecting Diabetic Presence from Retina Image Analysis".
- [4] Anitha Mohan¹, K. Moorthy² "Early Detection of Diabetic Retinopathy Edema Using FCM."
- [5] Bernhard M. Ege, et al, "Screening for diabetic retinopathy using computer based image analysis and statistical classification" Elsevier, Computer Methods and Programs in Biomedicine 62 (2000) 165–175.
- [6] Oliver Faust & Rajendra Acharya U. & E. Y. K. Ng & Kwan-Hoong Ng & Jasjit S. Suri "Algorithms for the Automated Detection of Diabetic Retinopathy Using Digital Fundus Images: A Review"
- [7] A. Aquino, Gegundez-Arias, M.E.Marin: "Detecting the Optic Disc Boundary in Digital Fundus Images Using Morphological, Edge Detection, and Feature Extraction Techniques", IEEE Transactions on Medical Imaging, vol. 29, pp. 1860 - 1869, Huelva, Spain, 2010.
- [8] Oliver Faust & Rajendra Acharya U. & E. Y. K. Ng & Kwan-Hoong Ng & Jasjit S. Suri "Algorithms for the Automated Detection of Diabetic Retinopathy Using Digital Fundus Images: A Review"
- [9] Diabetic Retinopathy, ..<http://www.craigbergermd.com/diabeticRetinopathy.htm>". Accessed in May 2012.
- [10] Anatomy and Structure of Human Sense Organs, ' <http://www.scientificpsychic.com/workbook!chapter2.htm>". Accessed in November 2013.



10.22214/IJRASET



45.98



IMPACT FACTOR:
7.129



IMPACT FACTOR:
7.429



INTERNATIONAL JOURNAL FOR RESEARCH

IN APPLIED SCIENCE & ENGINEERING TECHNOLOGY

Call : 08813907089  (24*7 Support on Whatsapp)