



iJRASET

International Journal For Research in
Applied Science and Engineering Technology



INTERNATIONAL JOURNAL FOR RESEARCH

IN APPLIED SCIENCE & ENGINEERING TECHNOLOGY

Volume: 7 Issue: XII Month of publication: December 2019

DOI: <http://doi.org/10.22214/ijraset.2019.12057>

www.ijraset.com

Call: ☎ 08813907089

E-mail ID: ijraset@gmail.com

Protocols and Various Imaging Modalities in Female Infertility

Ms. Geetashree Majumdar¹, Dr. R. P Bansal²

^{1, 2}NIMS University, Shobha Nagar, Jaipur

Abstract: Infertility in females is multi-factorial in origin. Though hysterosalpingography is the gold-standard investigation, USG is usually the first-line investigation for female infertility. MRI has expanded the usefulness of imaging. This pictorial essay reviews the role of imaging in the evaluation of female infertility.

Keywords: Infertility, Hysterosalpingography, Ultrasonography

I. INTRODUCTION

Infertility means not being able to get pregnant after one year of trying or six months if the woman is 35 or older^{1,2}. Women who can get pregnant but are unable to stay pregnant may also be infertile³. For healthy couples in their 20s or early 30s, the chance that a woman will become pregnant is about 25–30% in any single menstrual cycle. This percentage decreases rapidly after age 37 years. By age 40 years, a woman's chance of getting pregnant drops to less than 10% per menstrual cycle¹.

Basically pregnancy is the result of multi-step process: 4,5

- 1) *Ovulation:* A woman's body releases an egg from one of her ovaries.
- 2) *Womb:* The egg goes through a fallopian tube towards the uterus.
- 3) *Fertilization:* A man's sperm fertilizes the egg along the way.
- 4) *Implantation:* The fertilized egg attaches to the inside of the uterus. Infertility can happen if there are problems with any of these steps.

Infertility is not just a woman's problem. About one third of infertility cases are caused by women and one third are due to the man.

The other cases are caused by a mixture of male and female problems or by unknown problems. Pelvic causes of female infertility are varied and range from ovarian to tubal and peritubular abnormalities, uterine and cervical disorders⁶.

PCOS is a type of abnormality that can affect periods, fertility, hormones. It can also affect long-term health^{8,9}. Estimates of how many women it affects vary widely from 2 to 26 in every 100 women. Polycystic ovaries are slightly larger than normal ovaries and have twice the number of follicles (fluid-filled spaces within the ovary that release the eggs when a lady ovulates)¹³. As ultrasound examination of such cases is easy, available, cheap and less invasive than hormonal assessment, it is commonly used in patients with suspected PCO³. Ultrasound examination was performed between cycle days 2 and 7 with a 7 MHz Transvaginal transducer (Logic 400; General Electric, Milwaukee, USA)^{11,12}

A. AIM

To discuss various protocols of female infertility.

To evaluate the various pathological findings in female infertility

To determine the common age group scanned in USG, MRI and X RAY units.

II. METHODOLOGY

A retrospective cross-sectional design was used. A secondary source of data was used for the study. It was obtained from the x ray, USG, MRI unit, Pub Med, books radiology record book in the department at NIMS Hospital, All records with requests for X RAY, USG, and MRI with an indication of female infertility.

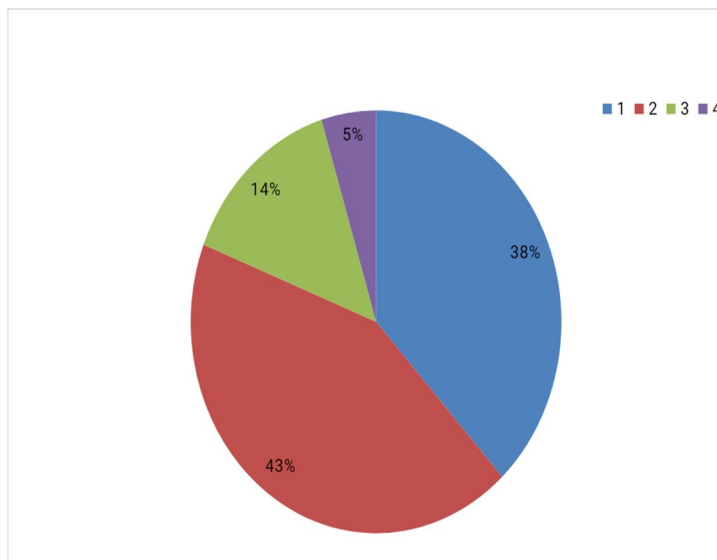
- 1) *Sample Size:* A population study was conducted.
- 2) *Inclusion Criteria:* Polycystic ovarian syndrome Fibroids Hydrosalpinx Tumors
- 3) *Instrument of data Collection:* Digital radiography, ultrasound machine and 1.5 tesla MRI machine of the radiology Department

III. RESULTS

The sample studied consisted of 72 infertile women. Regarding age, 64.5% were 20–29 years old, 20.0% were 30-39 years old, 11,8% were 40-49 years old. The sample studied consisted of 72 women of the age range of 19-45 were referred for pelvis study to the department of Radio-diagnosis with a clinical suspicion of PCOD, PID, hydrosalpinx, tubal blockage during the study period. Twenty one (21) patients were in HSG study while fifty one (51) were collected from USG study.

In HSG study, majority of the patients that fall within the age group with the highest patients i.e. 25-30 years. Regarding the types of study, normal cases are 28% and abnormal cases are 72%.

In USG study the majority of the patients that fall within the age group with highest patient i.e 19-24 years. The total number of normal cases are 20 which is 39% and the total number of abnormal cases are 31 which is 61%



Age Wise Distribution Of HSG Patients (HSG) For The Month Of Jan-2019

NO OF PATIENTS	NO. OF CASES	% OF CASES
20-25 YRS	03	50%
25-30 YRS	02	33%
30-35 YRS	01	17%
35-40 YRS	0	0%
TOTAL	06	

IV. DISCUSSION

The study was carried at radiology department of NIMS hospital, Shobha Nagar, Jaipur, Rajasthan from Jan-2019 March 2019. The study includes “protocols and various imaging modalities in female infertility”.

This study consists of 72 infertile female which are scanned in different imaging modalities. In HSG study, majority of the patients that fall within the age group with the highest patients i.e. 25-30 years. Regarding the types of study, normal cases are 28% and abnormal cases are 72%.

The common abnormality that I observed in my study is B/L tubal blockage (75%). Number of failure study is only one.

In USG study the majority of the patients that fall within the age group with highest patient i.e. 19-24 years. The total number of normal cases are 20 i.e 39% and the total number of abnormal cases are 31 i.e. 61%. The common cause of infertility that is observed in my study period includes polycystic ovarian disease, uterine fibroids, uterine cyst and pelvic inflammatory disease.

Polycystic ovarian disease=22%

Pelvic inflammatory disease=8% Uterine fibroids=19%

Uterine cyst=12%

REFERENCES

- [1] October 2017 by the American college of obstetricians and gynecologist..
- [2] OkekeTochukwu C. ¹*, Kennedy K. Agwuna², Cyril C. Ezenyeaku³, Lawrence.
- [3] Ali heba ibrahim¹ "Ultrasound assessment of polycystic ovaries: Ovarian volume and morphology; which is more accurate in making the diagnosis". The Egyptian journal of radiology and nuclear medicine- march 2016
- [4] Gilani Prof. dr. Syed Amir MBBS(pb)DMRD, MPH Ph.D (public health) ph.D (ultrasound) "ultrasound in female infertility"
- [5] Irani Szmelskyi DipAc MSc MBACc, Alan O. Szmelskyj Do MSc Adv DipClinHyp FRSPH, in Acupuncture for IVF and assisted reproduction 2015, "Anatomy and physiology of the reproductive system"
- [6] Jessica N. Sosa stanley¹, Dina C Peterson² "anatomy , abdomen and pelvis, uterus" feb,2019.
- [7] National Vulvodynia Association 2019/all rights reserved/NV Apolicies
- [8] Takeda S, Morioka I, Miyashita K, Okumura A, Yoshida Y, Matsumoto K. Age variation in the upper limit of hearing. Eur J Appl Physiol Occup Physiol 1992;65:403-8.[Medline].
- [9] Hackelöer B J. PMID:6730066 The role of ultrasound in female infertility management.
- [10] B.-Joachim Hackelöer University of Marburg, D-3550 Marburg, West Germany "The role of ultrasound in female infertility management" Science Direct Recommendations
- [11] Nefise Nazli Yenigul* and Ozge Cicek Department of Obstetrics and Gynecology, Esenler Maternity and Children's Hospital, Istanbul, Turkey. *Corresponding author: Nefise Nazli Yenigul, Department of Obstetrics and Gynecology, Esenler Maternity and Children's Hospital, Istanbul, Turkey, E-mail: drnaz84@yahoo.com Received date: March 29, 2016; Accepted date: April 28, 2016; Published date: May 05, 2016 "The Role of Three Dimensional Ultrasonography in Female Infertility"
- [12] Grigore M, Mare A. Rev Med Chir Soc Med Natlasi. 2009 Oct-Dec; 113(4):1113-9. Review. PMID: 20191884 "Application of 3D ultrasound in female infertility"
- [13] Mohamed Momtaz, M.D. Cairo, Egypt "The value of 3D ultrasonography in infertility management" Middle East Fertility Society Journal Copyright Middle East Fertility Society Vol. 11, No. 2, 2006
- [14] Tochukwu C. Okeke¹*, Kennedy K. Agwuna², Cyril C. Ezenyeaku³, Lawrence C. Ikeako³. "Application of ultrasonography in female infertility: a comprehensive Review" September-October 2015 · Volume 4 · Issue 5 Page 1246 .International Journal of Reproduction, Contraception, Obstetrics and Gynecology Okeke TC et al. Int J Reprod Contracept Obstet Gynecol. 2015 Oct;4(5):1246-1256



10.22214/IJRASET



45.98



IMPACT FACTOR:
7.129



IMPACT FACTOR:
7.429



INTERNATIONAL JOURNAL FOR RESEARCH

IN APPLIED SCIENCE & ENGINEERING TECHNOLOGY

Call : 08813907089  (24*7 Support on Whatsapp)