



iJRASET

International Journal For Research in
Applied Science and Engineering Technology



INTERNATIONAL JOURNAL FOR RESEARCH

IN APPLIED SCIENCE & ENGINEERING TECHNOLOGY

Volume: 8 Issue: IV Month of publication: April 2020

DOI: <http://doi.org/10.22214/ijraset.2020.4004>

www.ijraset.com

Call: ☎ 08813907089

E-mail ID: ijraset@gmail.com

A Review on Glaucoma Disease Detection by using Fundus Images of Eye

Payal Rabade¹, Radhika Harne²

¹M.Tech Student, ²Assistant Professor, Department of Electronics Engineering, Government College of Engineering Amravati, Maharashtra, India.

Abstract: Glaucoma is the Second leading causes of blindness across the world, it is an eye disease that affects the retina and optic nerve of eye which carries signals to the eye. This disease can leads to permanent blindness if not treated at earlier stage. The increased intraocular pressure which is main cause of glaucoma damages the optic nerve which sends images to the brain, the diameter of the optic cup within optic disc region is increased due to this increased retinal pressure. The increased cup to disc ratio (CDR) results in the loss of optic nerve fibers that are connected to the retina by disc area. CDR is the important structural features for differentiating between healthy and a glaucomatous eye. The objective of this paper is to present review of methods for automated detection of Glaucoma from fundus images of eye that assist in the progressive development of computer aided systems.

Keywords: Glaucoma, Intraocular pressure (IOP), Fundus image, Cup to Disc Ratio (CDR), Optic nerve.

I. INTRODUCTION

Glaucoma is a eye disease that damages the optic nerve in the eye that carries the images that we see to our brain. In healthy eye, a transparent watery liquid called the aqueous humor circulates inside the front portion of the eye to maintain a constant healthy eye pressure. The eye continuously produces a small amount of aqueous humor, an equal amount of this liquid flows out of the eye through a microscopic drain which is known as a trabecular meshwork in the drainage angle. In case of glaucoma patients the aqueous humor does not flow through the drainage angle properly causing fluid pressure called as intraocular pressure (IOP) in the eye to increase, and this pressure causes damage to the optic nerve fibers.

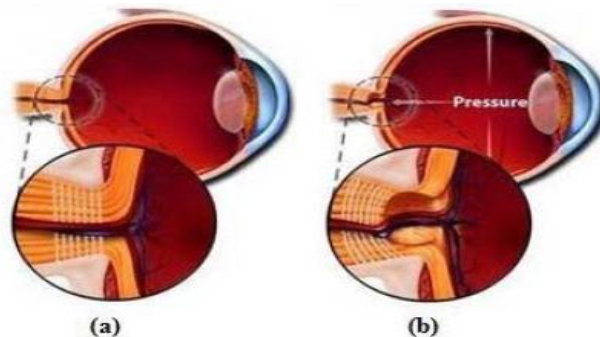


Fig.1 a) Normal eye b) Glaucoma eye.

In its early stages, Glaucoma usually does not show any symptoms. The eye's drainage canal becomes partially or completely blocked. Fluid builds up gradually in the chambers over a long period of time, and causes an increase of pressure within the eye. This pressure damages the nerve fibers, which result in patches of vision loss and may leads to total blindness at an advanced stage. Symptoms also appear gradually, starting with preferable vision loss, which may go unnoticed until the central vision is affected. Blind spot developed due to damage to the optic nerve fibers which usually go undetected until optic nerve is significantly damaged thus the early detection followed by treatment is the key to prevent vision loss from glaucoma. The main components of retina are Optic Disk(OD), Optic Cup (OC), and Neuroretinal rim (NRR). Optic disc is the round area in the back of the eye where retinal fibers are collected to form the optic nerve. Optic disc(OD) can be divided into two parts central bright part called the optic cup(OC) and peripheral part called neuroretinal rim. The relationship between OD and OC give rise to a definition called cup-to-disk ratio (CDR). As the intraocular pressure in the eye increases, the cup size also increase due to which the CDR value also increases.

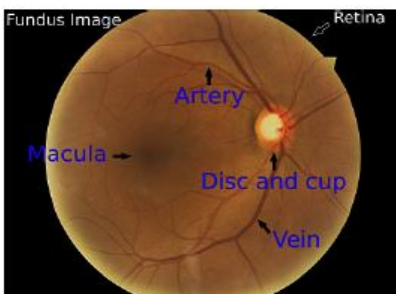


Fig.2 Fundus image of normal eye. [1]

CDR is widely used by health care professional for detection of the glaucoma disease. Hence CDR is a fundamental measure of detecting damage done by Glaucoma. CDR is calculated as follows,

$$CDR = \frac{\text{Area Cup}}{\text{Area Disc}} \dots [1]$$

If $CDR \geq 0.6$ then it is glaucoma eye otherwise it is not. In addition to this normal eye follows the ISNT rule. It is a characteristic pattern in which the inferior region is broader followed by superior, then nasal and then temporal region, the eye affected by glaucoma do not follow this rule.

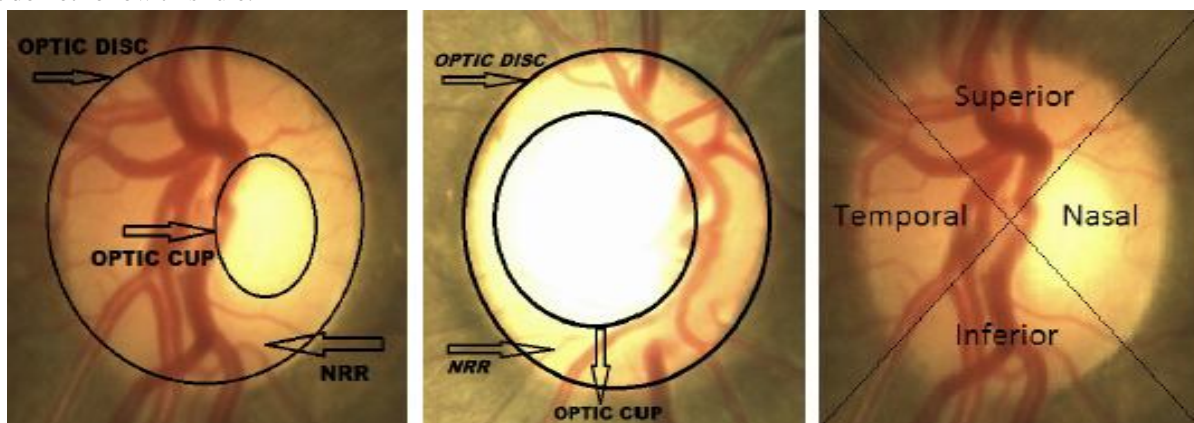


Fig 3. Left To Right : a) Normal eye disc b) Glaucomatous eye disc c) ISNT quadrant [5]

The common risk factors are having high internal eye pressure (intraocular pressure), age above 60, family history of Glaucoma such as a sibling or parent with Glaucoma, injuries to the eye such as sport injuries or a history of multiple eye surgeries for chronic eye condition, having certain medical condition such as diabetes, heart disease, high blood pressure and sickle cell anaemia, having certain types of eye surgery, taking corticosteroid medication, especially eye drops for long time. In the early stages of the disease, there are no symptoms of vision loss while with the disease progresses the loss of peripheral vision occurs. In the advance stage the patients may suffer from the total blindness. As the number of people suffering from glaucoma increasing rapidly, advanced research using various image processing techniques are applied to overcome the problem for early detection of glaucoma. The digital colour fundus image has been widely used in recent years to diagnose glaucoma as it is cost effective as compared to other technique i.e. optical coherence tomography (OCT) and Heidelberg retinal tomography (HRT).

II. LITERATURE SURVEY

Fig.4 shows generic block diagram of automated glaucoma detection. When fundus image is captured, various noise may get added to the image this happens due to varying condition during image capture. Pre-processing of fundus image improves the image data by suppressing the distortions and also enhance some image features for further processing. Feature extraction includes various algorithms for detection of various desired structural features from the fundus images. Fundus image classification analyses various image features extracted and organizes the data into categories which are normal eye and Glaucoma eye. Many works have been done so far towards automated glaucoma detection using fundus image. CDR is the fundamental measure of automated glaucoma detection using fundus image. Localizing Optic disk and Optic cup is a challenge task due to intensity variations within the Optic disk and its vicinity.

Juan Carrillo, Lola Bautista et al.[1] gives computational tool for automatic glaucoma detection from fundus image of the eye. The presence of the cup in the disc is a strong indicator of glaucoma, a method to detect glaucoma was presented by properly detecting the location of the cup. The disc segmentation was done by thresholding, the vessel segmentation was done using edge detection, and for the cup segmentation it was presented a method that uses the vessels and the cup intensities, after that CDR ratio is measured. The absolute error was 8.6% and the relative error was 19.2%. There was a success of 88.5% for the detection of the glaucomatous cases.

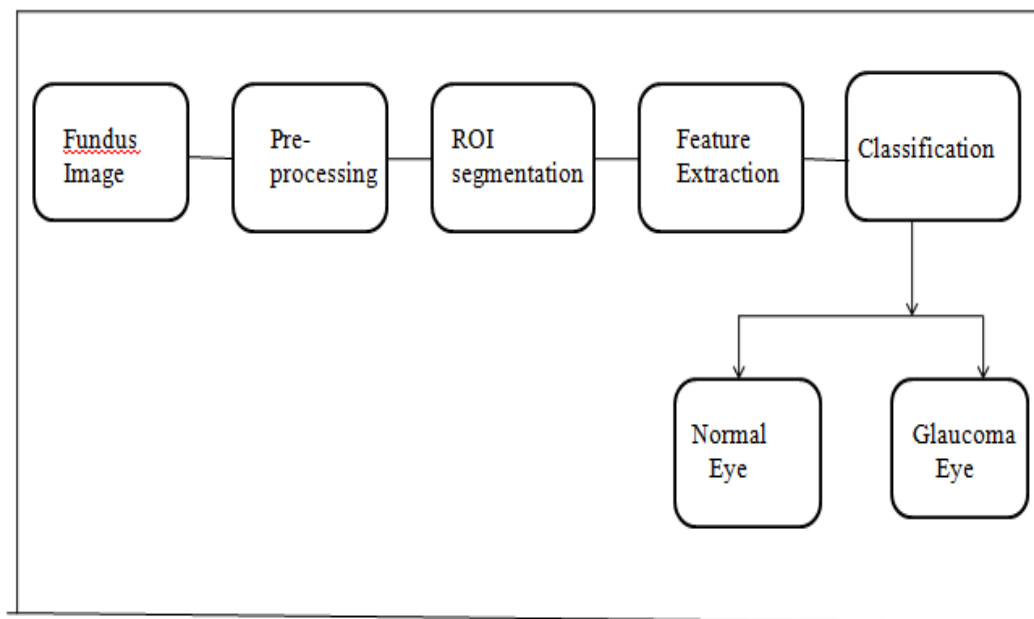


Fig .4 Generic block diagram of automated Glaucoma detection.

Namita Sengar, Malay Kishore Dutta et al.[2] presented an automated system for detection of suspected glaucoma by using hemorrhages detection in a particular region ,this method detect the suspected glaucoma automatically by using hemorrhages detection in particular region of interest (ROI)which makes this method efficient and computationally fast. The ROI segmentation is used for hemorrhages detection in particular region for automatically detecting suspected glaucoma. The optic disc and hemorrhages are segmented in a particular region automatically by using adaptive thresholding and some geometrical features. This algorithm achieves accuracy of 93.57% on digital fundus images for detection of suspected glaucoma.

J. Ayub, J. Ahmad et al. [3] proposed an efficient and novel method for calculation of CDR using combination of k-means clustering and intensity weighted centroid method. Region of interest (ROI) obtained by using intensity weighted centroid method which is followed by pre-processing and recursively applied k-mean clustering segmentation for the detection of Optic cup (OC) and optic disc (OD).

Ellipse fitting is applied for boundary smoothening of OC and OD. Proposed approach gives an accuracy of 92% for glaucoma, but they do not take into account the vascular system that goes throughout the disc which interferes with the precision of detecting the correct pixels that belong to the disc.

Mohammad Aloudat and Miad Faezipour [4] proposed a novel method for Glaucoma detection based on red area percentage level of the extracted portion of eye sclera, segmenting eye sclera is difficult especially with red eyes that usually exist in the case of Glaucoma. A specific part of sclera was extracted and red area percentage was calculated as the average of the white and black pixel in the extracted part of the sclera.

Fauzia Khan, Shoaib A. Khan et al. [5] designed an algorithm to identify glaucoma which uses morphological techniques to extract two major features for detection of Glaucoma i.e. Cup to Disc Ratio and area ratio of NRR in inferior, superior, temporal and nasal quadrants i.e. (ISNT quadrants) to check whether it obeys or violates the ISNT rule. The proposed method achieved accuracy of 94%.

III.SUMMARIZED WORKDONE

Table1. Shows the comparative study of various methods and their performance analysis for automated glaucoma detection from fundus image.

Reference	Method	Features	Dataset	Performance Analysis
1	Disc segmentation by thresholding, vessel segmentation by edge detection.	CDR measurement	Set of 26 fundus images of both healthy and non healthy eyes of local patients dataset.	Absolute error-8.6% Relative error-19.2% Success rate -88.5%
2	Optic disc and hemorrhages are segmented by using adaptive thresholding and some geometrical features.	Hemorrhages detection in particular region.	140 fundus images are tested in which 40 images are suspected glaucoma and 100 normal images collected from local hospital.	Accuracy -93.57%
3	Intensity weighted centroid method followed by k-mean clustering segmentation.	CDR measurement	100 fundus image form Armed force institute of ophthalmology, Pakistan.73 images of normal eyes while 27 are glaucomatous.	Accuracy-92%
4	Segmentation of eye iris using Circular Hough Transform method and extraction of portion of eye sclera.	Red area percentage (RAP) of extracted portion of eye sclera.	100 facial images in which 50 healthy images ,50 non healthy images.	AVG of RAP of all normal eye cases - 0.24 AVG of RAP of all glaucoma cases -0.97
5	Morphological operation for Glaucoma detection.	CDR, area ratio of Neuro retinal rim(NRR) in ISNT quadrant.	50 retinal images were collected in total 13 digital retinal images were taken from Hamilton Eye Institute (HEI-MED)19 images were taken from Friedrich-Alexander University of Erlangen-Nuremberg database library and 18 images were taken from MESSIDOR .	Accuracy – 94%

IV.CONCLUSION

Most of the people are unaware of the disease and suggested for retinal examination for early disease detection and treatment. The disease leads towards loss of vision due to damaged optic nerve cells. The damage done by glaucoma is irreversible. Early detection and treatment of glaucoma is the only way to prevent vision-loss. Pre-processing, segmentation, feature selection, and classification are the steps for the disease diagnosis discussed. Different segmentation methods as a region of interest and a number of texture, colour, intensity based features are selected for feature set classification. Automated glaucoma detection using fundus image is cheap and suitable for glaucoma detection .

V. ACKNOWLEDGMENT

I would like to give my sincere gratitude to my research guide Ms. Radhika Harne, Assistant Professor, Government college of Engineering Amravati, for their proper guidance, invaluable suggestions and support. I would express my profound gratitude to Dr. D.V. Rojatkhar, Head of department Electronics, Mr. Samrat Thorat, Assistant Professor, Government college of Engineering Amravati, for giving me an opportunity to work on a project that was challenging and interesting for me.

REFERENCES

- [1] Juan Carrillo, Lola Bautista, Jorge Villamizar, Juan Ruedaz, Mary Sanchez and Daniela rueda "Glaucoma detection using fundus image of the eye". 2019 XXII Symposium on Image, Signal Processing and Artificial Vision (STSIVA).
- [2] Namita Sengar, Malay Kishore Dutta, Radim Burget, Martin Ranjoha "Automated Detection of Suspected Glaucoma in Digital Fundus Images". 2017 40th International Conference on Telecommunications and Signal Processing (TSP).
- [3] J. Ayub, J. Ahmad, J. Muhammad, L. Aziz, S. Ayub, U. Akram, and I. Basit "Glaucoma detection through optic disc and cup segmentation using K-mean clustering". 2016 International Conference on Computing, Electronic and Electrical Engineering (ICE Cube), pages 143–147, 2016.
- [4] Mohammad Aloudat and Miad Faezipour "Determination for Glaucoma Disease Based on Red Area Percentage" 2016 IEEE Long Island Systems, Applications and Technology Conference (LISAT).
- [5] F. Khan, S.A. Khan, U.U. Yasin, I. Haq, U. Qamar, "Detection of glaucoma using retinal fundus images", The 2013 IEEE Biomedical Engineering International conference (BMEi-CON 2013), pp. 1-5, October 2013.
- [6] Atheesan S., Yashothara S. "Automatic Glaucoma Detection by Using Funduscopy Images" 2016 International Conference on Wireless Communications, Signal Processing and Networking (WiSPNET).
- [7] S.M. Nikam and C.Y. Patil. Glaucoma detection from fundus images using matlab gui. In 2017 3rd International Conference on Advances in Computing, Communication & Automation (ICACCA)(Fall), pages 1–4, 2017.
- [8] B. Naveen Kumar, R.P. Chauhan, Nidhi Dahiya "Detection of Glaucoma using Image processing techniques: A Review" 2016 International Conference on Microelectronics, Computing and Communications (MicroCom).
- [9] Pavithra G., Anushree G. et al, "Glaucoma Detection using IP Technique" 2017 International Conference on Energy, Communication, Data Analytics and Soft Computing (ICECDS).
- [10] Andres Diaz, Sandra Morales et al., "Glaucoma diagnosis by means of optic cup feature analysis in color fundus images" 2016 24th European Signal Processing Conference (EUSIPCO).



10.22214/IJRASET



45.98



IMPACT FACTOR:
7.129



IMPACT FACTOR:
7.429



INTERNATIONAL JOURNAL FOR RESEARCH

IN APPLIED SCIENCE & ENGINEERING TECHNOLOGY

Call : 08813907089  (24*7 Support on Whatsapp)