



iJRASET

International Journal For Research in
Applied Science and Engineering Technology



INTERNATIONAL JOURNAL FOR RESEARCH

IN APPLIED SCIENCE & ENGINEERING TECHNOLOGY

Volume: 4

Issue: I

Month of publication: January 2016

DOI:

www.ijraset.com

Call: ☎ 08813907089

E-mail ID: ijraset@gmail.com

A Review Paper on Detection of Glaucoma using Retinal Fundus Images

Shruti Gorasia¹, Rida Anwar²

¹M.Tech Student, DIMAT, CSVTU, Bhilai, ²M.Tech Student, DIMAT, CSVTU, Bhilai

Abstract— This paper describes the various techniques used for automatic detection of glaucoma. Glaucoma is a chronic eye disease in which optic nerve is progressively damaged and hence causes partial loss of vision. If not treated properly, it may lead to blindness. The current diagnosis of this neurodegenerative disease is done by extracting different features from retinal fundus images. Mostly, the features include Cup to Disc Ratio(CDR), ratio of Neuro-Retinal Rim(NRR) in Inferior, Superior, Nasal, Temporal (ISNT) quadrants, blood vessels, Para-Papillary Atrophy(PPA) and RNFL(Retinal Nerve Fibre Layer) thickness.

Keywords: Glaucoma, Optic Nerve Head, Inter Ocular Pressure, Feature Extraction, Fundus Images

I. INTRODUCTION

A. Glaucoma

Glaucoma is the second most common cause of blindness in the world [1]. By the year 2020, about 79 million people in the world are likely to be affected by glaucoma [2]. It is a neurodegenerative disease in which there is a progressive damage to the optic nerves and the vision loss is irreversible. Glaucoma has no early symptoms or pain, thus it is required to see the doctor regularly as early detection and treatment will prevent further loss to the vision [3]. It is known as ‘silent thief of sight’ as the loss of vision occurs gradually over a long period of time and the symptoms are unseen in earlier stages. It is the group of disease that contaminates the optic nerve and the optic nerve cells which results in loss of vision [4]. It is caused due to an increase in Inter Ocular Pressure. A liquid called “aqueous” continuously flows inside the eye. This liquid creates pressure on the internal surface of the eye. In normal eye, this pressure is between 14 to 20 mmHg. If it is between 20 to 24 mmHg, it shows the symptoms of glaucoma but if it exceeds 24 mmHg, it is detected as glaucoma. In healthy eyes, there is normal balance between the fluids, one that is produced in the eye, and the second that leaves the eye through eye’s drainage system. This balance of fluids keeps Inter Ocular Pressure (IOP) constant in the eye. But in glaucoma, this balance of fluids is not maintained properly. As a result it causes an increase in IOP, resulting in the damage of optic nerve. Due to increase in IOP, the cup size begins to increase which consequently increases the Cup to Disc Ratio. The vision of normal eye and glaucomatic eye is shown in Fig.1.



Fig.1: Vision of normal eye and glaucomatic eye

The fundus image acquired from the digital fundus camera is shown in Fig.2. The total blindness due to Glaucoma in the country today is 12.8 per cent. In India, approximately 90 per cent of Glaucoma cases go undiagnosed. Glaucoma affects approximately 12 million people in India and by 2020 it will become 16 million people. Statistics say that one person out of eight persons with age of 40 years or above in India is either suffering from Glaucoma or is at the risk of the disease [5].

International Journal for Research in Applied Science & Engineering Technology (IJRASET)

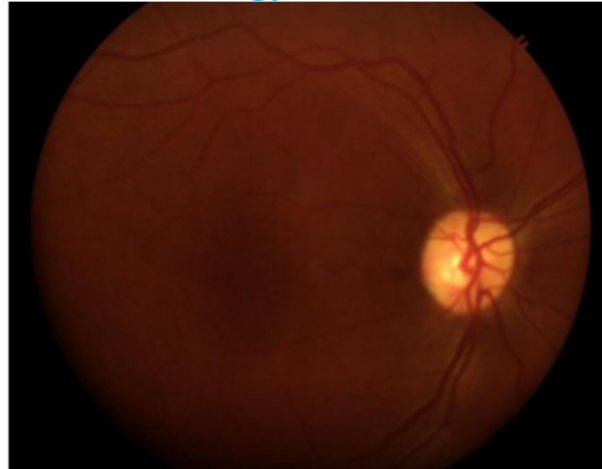

Fig.2: Acquired retinal fundus image [9]

B. Types of Glaucoma

There are various types of glaucoma but mainly two types are found i.e. open-angle glaucoma and angle-closure glaucoma. Following are the different types of glaucoma:-

- 1) *Primary open-angle glaucoma*: It is the most common type of glaucoma found in 90% of Americans. The symptoms are not noticeable in earlier stages and by the time the vision is impaired and the damage is irreversible. In this type, there is a slow clogging of drainage canal leading to the rise in IOP, resulting in the damage of optic nerve cells. If a specific number of nerve cells are destroyed, then the blind spots will begin to form in the field vision. In earlier stages, these blind spots appear in the peripheral or outer sides of the field vision and later in the center affecting the vision. Once the nerve cells are impaired, nothing can cure them, thus if vision loss occurs, it is irreversible.
- 2) *Angle-closure glaucoma*: It is less common than open-angle glaucoma among Americans. In this type, the drainage canals are blocked i.e. the flow aqueous humor between the iris and lens stops suddenly, resulting in a sudden rise in IOP. This condition need immediate medical treatment. Without the treatment, blindness occurs within two days.
- 3) *Normal tension glaucoma*: It is also known as low-tension glaucoma. In this type, the IOP is normal but still optic nerve damage and visual field loss occurs. It is thought to be related like poor blood flow to the optic nerve, leading to the death of cells. In the normal range of pressure, these eyes are susceptible to damage, thus eye pressure needs to be kept lower to prevent further loss in vision.
- 4) *Congenital glaucoma*: This type of glaucoma is common in infants or babies, thus is also called children glaucoma. It is of two types i.e. primary congenital glaucoma, is the result of incomplete or abnormal development of eye's drainage canal and secondary congenital glaucoma, is the result of disorders in eye or body, which may or may not be genetic.
- 5) *Secondary glaucoma*: Glaucoma that results from another disease is called secondary glaucoma. Pigmentary and neovascular glaucoma are secondary glaucoma. These are described below.
- 6) *Pigmentary glaucoma*: It is caused when the pigment granules that are present in the back of iris, enters into the aqueous humor that flows inside the eye. These granules flow toward the drainage canals and slowly clog them, leading to increase in eye pressure.
- 7) *Neovascular glaucoma*: It is caused by abnormal formation of blood vessels on the iris and over the drainage canals. This type of glaucoma is always associated with other diseases e.g. diabetes. The new blood vessels block the fluid from exiting through drainage canals, causing an increase in eye pressure.

II. FEATURE EXTRACTION FROM RETINAL IMAGE

ONH is an elliptical-shaped area located at the entrance of the optic nerve at the back of the eye. There are many parts of ONH that can be observed to distinguish between normal and glaucoma eyes such as disc, cup, neuroretinal rim, blood vessels and parapapillary atrophy (PPA)[8]. Following are the different features that can be extracted to detect glaucoma:

International Journal for Research in Applied Science & Engineering Technology (IJRASET)

A. CDR(Cup-to-Disc Ratio)

Thus, CDR can be used as a parameter to detect glaucoma disease [6]. As for normal disc the CDR is considered to be less than 0.5 but in case of glaucoma, it is greater than 0.5 [3]. As the cup size increases it also affects the Neuro-retinal Rim (NRR).

B. NRR(Neuro-Retinal Rim)

NRR is the region located between the edge of the optic disc and the optic cup. In glaucoma, area ratio covered by NRR in nasal and temporal regions becomes thick as compared to area covered by NRR in inferior and superior region [7].

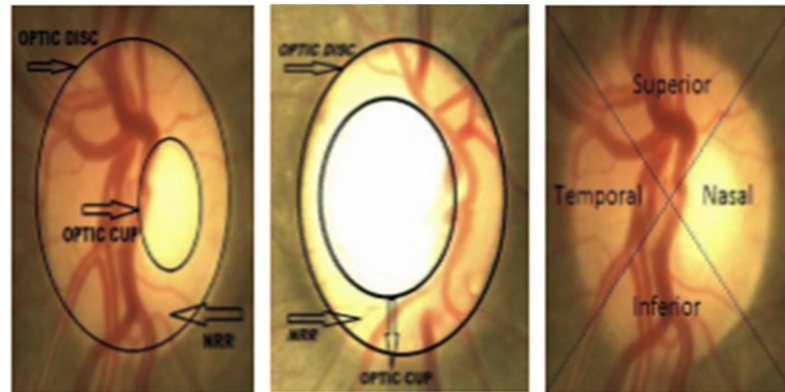


Fig.3. L to R: Normal Disc (CDR<0.5), Glaucoma tic Disc (CDR>0.5), ISNT Quadrants [8]

C. PPA(Parapapillary atrophy)

PPA is a part with crescent-shaped, which consists of two types of alpha-zone and beta-zone. Alpha zone is not affected by glaucoma while beta zone is affected more frequently in patients with glaucoma, which has the characteristic white color. Both types of PPA are located outside the area of the disc. Beta-zone is directly bordering the disc on the temporal side, while alpha-zone directly adjacent to the beta-zone [6]. The areas of alpha zone and beta-zone are shown in Fig.4.

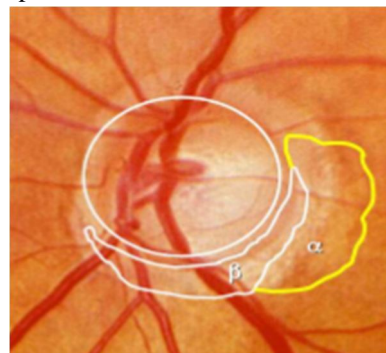


Fig.4: PPA With Alpha-Zone And Beta-Zone On The Right Eye

D. RNFL(Retinal Nerve Fibre Layer)

It looks like a bunch of scratches that a colored light is been distributed evenly on the normal eye. In normal eye RNFL mostly seen in the inferior temporal area, followed in the area of the superior temporal, superior nasal and inferior nasal [10]. RNFL can be observed by ophthalmoscopy and wide angle photos without the red color. The structure of the RNFL is shown in Fig. 5.

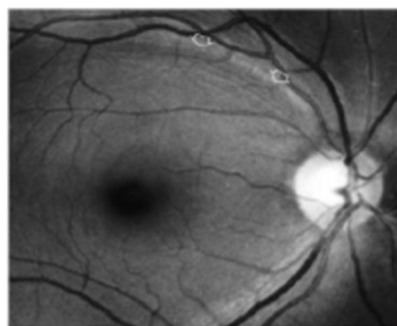


Fig.5: Structure of RNFL

International Journal for Research in Applied Science & Engineering Technology (IJRASET)

III.SURVEY OF DIFFERENT TECHNIQUES FOR THE DETECTION OF GLAUCOMA

Several studies and researches have been reported in the last few years for the detection and classification of glaucoma by extracting different features mentioned in the above section. The work is as follows:

- A. In year 2006, Kevin Noronha et al. [11] proposes different techniques to extract main features of retinal fundus images such as optic disc, fovea and blood vessels. The author finds the brightest part of the fundus and applies Hough transform to determine the optic disc and its center.
- B. In year 2007, Xu et al.[12] proposes a novel technique that modifies original snake technique. This technique is used to extract the boundary of cup and disc.
- C. In year 2008, S.Shekhar et al. [13] proposes a method in which region of interest is found first by morphological processing of fundus image and then Hough transform is used to detect optic disc.
- D. In year 2010, Zhuo Zhang et al. [14] present an online dataset which aims to share clinical retinal images with the public. The proposed method focuses on optic disc and cup segmentation based on statistical model-based methods.
- E. In year 2010, Vahabi Z et al. [15] proposed a new filtering approach to detect optic disc such as Sobel filtering, texture analysis, intensity and template matching. The algorithm is applied on 150 images of Messidor dataset.
- F. In year 2012, Nilanjan Dey et al. [16] determined CDR using Harris Corner. Harris Corner detector[17,18] is based on the local auto-correlation function of a signal.
- G. In year 2012, Geetha Ramani et al. [19] proposed a novel approach which uses image analysis and data mining techniques to categorize the retinal images as either normal, diabetic retinopathy or glaucoma affected.
- H. In year 2013, Cheng et al. [20] proposed superpixel classification methods to segment the optic disc and cup.
- I. In year 2013, Preeti et al. [9] proposed a review paper providing information about the image processing techniques for automatic detection of glaucoma. The key image processing techniques to detect glaucoma include image registration, fusion, segmentation, feature extraction, enhancement, pattern matching, image classification, analysis and statistical measurements.
- J. In year 2013, Fauzia khan et al. [8] proposed a technique for early detection of glaucoma using CDR and ratio of NRR in ISNT quadrants. The technique is implemented on 50 images and 94% accuracy is achieved in 1.42 seconds.
- K. In year 2014, Hafsa Ahmad et al. [21] proposed a technique for early detection of glaucoma using CDR and ratio of NRR in ISNT quadrants. The technique is implemented on 80 images and 97.5% accuracy is achieved in 0.8141 seconds.
- L. In year 2014, Sobia et al. [22] proposed a method in which anisotropic filtering is performed. Disc is extracted using 3 techniques i.e. edge detection method, optimal thresholding method and manual threshold analysis.
- M. In year 2015, Anindita et al. [23] proposed a review paper which consisted of all possible features that can be extracted from the retinal image and can be used as a parameter to detect glaucoma disease.

IV.PUBLICLY AVAILABLE DATABASES FOR GLAUCOMA

This section includes examples of several databases that are available publicly for automatic extraction of features to detect glaucoma.

A. STARE(Structured Analysis of the retina)

STARE database is created with the aim to develop research related to the automatic diagnosis of the human eye. This database provides 81 images consisting of 31 images and 50 with normal retinal images which suggest some diseases of the retina, such as exudate and haemorrhages that occur in the ONH [24].

B. DRIVE(Digital Retina Images for Vessel Extraction)

DRIVE is a retinal fundus image database created to develop research on the segmentation of blood vessels in retinal image. This database provides 40 images as training data and 20 images as a data testing [25].

C. HRF(High-Resolution Fundus Image Database)

This database is created to support studies on automatic segmentation algorithms on retinal fundus images. The public database contains at the moment 15 images of healthy patients, 15 images of patients with diabetic retinopathy and 15 images of glaucomatous patients.

International Journal for Research in Applied Science & Engineering Technology (IJRASET)

D. ORIGA(An Online Retinal Fundus Image Database for Glaucoma Analysis and Research)

This database was created to help with the research related to glaucoma. This database consists of 650 images (168 glaucoma and 482 non-glaucoma images). Each image data in the database is equipped with grading information for traits related to glaucoma [14].

E. RIM-ONE(An Open Retinal Image Database for Optic Nerve Evaluation)

RIM-ONE is a fundus image database generally used for research related to glaucoma disease and is focused on ONH segmentation. This database consists of 169 images. For each image of the ONH, examples of the manual segmentation are provided which are performed by five experts. Overall, the image is divided into several classes i.e. normal 118 images, early glaucoma 12 images, Moderate glaucoma 14 images, deep glaucoma 14 images and ocular hypertension (OHT) 11 images [26].

V. CONCLUSION

From the review of the above papers and different features, it can be concluded that many different techniques can be used to detect glaucoma using different features. Glaucoma is a primary cause of permanent blindness. Hence, the detection and diagnosis has to be done in its earlier stages. There is a constant research happening in this field. Here, an attempt is done to learn and understand some of the techniques used till now for the detection of glaucoma using extraction of different features.

VI. ACKNOWLEDGMENT

For this paper, a large amount of credit must go to our guide Prof. Sanjivani Shantaiya. The author expresses sincere thanks to her for her continuous assistance, patience and support in the preparation of this paper.

REFERENCES

- [1] H. A. Quigley, "Number Of People With Glaucoma Worldwide", 1996, pp. 389–393.
- [2] G. Michelson, S. Wrntges, J. Hornegger, and B. Lausen, "The papilla as screening parameter for early diagnosis of glaucoma," *Deutsches Aertzteblatt Int.*, vol. 105, pp. 34–35, 2008.
- [3] <http://www.optic-disc.org>
- [4] M.K. Nath, S. Dandapat, "Techniques of glaucoma detection from color fundus images: A Review", *IJ. Image, Graphics and signal processing*, 2012, 9, 44-51.
- [5] G. . Kriegelstein and R. . Weinreb, *Glaucoma Progress III (Essentials In Ophthalmology)*. Berlin Heidelberg: Springer-Verlag, 2009
- [6] N. T. Choplin and D. C. Lundy, Eds., "Atlas of Glaucoma", Second Edition London: Informa Healthcare, 2007.
- [7] S. Kavitha, S. Karthikeyan, "Neuroretinal rim quantification in retinal images to detect glaucoma" *IJCSNS*, Vol 10, No. 6, June 2010.
- [8] Fauzia Khan, Shoaib A. Khan, Ubaid Ullah Yasin, "Detection of Glaucoma using retinal fundus images", *IEEE* 2013.
- [9] Preeti, Jyotika Pruthi, "Review of Image Processing Technique for Glaucoma Detection", *IJCMC*, Vol. 2, Issue 11, November 13, pg.99-105
- [10] C. J. Morrison and P. I. Pollack, "Glaucoma Science and Practice", Thieme Medical Publishers, Inc, 2003.
- [11] Kevin Noronha, Jagadish Nayak, S.N. Bhat, "Enhancement of retinal fundus Image to highlight the features for detection of abnormal eyes".
- [12] J. Xu, O. Chutatape, E. Sung, C. Zheng, and P. C. T. Kuan, "Optic Disk Feature Extraction Via Modified Deformable Model Technique for Glaucoma Analysis", *Pattern Recognition*, 2007, Vol. 40, pp. 2063–2076
- [13] S. Shekhar, "Automated localization of retinal optic disk using hough transform", Department of Electrical Engineering and Electronics, University of Liverpool, UK.
- [14] Zhuo Zhang, "ORIGA-light : An Online Retinal Fundus Image Database for Glaucoma Analysis and Research", 32nd Annual International Conference of the IEEE EMBS Buenos Aires, Argentina, August 31 - September 4, 2010.
- [15] Vahabi Z, "The new approach to Automatic detection of Optic Disc from non-dilated retinal images" *Proceedings of the 17th Iranian Conference of Biomedical Engineering (ICBME2010)*, 3-4 November 2010
- [16] Nilanjan Dey, "Optical Cup to Disc Ratio Measurement for Glaucoma Diagnosis Using Harris Corner", *ICCCNT12*.
- [17] Harris C, Stephens, M., 1988, A Combined Corner and Edge Detector, *Proceedings of 4th Alvey Vision Conference*.
- [18] Konstantinos G Derpanis, 2004, The Harris Corner Detector.
- [19] R. Geetha Ramani, "Automatic Prediction of Diabetic Retinopathy and Glaucoma through Retinal Image Analysis and Data Mining Techniques".
- [20] J. Cheng, J. Liu, Y. Xu, F. Yin, D. Wing, K. Wong, N. Tan, and D. Tao, "Superpixel Classification Based Optic Disc and Optic Cup Segmentation for Glaucoma Screening", *IEEE Transactions On Medical Imaging*, Vol. 32, no. 6, 2013, pp. 1019–1032.
- [21] Hafsa Ahmad, Abubakar Yamin, Aqsa Shakeel et al., "Detection of glaucoma using retinal fundus images", *IEEE* 2014.
- [22] Sobia Naz, Sheela Rao, "Glaucoma detection in color fundus images using cup to disc ratio", *IJES* 2014.
- [23] Anindita Septiarni, Agus Harjoko, "Automated glaucoma detection based on the type of features used: A Review", *JATIT* 2015.
- [24] M. Goldbaum, *Structured Analysis of the Retina (Stare)*, 2000. URL <http://www.ces.clemson.edu/~ahoover/stare/>
- [25] J. Staaf, M. Abramoff, M. Niemeijer, M. Viergever, B. V. Ginneken, and ., "Ridge Based Vessel Segmentation in Color Images of the Retina", *IEEE Transactions On Medical Imaging*, Vol. 23.
- [26] F. Fumero, S. Alayon, J. L. Sanchez, J. Sigut, and G. M. Hernandez, "RIM-ONE : An Open Retinal Image Database for Optic Nerve Evaluation", *Proc. 24th Int. Symp. Comput. Med. Syst.*, 2011, pp. 2–7.



10.22214/IJRASET



45.98



IMPACT FACTOR:
7.129



IMPACT FACTOR:
7.429



INTERNATIONAL JOURNAL FOR RESEARCH

IN APPLIED SCIENCE & ENGINEERING TECHNOLOGY

Call : 08813907089  (24*7 Support on Whatsapp)