



iJRASET

International Journal For Research in
Applied Science and Engineering Technology



INTERNATIONAL JOURNAL FOR RESEARCH

IN APPLIED SCIENCE & ENGINEERING TECHNOLOGY

Volume: 6 Issue: XI Month of publication: November 2018

DOI:

www.ijraset.com

Call:  08813907089

E-mail ID: ijraset@gmail.com

Morphology of Schistosoma Spindale as Studied under Scanning Electron Microscopy (SEM)

Vanita Malewar¹, Aruna Karemungikar², Parvathi J³

^{1, 2, 3}Osmania University, Hyderabad, India

Abstract: *Schistosoma spindale* is a trematode infecting *Bubalus bubalis*. *S. spindale* causes hepato-intestinal Schistosomiasis. It is the fifth major helminthiasis of domestic animals in the Indian sub-continent(1). Helminth infections are often characterized by marked cellular responses such as eosinophilia. Animals with heavy infection suffer from anaemia, debility, emaciation and diarrhea ending fatally. Studies on the morphology reveal a great deal of vital characteristics which help in the adaptability of the parasite in the host. Morphology of the parasite has been studied under Scanning Electron Microscopy (SEM) in the present study. The adults show sexual dimorphism. The male *S.spindale* was shorter, coiled and stouter. The female *S.spindale* was long and slender. The tegument was found to be rough. There is bisexual pairing of adult worms. Few females were seen in the gynaecophoric canal of the males. Spines were found in the gynaecophoric canal. Spines arranged in a circular manner were also found in the oral sucker and ventral sucker. The wealth of information of the sanguinivorous worm, *S.spindale* in the present study would prove a vital force in the study of the ultrastructure of the parasite.

Keywords: *Schistosoma spindale*, Gynaecophoric canal, sanguinivorous worm, Schistosomiasis, eosinophilia.

I. INTRODUCTION

Schistosomes show morphological and physiological peculiarities which makes them apart from all other trematodes. The adults worms are adapted to the life within the blood vessels. The male is actually flat but has the sides of the body rolled ventrally to form a gynaecophoric canal bearing the long narrow body of the female. In mammals, the portal system carries intestinal break-down products from the duodenum, is rich in glucose and aminoacids, so that together with the plasma and blood cells, it represents an environment satisfying the metabolic demands of an egg-producing trematode. The number of species of schistosomes which grow and reproduced is clear by the efficiency in adapting themselves in blood. The blood of livestock is one of the most favoured habitats harbouring a wide range of parasites. It undergoes rapid and continuous chemical physiological and physical changes associated with energy absorption and exhibits negligible and very low terminal oxygen content. Blood provides a comprehensive nutrient resource for parasites. The pathology of experimental *S. spindale* infection buffaloes was studied by Fairley and Jasudasan(2). They insisted that buffaloes would constitute the main host of this schistosome under natural conditions. In this host the schistosomes were present in the portal and mesenteric veins and their eggs could be demonstrated in the large and small intestines. Schistosomes merits more detailed investigation than those carried out so far. The present study is an attempt to know the morphology of *S.spindale* through Scanning Electron Microscopic work(SEM).

II. MATERIALS AND METHODS

- 1) *Collection of parasites:* The intestine of buffalo infected with *S.spindale* were collected from the local slaughter house in Hyderabad. Mesenteric portal veins were observed and localization of the parasites in blood vessel of the intestines was done. The parasites were collected by dissecting and then with the help of needle and brush.
- 2) *Light Microscopy:* The morphology was studied by flattening between two slides and fixed in 4 % formalin for 24 hours. These worms were used for morphological studies after staining them using stains like Borax Carmine and Haematoxylin Eosin stain.
- 3) *Scanning Electron Microscopy:* (SEM) Male and female *S. spindale* were obtained from the mesenteric veins of naturally infected *B. bubalis* in Hyderabad, India. The parasites were fixed in 2.5% Gluteraldehyde in 0.05M phosphate buffer (pH 7.2) for 24 hr at 4^oC and post fixed 2% aqueous Osmium tetroxide in the same buffer for alcohol and processed for 2 hr. After the post fixation samples were dehydrated in series of graded alcohol and processed for critical point drying with Electron Microscopy Science CPD Unit. The dried samples were mounted over the stubs. Finally, applied a thin layer of platinum metal over the sample using an automated sputter coater (JEOL JFC-1600) for 5 min. Then samples were observed and scanned in SEM (JOEL-JSM 5600) at various magnifications. SEM studies were carried as per the principles and techniques described by John and Lonne (3).

III. RESULTS

- 1) *Under Light Microscope* adult *S. spindale* is seen coiled with smooth tegument (Fig.1A,1B, 1C). The male is seen coiled (Fig.1B,1C). The female is seen as a long thread like shape. (Fig. 1A). The female is seen in the gynaecophoric canal of the male. (Fig.1B). A subterminal and obliquely placed oral sucker is seen (Fig.1C, 1G) Ventral sucker is seen as pedunculated and cup shaped (Fig.1C,1G). The posterior end gets bluntly. (Fig 1F,1G) The characteristic spindale shaped egg of *S. spindale* having terminal spine seen under light microscope (Fig 1E, 1F).
- 2) *Under SEM Studies* the male and female *S. spindale* were observed. The following features of the morphology of *S. spindale* were quite evident.
 - a) *Tegument*: The tegument of *S. spindale* is rough and devoid of spines (Fig.2B,2E)
 - b) *Anterior End*: The anterior end of *S. spindale* consists of Oral sucker and Ventral sucker (Fig.2A,2B).
 - i) *Oral Sucker*: The oral sucker is subterminal having circular layers of spines in the oral sucker (Fig.2B,2C, 2D). The surface of the oral sucker was completely covered with numerous blunt spines directed inwardly.
 - ii) *Ventral Sucker*: The ventral sucker is pedunculated and has circular layers of ridges and spines (Fig.2G, 2H).
 - c) *Gynaecophoric Canal*: The gynaecophoric canal shows female in the male. Many spines were seen in the gynaecophoric canal. (Fig 2 A, 2E)..

IV. DISCUSSION

In the present study, the female is seen in the gynaecophoric canal of the male. Numerous spines are seen in the gynaecophoric canal when seen through SEM. The spines on the gynaecophoric canal can be substantiated by the fact that spines provide considerable friction to the female residing in the gynaecophoric canal of the male. The male and female *S. spindale* shows smooth tegument when seen under light microscope. But the tegument when seen under higher magnification through SEM shows a rough texture devoid of spines. The SEM studies on *S. spindale*, Jabalpur, India was done by Gupta and Aggrawal and they found the tegumental surface to be non-tuberculated, (4). The body surface of the male appeared to be uniform from anterior to posterior end. (5). The results of the present study correlates with the studies made by Gupta and Aggrawal (2002) and by Kruatrachue (1983).

The well-defined oral sucker and ventral sucker was seen through light microscopy. Further fine spines on the oral sucker and the ventral sucker were seen under higher magnification. The spines in the suckers would be for the considerable resistance of the parasite with reference to current of the blood flowing and to adhere against the walls of the blood vessels. These suckers provide a major inlet of food to the parasite sucking blood. The oral sucker is surrounded by an aspinose muscular wall (6). The present study is in agreement with the studies made by Narain and Mahanta (1999).

V. CONCLUSION

It is only through the researcher and the challenge to study the parasite, the panic of the outbreak of disease hanging over the cattle or buffalos can be solved. The present studies on the parasite, *S. spindale* have been carried out by the author to fill the existing lacuna on the morphological studies on the parasite. The morphological studies through Scanning Electron Microscopy have immensely helped to know the ultrastructure of *S. spindale*. Hepato-intestinal Schistosomiasis is by far the most common and widespread form of the disease encountered in almost all the species of domesticated animals, including man and many different schistosome species are involved. Thus an in-depth study of *S. spindale* would enable further for knowing the morphological parameters of the parasite. The work carried out in the present study would help in knowing the host parasite relationship. The adaptability of the parasite in the host is directly related to the morphological aspects of the parasite.

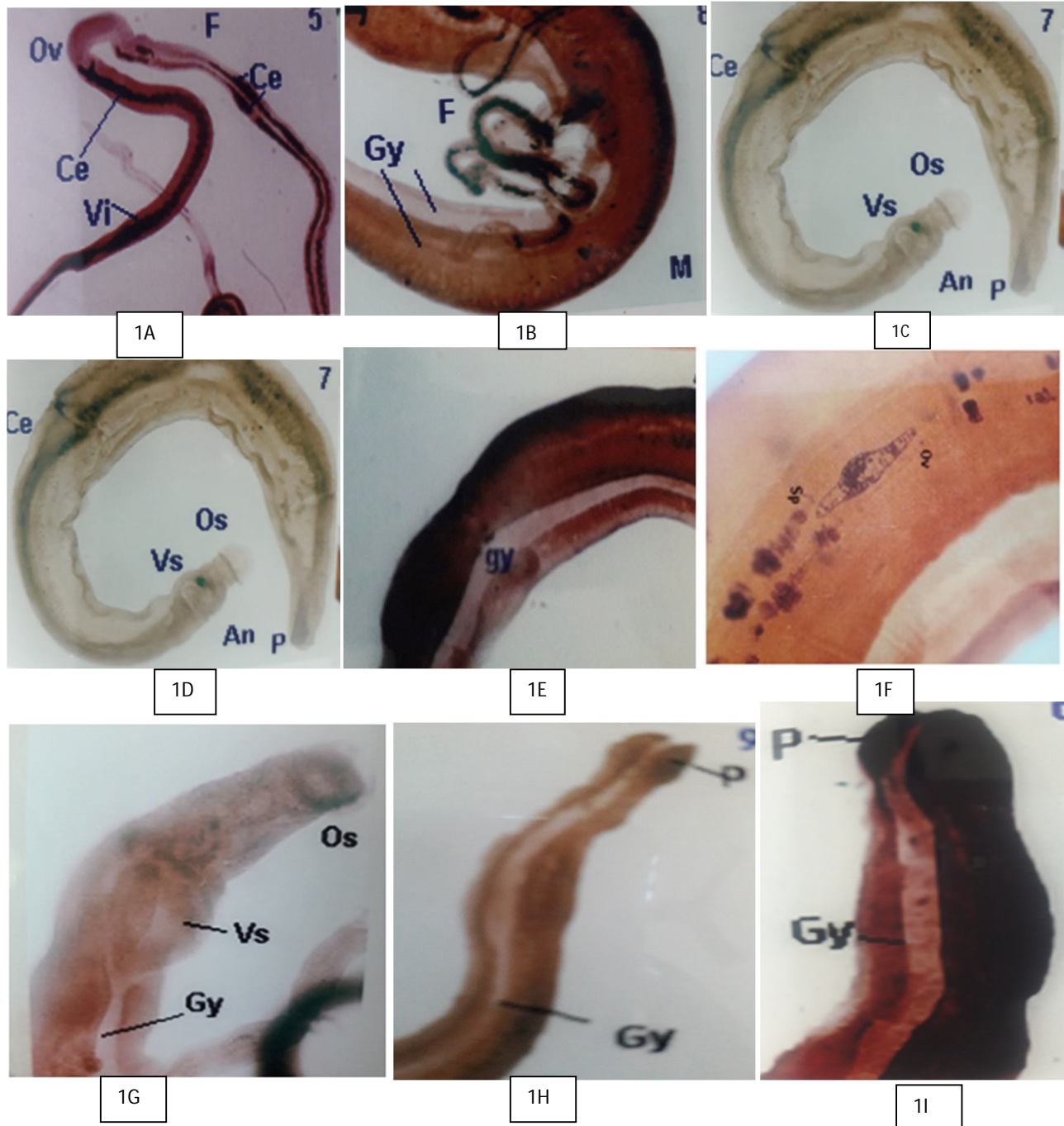
VI. ACKNOWLEDGMENT

We are extremely grateful to Vivek Vardhini Educational Society, Jambagh, Koti for rendering the laboratory facilities for the Research work undertaken. We are also grateful to Ruska Laboratory, ANGRAU campus, Rajendranagar, Hyderabad, for the Scanning Electron microscopy work.

REFERENCES

- [1] JOHN BOZZOLA and D.LONNIE RUSSELL (1999). Electron Microscopy Principles Techniques for Biologists 2nd edition. Southern Illinois University, Carbondale, Illinois.
- [2] S. S. SUMANTH, P.E SOUZA and M.S JAGANNATH. (2004). A study of the nasal and intestinal schistosomiasis in cattle slaughtered at an abattoir in Bangalore South India. Revista Science Technology, 23:937-942.
- [3] N.H. FAIRLEY and F. JASUDASAN (1927). The experimental transmission of *Schistosoma spindalis* to the Indian water buffalo. Indian Journal of Medical Research, 14:701-712.

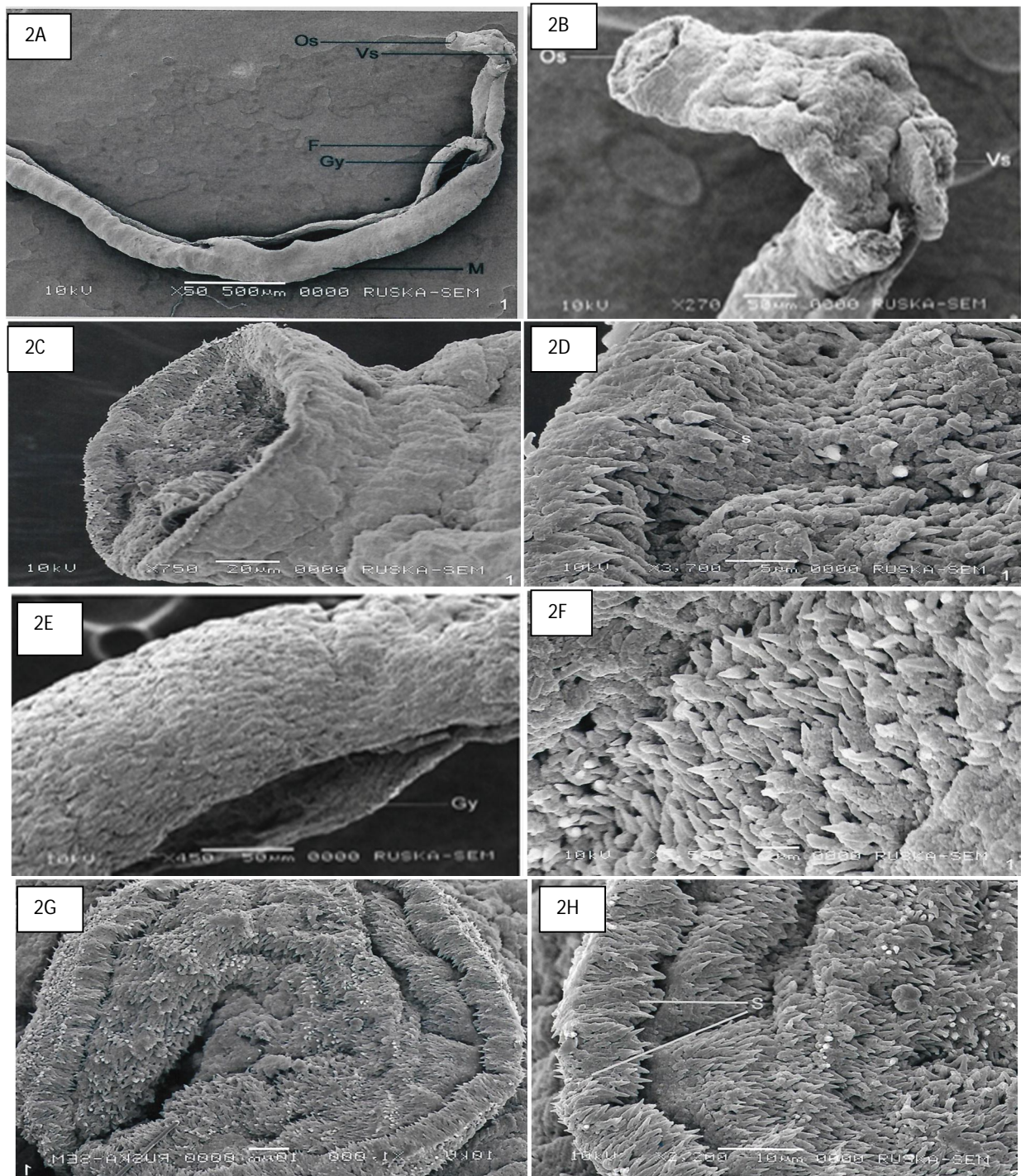
- [4] M. KRUATRACHUE, S. RIEGROJPITAK, E. S. UPATHAM and S. SAHAPHONG(1983). Scanning electron microscopy of tegumental surface of adult *Schistosoma spindale*. South East Asian Journal Tropical Med. Public Health, 14(3): 281-9.
- [5] S.GUPTA and M.C AGRAWAL(2002). Comparative scanning electron microscopy of some Indian schistosomes. Journal of parasitology and Applied Biology, 11: 49-54.
- [6] NARAIN and J. MAHANTA(1999). Scanning electron microscopy of the integumental surface of *Schistosoma spindale* isolated during an outbreak of cercarial dermatitis in Assam.. Journal of Veterinary Parasitology, 13(2):103-106.



A. Morphological Characteristics Of *Schistosoma spindale* Seen Under Light Microscope

Fig 1A. Female *S. spindale* Fig.1B. Female in the gynaecophoric canal of the male. Fig.1C. Male *S.spindale*. Fig. 1D. Gynaecophoric canal. Fig.1E. The Gynaecophoric canal showing female having ovum. Fig.1F. Ovum of *S. spindale*. Fig.1G. Anterior end of male *S.spindale* showing oral sucker and ventral sucker. Fig.1H Posterior end of male *S spindale*. Fig 1I. Posterior end of male *S.*

spindale(F-Female, M-Male, An-Anterior end,P-Posterior end, Gy-Gynaecophoric canal,Ov- Ovum,Ce-Caeca,Os-Oral Sucker, Vs-Ventral Sucker,Vi-Vitellaria, Mi-Miracidia)



B. Scanning Electron Microscopic Photographs Of Schistosoma Spindale

Fig. 2A. Female *S. spindale* lying in the gynaecophoric canal of male. $\times 50$. Fig. 2B. The anterior end of the male *S. spindale* showing oral sucker and ventral sucker $\times 270$. Fig. 2C. Oral Sucker of the male *S. spindale* $\times 750$. Fig. 2D. Oral Sucker of male *S. spindale* showing spines. $\times 3700$. Fig. 2E. The Gynaecophoric canal of the male *S. spindale* $\times 450$. Fig. 2F Gynaecophoric canal showing spines $\times 5500$. Fig 2G. Ventral Sucker of the male *S. spindale* $\times 1000$. Fig 2H. Ventral Sucker of male *S. spindale* showing spines $\times 2200$.



10.22214/IJRASET



45.98



IMPACT FACTOR:
7.129



IMPACT FACTOR:
7.429



INTERNATIONAL JOURNAL FOR RESEARCH

IN APPLIED SCIENCE & ENGINEERING TECHNOLOGY

Call : 08813907089  (24*7 Support on Whatsapp)