



IJRASET

International Journal For Research in
Applied Science and Engineering Technology



INTERNATIONAL JOURNAL FOR RESEARCH

IN APPLIED SCIENCE & ENGINEERING TECHNOLOGY

Volume: 6

Issue: II

Month of publication: February 2018

DOI:

www.ijraset.com

Call:  08813907089

E-mail ID: ijraset@gmail.com

Histological Study on Gills and Liver of Fresh water Fish *Rasbora dandia* Exposed to Sodium Lauryl Sulfate (SLS)

Jeen Jose P¹, Midhu K Johnson², Parvathy C A³

¹Department of Zoology, Vimala College, Thrissur

²Department of Physiology, Prajothi Nikethan College, Pudukkadu

³Research and Postgraduate department of Zoology, St. Thomas College, Thrissur.

Abstract: *The histological effects of Sodium Lauryl Sulfate (SLS) on the gill and liver tissues of the Rasboradandia were studied. The fish were exposed to two sublethal concentrations of anionic detergent, Sodium lauryl sulfate (SLS) with the observation of 120 hrs, 240 hrs, and 360 hrs. The 96 hr LC50 for Sodium Lauryl Sulphate(SLS) was estimated 4 mg/L. Gill and liver samples were collected after 120hrs of exposure to SLS and histological slides were created and analyzed. Even at small SLS concentrations Rasbora stressed and showed erratic swimming and struggle hard for breathing. The histological changes to gills were edema, fusion of lamellae and lamellar aneurism. In the liver tissue, hepatocyte degeneration, congestion and dilation of sinusoid and vacuolar degeneration were seen. The 120 hrs exposure with 1.5 mg/L SLS showed the dilation and congestion in the blood vessels of primary gill lamellae and epithelial detachment were observed. Curling of secondary lamellae was also observed and some of the hepatic cells showed degeneration. The 360 hrs exposure with 3 mg/L SLS marked epithelial detachment, epithelial hyperplasia, degeneration of secondary lamellae and atrophy and aggregation and necrosis of the hepatocytes was observed some of the hepatocytes ruptured leading to d enucleated cell. The tissue damages and histological changes increased with the increase of SLS concentration and exposed period. It seems that sublethal concentration of LAS may affect sever changes to gill and liver of Rasboradandia specimens that leads to malfunction of these organs which cause severe damage to health of the fish.*

Keywords: *Sodium Lauryl Sulfate (SLS), Histology, Gill, Liver Cells, Rasbora dandia, Necrosis.*

I. INTRODUCTION

Water, provide very important medium for all life and considered as one of the nature's most preatious gifts to mankind. Earth contains only 2.5% of fresh water. Majority of water is in sea, as ice and very few amount of water is found in rivers, lakes, atmosphere and biological bodies. Water is pivotal in day to day life. In human beings 70% of body weight is from water and also form a very crucial role in all forms of biological activities and also water contribute enormous purposes like drinking, for watering livestock, food production, fisheries, industries and even for recreational activities. Today one of the major environmental problem facing mankind is the unavailability of pure water. Rain water become decreased and even available fresh water going polluted by the activities like urbanization, industrialization and human apathy have all contributed to water pollution emerged as an "ecological disaster". The wide array of pollutants discharged into the aquatic environment may have physico-chemical, biological, toxic and pathogenic effects [19]. The fast diminishing of water pure water emerges the increasing concern for deteriorating availability of water, but there is no use by concern, the solution must be taken for consideration and for working. Good quality drinking water ensure the good health and physiological conditions, all biological life continued existence depends on its availability. Waste water is polluted water, loss of beneficial nature due to the mixing of harmful and unwanted chemical and biological materials in to it. Water pollution occurs when fresh water resources become unconcern about discharge of industrial effluents without proper treatment to remove harmful materials from it, the water become no long suitable for drinking, cooking and bathing due to the hazardous chemical compounds present in it. This polluted water being taken up by all organisms and cause deleterious to the entire populations of organisms and even to the individual species. Detergents contribute a important role in water pollution. detergents has very harmful effect on the biological diversity. Today detergent used for making soaps and other materials used in daily life. This detergents from the human uses discharged continuously into the water resources and become polluted. Detergents are the chemical compounds or organic compounds composed of fatty acids and various compound like Alkyl Benzene Sulphonates, Polyphosphates, Cellulose, Succinic acid, Sodium lauryl sulphate. Detergents are of three types: anionic, cationic and

non-ionic detergents with polar and non polar nature. Anionic and cationic detergents have permanent negative or positive charges, attached to non-polar (hydrophobic) C-C chains. Non-ionic detergents have no such permanent charge; instead, they have a number of atoms which are weakly electropositive and electronegative [61]. Detergents are of two kinds: phosphate detergents and surfactant detergents, former are caustic and used to soften hard water and suspend the dirt in water and later are used to enhance the wetting, foaming, dispersing and emulsifying properties of detergents and are very low. Detergents are not fully degraded by sewage treatment and also they are again discharged into the water bodies, cause very harmful effect on the biodiversity, health and environment. Surfactants have high biological activity even at low concentrations and also have the power to accumulate in the organisms. Several types of surfactants such as soaps (anionic), Alkyl benzene sulphonate (ABS), Sodium lauryl sulfate (SLS) (anionic) and Ethoxylated fatty alcohols (non-ionic) are used to make detergents. Sodium Lauryl Sulfate (SLS) is an anionic surfactant detergent derived from Alcohol Sulfates and it is also known as Sodium Dodecyl Sulfate (SDS). SLS is widely used in household products such as, toothpastes, shampoos, shaving foams, bubble baths, and cosmetics. It is used as leather softening agent, wool cleaning agent, in paper industry as penetrant and flocculating agent, in construction as additive of concrete, and as ingredient of floor cleaners and car wash soaps. The presence of SLS in environment arises mainly from its presence in complex domestic and industrial effluents as well as its release directly from some applications (e.g., oil dispersants and pesticides). It has been reported that SLS is toxic and affects survival of aquatic animals such as fishes, microbes like yeasts and bacteria. It is also toxic to mammals like mice and humans but to a lesser extent [15]. The use of biota as an indicator of pollution is advantageous over chemical analysis as they are ecologically realistic [38]. Due to their widespread use, there has been an increasing concern about the environmental behaviour of these compounds. Faunal and chemical monitoring has frequently been used to assess environmental quality [30]. The use of biota as an indicator of pollution is advantageous over chemical analysis as they are ecologically realistic [38]. Fishes are quite susceptible to detergents and their continuous exposure may reduce the resistance of fish against parasitic infections. When detergents enter the fresh water ecosystem even somewhat beyond its minimum limit, they have toxic effect on the aquatic life. These detergents cause injuries to the skin, outer protective mucus coats and to the respiratory organs (gills). It will kill the eggs and developing embryos at low concentration. These contaminated fishes are not good for human ingestion. Many workers have studied toxicity of detergents and biochemical contents in fishes. Histopathological changes have been widely used as biomarkers in the evaluation of the health of fish exposed to contaminants [55]. The exposure of fish to chemical contaminants is likely to induce a number of lesions in body organs like gill, liver and kidney. These organs are suitable for histological examination in order to determine the effect of extent of pollution. Gill exhibits large surface area, which is subjected to direct and permanent contact with pollutants. Liver plays a key role in metabolism and subsequent excretion of xenobiotics and is also the site of vitellogenin production. Kidney is important in the maintenance of a stable internal environment and is partially involved in the metabolism of xenobiotics.

Histopathological analysis yields data on a number of organ systems and permits localization of lesion with specific cell types. With a thorough prior knowledge of normal anatomy, the investigator can use histological analysis to detect alterations in tissues and organs caused by exposure to toxicants. When concentration of a toxicant is sufficient to result only in cellular injury and not death, sub-lethal changes can be observed in affected cells. On the other hand, death of cells followed by a series of cellular reactions occurs without death of the organism. One of the great advantages of using histopathological biomarkers in environmental monitoring is that this category of biomarkers allows examining these specific target organs [18]. Furthermore, the pathological changes discovered in these organs are normally easier to identify than functional ones [14], and serve as warning signs of damage to animal health [22]. For the reasons already mentioned, the present investigation was carried out to evaluate and compare the acute toxicity of sublethal concentrations of anionic surfactant SLS on the gill and liver of the *Rasbora dandia*. In the present study, *Rasbora dandia* was selected because it serves as an important biological indicator of water quality and they are most commonly and abundantly found in the river. This study is very influential now a day, as domestic utilization of detergents is polluting our fresh water ecosystem.

II. MATERIALS AND METHODS

A. Test Animal

Rasbora dandia was chosen as the test animal for the study as they are most commonly and abundantly found in the fresh water wetlands such as rivers, streams and koles, and they are much tolerant to physical and chemical changes. The effect of detergents on *Rasbora* shows the potential hazards and toxicity on all biodiversity.

Rasbora dandia

Phylum : Chordata
Class : Actinopterygii
Order : Cypriniformes
Family : Cyprinidae

Common /local names: English; Slender rasbora or Blacklinerasbora. Kerala; Kokanutchee, thuppalkuthi. The name *R. Dandia* is revived for the Sri Lankan and southern Indian species previously assigned to *R. daniconius*. Distribution: Bangladesh, India, Myanmar, Pakistan, Makong and Sri Lanka.

Morphology: Body elongated, oblong, compressed with small mouth. Barbles absent. Lateral line complete descending gradually with 21-34 scales. Body olive dorsally with silvery flanks and belly. A prominent black stripe from eye to the base of caudal fin, delicately edged by a thin metallic golden line. *Rasbora dandia* differs from *R. daniconius* by having a complete lateral line on the body. Habitat: Pools, ditches streams, ponds canals and rivers. Feeding Habits: Surface dwellers; feeds on algae, aquatic insects, protozoans, mud and sand [48].

B. Research Method

About 80 -100g sized fishes were collected from Thrissur, Kerala. They were brought to the laboratory, acclimatized in tap water for about one week, prior to the experiment, fed daily ones with fish pellets. The tanks were observed 1-2 times a day, and the excreta and waste materials accumulated were removed.

C. Determination of LC50

The 96 hr LC50 was determined by adding different concentration of Sodium lauryl sulphate (SLS) to water. Mortality rate during 24, 48, 72 and 96 hr after the exposure period was recorded. To calculate lethal concentration, fishes were exposed to 2,4,6,8 and 10 mg/l of SLS containing water. Fishes with almost 80 to 100g weight were selected and 10 fishes were kept in each tub containing 20L of dechlorinated water. Preliminary experiments were conducted to choose the concentration that result in the 50% mortality at 96 hours exposure period. The fishes were observed regularly and the number of death in all the tub were recorded daily for a period of 96 hours. The number of dead organism in each of the test series was recorded. From this reading, 96 hours LC₅₀ concentration of SLS was found out.

D. Experimental Design

Three tubs were taken and filled with 10 L of tap water, in which one was noted as control and other two of them as tub 1 and tub 2. The day on which the experiment was started is noted as the '0th' day. The two of the experiment tubs were treated with concentrations of 1.5 and 3mg of SLS per liter. Surfactant was not added to control. After 15 minutes of stabilization 10 fishes were exposed to each tub. The fishes were fed once daily. The tub was refilled with water every day and care was taken not to change concentrations. The exposure period was 15 days.

E. Histological Analysis

Two specimens from each treated and control groups were sacrificed and organs such as gill and liver were dissected out. Tissues were fixed in Bouin's fixative for 24 hours. The tissues are cut into small pieces (5 µm) and washed repeatedly in 70% alcohol and further dehydrated in graded alcohol in ascending order, cleared in xylene and finally embedded in paraffin then 4-6µ thick sections were cut. These sections were stained with haematoxylin and eosin [11]. Light microscopy was performed and stained section was photographed.

III. RESULTS AND DISCUSSION

A. Treated

The 96hr LC50 for Sodium Lauryl Sulphate (SLS) was estimated 4 mg/L. In the present study, when *Rasbora dandia* was exposed to SLS treatment in sub-lethal concentrations of 1.5 and 3 mg/L, have induced marked histological changes in the fish gill and liver

B. Morphological and Behavioral Observations

Behavior's the recordable and observable activity of living organisms. When experimental fishes were introduced into water containing 1.5 mg/L concentration of SLS, they began to move around rapidly, with increased concentration of the SLS at 3mg/l, showed erratic swimming and struggle hard for breathing.

C. Histological effects

- 1) **Gill (Control)** :In the control fish the gill showed the arrangement of primary and secondary lamellar processes. The primary gill lamellae (PL)were flat leaf like structures with a central rod like supporting axis and a row of secondary gill lamellae on each side of it. The secondary lamellae (SL) were equally spaced along the columnar structures with intact cellular layer attached at their bases with the primary lamellae and free at their distal ends. The normal secondary lamellar epithelium was simple, consisting of a thin single or double sheet of epithelial cells, blood vessels and a row of pilaster cells. The blood vessel extends to the secondary lamellae. The region between the two adjacent secondary lamellae was interlamellar region. Between the secondary lamellae, the primary lamellae are lined by a thick stratified epithelium. This region contains numerous mucous and chloride cells. The gills are finger like filaments, made up of two rows and are attached to the opposite sides of the Inter branchialseptum. The control tissue taken on the 5th, 10th and 15th day showed the similar structure as below (Fig. I).
- 2) **Liver (Control)** :The liver of control Rasbora dandia was composed of parenchymal cells (hepatocytes) arranged in a typical tubular sinusoid pattern, the liver cords were characteristically two cells thick and alternated with sinusoids. The hepatocytes were morphologically polygonal and vacuolated. The nuclei were spherical in shape and uniform in size. The blood vessels with red blood cells were found in good condition (Fig.II).
- 3) **Experiment I, Rasbora exposed at 1.5 mg/l SLS.**: Gill: On the 5th day of exposure there was dilation and congestion in the blood vessels of primary gill lamellae observed in gill filament.On the 10th day of exposure were observed dilation and congestion in the blood vessels of primary gill lamellae and epithelial detachment. On the 15th day of exposure dilation and congestion in the blood vessels of primary gill lamellae and epithelial detachment were observed. Curling of secondary lamellae was also observed. Liver: On the 5th day of exposure the hepatocytes had lost their polygonal shape and hence the gaps between the cells increased. On the 10th day of exposure slight degeneration and aggregation of the hepatocytes and dilated sinusoids were noted. On the 15th day of exposure some of the hepatic cells showed degeneration and vascular degeneration was also observed.
- 4) **Experiment II: Rasbora exposed at 3 mg/l SLS:** GillOn the 5th day of exposure there were observed dilation and congestion in the blood vessels of primary gill lamella and epithelial detachment. On the 10th day of exposure aneurism and epithelial hyperplasia in the gills were observed. On the 15th day of exposure the gill tissue showed epithelial detachment, epithelial hyperplasia, degeneration of secondary lamellae and atrophy. Liver: On the 5th day of exposure loss of the shape of the hepatocytes and dilated sinusoids were observed. On the 10th day of exposure the cell membrane underwent lysis and dilated sinusoids were exposed. Aggregation of hepatocytes was observed. On the 15thday of exposure aggregation and necrosis of the hepatocytes was observed some of the hepatocytes ruptured leading to denucleated cell.

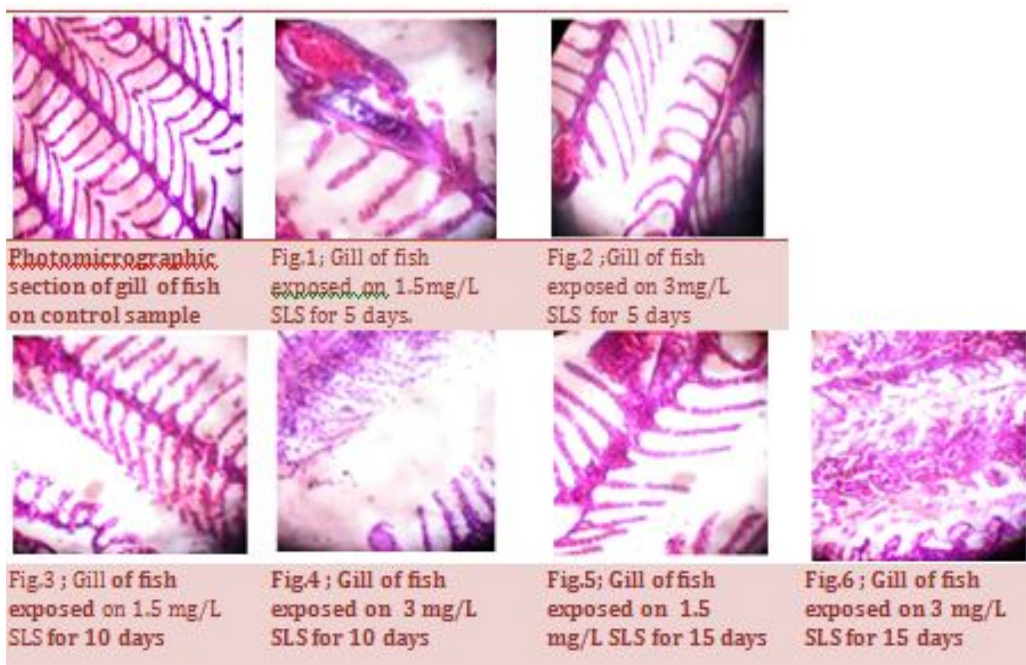


Fig. I: Photomicro graphic sections of Gills of Rasbora with different SLS concentrations and exposure periods.

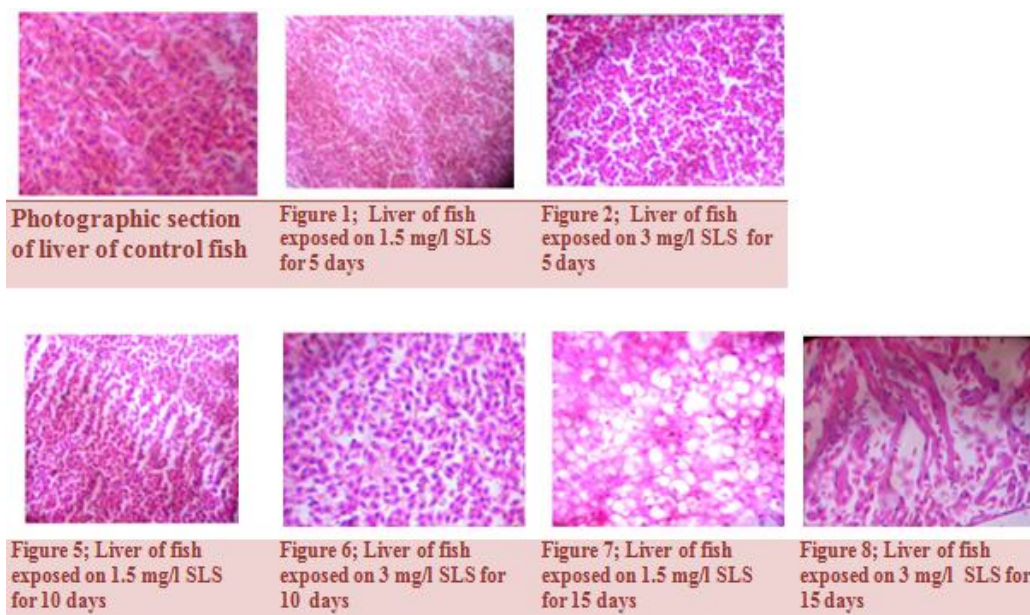


Fig. II: Photo micrographic sections of Liver of Rasbora with different SLS concentrations and exposure periods.

Aquaculture sector is contributing to a great extent towards the protein requirement of man. As fish is considered the most important and vital link in the food chain of the ecosystem and the inland fisheries are an important source of protein in a nation's diet, a thorough understanding of the toxicant's effect on fishes would be really vital for fish conservation and fisheries development [2]. Fishes are known to bio accumulate, bio concentrate and bio magnify toxicants in their tissue and are widely used as bio indicators for pollution in marine and freshwater environment [9]. The contamination of fresh waters with a wide range of pollutants has become a matter of concern over the last few decades [8]. Histology is useful technique for investigating the toxic effect of pollutants. Such a study also offers opportunity to locate the effect of pollutants in various organs and systems of animals. This type of study in fish has been to a great extent is handicapped because of the lack of adequate histological literature concerning various fish organs [25]. Considerable interest has been shown in recent years in histopathological studies while conducting environmental toxicity tests in fish. In the present study, when fishes were introduced to water containing different sub-lethal concentration of SLS they moved around rapidly. As the concentration of detergent increased fish's distress increased.

The gills, which participate in many important functions in fish, such as respiration, osmo regulation and excretion, remain in close contact with the external environment, and particularly sensitive to changes in the quality of the water, are considered the primary target of the contaminants. Fish gill is very sensitive to changes in the composition of the environment and is an important indicator of detergent effect. Consequently, injury to gill epithelium is a common response observed in fish exposed to a variety of contaminants. The severity of damage to the gills depends on the concentration of the toxicant and the period of exposure.

Rasbora dandia which are exposed to sub lethal concentrations of SLS exhibited pathological lesions in the gill. Maximum severity of histological changes was noticed in gills of fishes exposed to higher concentration and longer durations of SLS. The changes observed due to the exposure of SLS are dilation and congestion in the blood vessels of primary gill lamellae, Epithelial detachments, aneurism, curling of secondary lamellae, degeneration of secondary lamellae, atrophy and epithelial hyperplasia.

The proliferative thickening of gill epithelium might be general safety measure against irritation by environmental toxicants [42]. The formation of an aneurysm is related to the rupture of the pillar cells due to a bigger flow of blood or even because of the direct effects of contaminants on these cells [31]. A commercial detergent "Ariel" at 5ppm was found to induce moderate degenerative changes in the respiratory lamellae in *Oreochromis mossambicus* on 2 days exposure and the chronic exposure led to drastic changes like separation of epithelium layer and atrophy [40]. Similar results were also found in the studies on fish *Sparus aurata*, where pronounced alteration in the filaments of individuals occurred when fishes were exposed to concentrations from 3 to 15mgL⁻¹ of SDS and LAS [52].

The liver is the primary organ for detoxification of organic xenobiotics. Hepatic cells have many vital functions. Hepatic cells not only secrete bile but also play an important role in carbohydrate, protein and lipid metabolism and serve as storage sites for some nutrients. In liver sections of normal fish, the hepatocytes form a rather cord-like pattern. The liver cells are large in size, polygonal

in shape with homogenous eosinophilic cytoplasm and centrally located nuclei. A large number of blood sinusoids separate the hepatic cords one from another. Lethal concentration of SLS induced obvious histological changes in the liver of *Rasbora dandia*. During the experiment, the liver of fish in the control group did not show any morphological changes in the structure whereas in experimental set ups the fishes showed the following morphological changes in the liver; loss of polygonal shape, vacuolization of hepatocytes, dilated sinusoids, degeneration of hepatic cells aggregation of hepatocytes, cell lysis, vacular degeneration, denucleated hepatocytes, and necrosis of hepatocytes. The changes were more in the liver of fishes incubated in water containing more SLS.

Several studies demonstrated that alterations in number, size and shape of the hepatocyte nucleus can be due to contaminants [36]. Congestion of sinusoid, shrinkage of hepatocytes, slight atrophy and vacuolar degeneration have been reported in liver of fishes after chronic exposure to LAS [22]. The hepatic necrosis are described as irreversible injury to tissue [3]. Necrosis was also reported in liver of Brazilian tropical and subtropical fish species exposed to multiple contaminants in different impacted regions [36]. Some morphological changes in gills and liver may represent adaptive strategies to maintaining physiological functions, but the histopathological changes as described in the present study indicated that fishes were affected by the exposure to SLS presented in water [62].

IV. CONCLUSION

It can be concluded that the SLS had a severe impact on the experimental fish *Rasbora dandia* (Hamilton, 1822). The findings of the present histological investigations demonstrate that the exposure of freshwater fish, *R. dandia* to SLS concentrated water caused moderate to severe damages to the gills and liver, with increase in concentration of the SLS increased altered changes in the structures of their gills and liver. Hence, the environmental awareness becomes more necessary, since fish forms delicious component of human food and further it is poor man's dish, it may be concluded that the surfactant pollution presently evaluated cause lethal effects found in the surrounding area whether terrestrial or aquatic. People need to be made aware of the adverse causalities of detergents on various forms of aquatic life. Sewage water generated from households should not be allowed to be discharged directly into the water bodies. Better sewage treatment facilities have to be looked into for the protection of these water bodies.

V. ACKNOWLEDGMENT

The authors are thankful to the Principal and Head Department of Zoology, Vimala College, Thrissur for giving permission to conduct the basic survey work and using the laboratory.

REFERENCES

- [1] Abel P. D. (1974). Toxicity of synthetic detergents to fish and Aquatic Invertebrates. *Fish Biology*, 279-298.
- [2] Agnihotri, N. & Chattopadhyay, S. (1992). Pollution hazards through agrochemicals, soil fertility and fertilizer use. *Indian Farmers Co-Operative Ltd. N.D.* 5:157- 174.
- [3] Bernet, D., Schmidt, H., Meier, W., Burkhardt-Holm, P. And Wahli, T. (1999). Histopathology in fish: Proposal for a protocol to assess aquatic pollution. *J. Fish Dis.*, 22: 25-34.
- [4] M. Brown, V. V. Mitrovic, G. T.C. Stark. (1968). Effects of chronic exposure to zinc on toxicity of a mixture of detergent and Zinc. *Water research Volume 2, Issue 4, June, Pages 255-260, In3-In4, 261-263.*
- [5] Brunelli E, Talarico E, Corapi B, Perrotta I, Tripepi S. (2007). Effectsof a sublethal concentration of sodium lauryl sulphate on the morphology and Na⁺/K⁺-ATPase Activity In The Gill Of The Ornate Wrasse (*ThalassomaPavo*). *Ecotoxicol Environ Saf.* 2008 Oct; 71(2):436-45. Epub 2007 Nov 19.
- [6] Byrne P, Speare O And Ferguson H. W. (1989). Effects Of A Cationic Detergent On The Gills And Blood Chemistry Of Rainbow Trout. *Dis Aquat Org.* 6, 185-196.
- [7] Camargo, M. M. P. And Martinez, C. B. R. (2007). Histopathology of gills, kidney and liver of a neotropical fish caged in an Urban stream. *Neotropical Ichthyology*, 5(3):327-336.
- [8] Canli M., Ay, O & Kalay, M. (1998). Levels of heavy metals (Cd, Pb, Cu, and Ni) in tissue of *Cyprinus carpio*, *Barbus carpio* and *Chondrostomaregium* from the Seyhanriver. *Turk. J. Zool.* 22(3):149-157.
- [9] Casini, S., Corsdini, S., Focardi, S. & Mettai. (1995). Biomarkers and organ Chlorine levels in specimens of *Zostersessor*, *Ophiocephalus* from the Lagoon of Venice as a tool for evaluating the water quality. *S. It. E. Proc.* 16: 61 - 63.
- [10] Chandanshive Navnath Eknath (2013). Studies on toxicity of detergents to *Mystus montanus* and change in behaviour of fish. *Research journal of animal, veterinary and fishery sciences*, Vol. 1(9), 14-19.
- [11] Culling C F A. (1974). *Handbook of histopathological and histochemical techniques*. Third Edition.
- [12] Dirilgen, N. (2001). Accumulation of heavy metals in freshwater organisms: Assessment of toxic interactions. *Turk. J. Chem.* 25(3):173-179.
- [13] Emi Mathew¹, Sunitha P. T. 2, Philip Litto Thomas. (2013). Effect of different concentrations of detergent on dissolved oxygen consumption in *Anabas Testudineus*. *Iosr Journal Of Environmental Science, Toxicology And Food Technology (Iosr-Jestft)*. E-Issn: 2319-2402, P-Issn: 2319-2399. Volume 5, Issue 3 (Jul. - Aug. 2013).

- [14] Fanta, E., Rios, F. S., Romão, S., Vianna, A. C.C. And Freiberger, S.(2003). Histopathologyof the fish *CorydorasPaleatus*contaminatedwith sublethal levels of organophosphorus inwater and food. *Ecotoxicology And Environmental Safety*, 54, 119-130.
- [15] N. J. Fendinger, D. J. Versteeg, E. Weeg, S. Dyer And R. A. Rapaport. (1994). Environmental behavior and fate of anionic surfactants. In: *Environmental Chemistry Of Lakes And Reservoirs*, (Ed. L. A Baker). American Chemical Society, Washington. Dc, Usa: 527-557.
- [16] Figueiredo-Fernandes, A., Ferreira-Cardoso, J.V., Garcia-Santos, S., Monteiro, S.M.,Carrola, J., Matos, P. and Fontafnhasfernandes, A. (2007). Histopathologicalchanges in liver and gill epithelium of ofnile tilapia, *OreochromisNiloticus*, exposed to water borne copper. *Pesq. Vet. Bras.*,27 (3) :103-109.
- [17] GargTkAnd Mittal Ak (1993). Observations on the functions of mucus cells in the epidermis of the cat fish *ClariasBatrachuse*exposed to Sodium Dodecyl Suifate,*Biomed Environ Sci*, 6(2), 119-133.
- [18] Gernhofer, M., M. Pawet, M. Schramm, E. Müller & R. Triebkorn. (2001). Ultrastructural biomarkers as tools to characterize the health status of fish in contaminated streams. *Journal of Aquatic Ecosystem, Stress and Recovery*, 8: 241-260.
- [19] Goel P. K. (2000).*Water Pollution: causes, effects and control*. New age international publishers, Ltd, New Delhi.
- [20] Gonzales, G.,Crespo, S.&Brusle, J. (1993). Histo-cytological study of the liver of the Cabrillasea bass, *Serramuscabrilla*(Teleostei, Serramidae), Anavailable model for marine fish experimental studies. *J. Fish Biol.*, 43: 363-73.
- [21] Hamilton, B. (1822). An account of the fishes found in the river Gangas and its branches. Edinburgh (Reprinted 1981). P. 405.
- [22] Hampel, M., Ortiz-Delgado, J.B., Sarasquete, C. And Blasco, J.(2008). Effects of sedimentabsorbed linear alkylbenzenesulphonate onjuveniles of the senegal sole, *SoleaSenegalensis*: Toxicity and histologicalindicators. *Histology and histopathology*, 23,87-100.
- [23] Hara T. J And Thompson B. F. (1978). The Reaction of white fish (*CoregonusClupeaformisi*)To the anionic detergent Sodium Lauryl Sulfate and its effect on olfactory responses,*Wat Res*, 12, 893-897.
- [24] HazariLal, VirendraMisra, P. N. Viswanathan, And C. R. Krishna Murtibull. (1984). Effect of synthetic detergents on some of the behavioral patterns of fish fingerlings (*CirrhinaMrigala*) and its relation to ecotoxicology. *Environ. Contam. Toxicol.* 32:109-1159
- [25] Hinton, D.E., Lauren, D.J. &Gian, C.S. (1997). Cellular composition and ultrastructure of hepatic neoplasm's induced by Diethyl Notrosamine in *Oryziaslatipes*. *Mar. Environ. Res.* 24: 307-310.
- [26] Hrabak A, Antoni F And SzaboMt(1982). Damaging effects of detergents on human lymphocytes, *Bull Environ ContamToxicol*, 28, 504-511.
- [27] KicenuikJw, Penrose WrAnd Squires W. R. (1978). Oil spill dispersants cause bradycardia in a marine fish, *Mar Poll Bull*, Vol. 9(2).
- [28] Kirpatrick F. H, Gordesky Se And Marinetti G. V. (1974). Differential solubilisation of proteins, phospholipids and cholesterol of erythrocyte membranes bydetergents. *BiochimBiophysActa*, 345, 154-161.
- [29] Kumar M, Trivedi S.P, Misra A, Sharma S. (2005). Histopathologicalchanges in testis of the freshwater fish, *HeteropneustesFossilis* (Bloch) Exposed to linear Alkyl Benzene Sulphonate (Las). *J Environ Biol.* 2007 Jul; 28(3):679-84.
- [30] Martin M., and Richardson B.J.(1995). A paradigm for integrated marine toxicity research: Further views from the Pacific Rim. *Marine Pollution Bulletin.* 30, 8-13.
- [31] Martinez, C.B.R., Nagae, M.Y., Zaia, C.T.B.V. And Zaia, D.A.M. (2004). Morphological andphysiological acute effects of lead in the neotropical fish *ProchilodusLineatus*. *BrazilianJournal of Biology*, 64(4):797-807.
- [32] Miranda, A.L., Roche, H., Randi, M.A.F., Menezes, M.L. & Oliveira Ribeiro, C.A. (2008). Bioaccumulation of chlorinated pesticides and pcbs in the tropical freshwater fish *HopliasMalabaricus*: Histopathological, physiological, and immunological findings. *Environ. Int.*, 34(7): 939-949.
- [33] Naeemi A.; Jamili S.; Shabanipour N.; Mashinchian A. And ShariatiFeizabadi S. (2011). Histopathologicalchanges of gill, liver and kidney in caspiankutum exposed to linear alkylbenzenesulfonate.*Iranian Journal Of Fisheries Sciences* 12(4)887-897.
- [34] Ogundiran, M. A., Fawole, O. O., Adewoye, S. O. And Ayandiran, T.A. (2009). Toxicological impact of detergent effluent on juvenile of African Catfish (*Clariasgaripepinus*) (Buchell 1822). *Agric. Biol. J. N. Am.* 1: 330-342.
- [35] Olaniran N.S. (1995). Environment and health: an introduction, environment and health. Lagos. Micmillan Nig. Pub. Co for Ncf, 34-151.
- [36] Paris-Palacios, S., S. Biagiante-Risbourg & G. Vernet. (2000). Biochemical and (ultra)structural hepatic perturbations of *Brachydaniorerio* (Teleostei, Cyprinidae) exposed to two sub-lethal concentrations of CoperSulfate. *Aquatic Toxicology*, 50: 109-124.
- [37] Peebua, P., Kruatrachue, M., Pokethitiyook, P. And Singhakaew, S.(2008). Histopathologicalalterations of Nile tilapia, *Oreochromisniloticus* in acute and subchronicalachlor exposure. *Journal Of Environmental Biology.* 29 (3) : 325-331.
- [38] Pocklington P. And Wells P.G.(1992). Polychaetes: Key Taxa for marine environmental quality monitoring.*Marine Pollution Bull.* 24, 593-598.
- [39] Poleksic, V. and Mitrovic-Tutundzic, V.(1994).Fish gills as a monitor of sublethal and chroniceffects of pollution, Oxford, Fishing NewsBooks. pp.339 – 352.
- [40] Raju C S. Anilkumar D M H S, PrakasaBabu P AndJayanthaRao K. (1994). Effect of detergent (Ariel) on oxidative enzymes and histology of the teleost, *Oreochromismossambicus*, *J Ecotoxicol Environ Monit*, 4(4), 227-230.
- [41] Rejeki, S., Desrina, D. And Mulyana, A.R., 2008.Chronic affects of detergent surfactant (LinearAlkylbenzeneSulfonate / LAS) on the growth and survival rate of sea bass (*LatesCalcalifer* Bloch), *Larvae Journal of Coastal Development*.213p.
- [42] Roberts,T.R.(1989).Fresh water fishes of western borneo(Kalimantan baratindonesia), *Memoirs of california academy of science* 14.California Academy Of Sciences,Sanfrancisco, Ca.210pp
- [43] Rosety M, Ribelles A and Carrasco S. (1997). A morphological study in the kidney and spleen of gilt head, *Sparusaurata* L. caused by Sodium Dodecyl Suifate, *HistolHistopathol*, 12(4), 925-929.
- [44] L. M. Rosety-Rodríguez, F.J. Ordoñez, S. Roldan, J.M. Rosety, M. Rosety, A. Ribelles, C. Carrasco, and I. Rosety. (2001). Acute effects of Sodium Dodecyl Sulphate on the survival and on morpho-histochemical characteristics of the trunk kidney of juvenile turbot *Scophthalmusmaximus*. *Eur. J. Histochem.* 46: 179-184
- [45] Roy, D. (1988a). Toxicity of an anionic detergent, Dodecyl Benzene Sodium sulfonate to a freshwater fish, *Rita rita*. Determination of LC50 values by different methods. *Ecotoxicol. Environ. Saf.* 15: 186-194.
- [46] Roy D. (1988b). Statistical analysis of anionic detergent induced changes in the goblet mucous cells of opercular epidermis and gill epithelium of *Rita rita*(Ham.) (Bagridae: Pisces). *Ecotoxicol Environ Saf.* 15:260–271.

- [47] Dr.Sewa Ram Verma Assistant Prof, Dr. Mohan Research Scholar and Dr. R. C. Dalela.(1976). Studies on the relative toxicity of few synthetic detergents to a fish *Macronesvittatu*. *Actahydrochimica et hydrobiologica* .Volume6, Issue 2, pages 121–128, 1978.
- [48] Shafi, M. &Quddus, M.M.A (2001). *Bangladesharmatshoshampad (Fisheries Of Bangladesh)* (In Bengali), Kabir Publication. Dhaka, Bangladesh. 159-160
- [49] Skidmore J. F. And Tovell P.W.A. (1972): Toxic effect of sulphate on the gills of rainbow trout. *Water Res.* 6: 217-230.
- [50] SpiritaSharmili V, Avila Varshini R, Kanagapan M (2015); Alkylbenzene Sulphonate, A detergent, induced toxicity on the gill of Zebra fish *Danioerio(Hamilton)* .*Jjfb*s 2015; 2 (4): 33-37
- [51] Sudhasaravanan. R And Biukumari.S.(2014).Effect of different concentrations of detergent on dissolved oxygen consumption in *Lepidoccephalichthyesthermalis*.*World Journal of Pharmaceutical Research*. Volume 4, Issue 2, 940-945.
- [52] Supriyono E., Takashima F., Strussmann C.A. (1998). Toxicity of linear AlkylbenzeneSulphonate (Las) To Juvenile Kuruma Shrimp, *P. Japonicus*: A histopathological study on acute and sub-chronic levels, *J. Tokyo Univ. Fish*, 85(1), 1-10.
- [53] Swedmark M, Braaten B, Emanuelsson E AndGranmo A. (1971). Biological effects of surface active agents on marine animals, *Mar Bioi*, 9, 183-201
- [54] Thatcher T. O. (1966). The comparative lethal toxicity of a mixture of hard ABS detergent products to eleven species of fishes. *Int J Air War Poll IO*: 585-590
- [55] ThophonSm, Kruatrachue M, UpathamEs, Pokethitiyook P, Sahaphong S, Jaritkhuan S. (2003). Histopathologicalalterations of white sea bass, *LatesCalcariferin* acute and subchronic cadmium exposure. *Environmental Pollution*; 121(3):307-320.
- [56] Tkatcheva, V. Hyvarinen, H., Kukkonen, J.,Ryzhkov, L.P. &Holopainen, I.J. (2004). Toxic effects of mining effluents on fish gills in a subarctic lake system In New Russia. *Ecotoxicol. Environ. Saf.* 57: 278-289.
- [57] Valdez Domingos, F.X., Assis, H.C.S., Silva, Manuela, D., Damian R.C., Almeida, M.I.M.,Cestari, M.,Randi, M. & Oliveira Ribeiro, C.A. (2009). Anthropic impact evaluation of two brazilian estuaries through biomarkers in fish. *J. Braz. Soc. Ecotox.*, 4p. 03: 21-30.
- [58] VenkateshChaturvedi, Ashok Kumar. (2010). Toxicity of Sodium Dodecyl Sulfatein fishes and animals. *International Journal of Applied Biology And Pharmaceutical Technology*. Volume: I Issue-2: Aug-Oct -2010, Issn 0976-4550.
- [59] Voegborlo, R. B., Methnani, A. M. E., &Abedin, M. Z. (1999). Mercury, Cadmium and Lead content of canned Tuna Fish. *Food Chem.*, 67 (4), 341 – 345.
- [60] Vutukuru, S.S. (2005). Acute effects of hexavalent chromium on survival, oxygen consumption, hematological parameters, and some biochemical profiles of the Indian major carp,*Labeorohita*. *Int. J. Environ. Res. Public Health*, 2(3):456- 462.
- [61] Walker C. H, Sibly R. M, Hopkin SP, Peakall DB. (2001). *Principles of Ecotoxicology*. 2nd edition; ISBN 0-203-26767-2011
- [62] Winkaler, E.U., Silva, A.G., Galindo, H.C. & Martinez, C.B.R. (2001).Biomarcadoreshistológicos e fisiológicospara o monitoramento da saúde de peixes de ribeirões de londrina, estado do paraná. *Acta Sci.*, 23 (2): 507-514.



10.22214/IJRASET



45.98



IMPACT FACTOR:
7.129



IMPACT FACTOR:
7.429



INTERNATIONAL JOURNAL FOR RESEARCH

IN APPLIED SCIENCE & ENGINEERING TECHNOLOGY

Call : 08813907089  (24*7 Support on Whatsapp)