



iJRASET

International Journal For Research in
Applied Science and Engineering Technology



INTERNATIONAL JOURNAL FOR RESEARCH

IN APPLIED SCIENCE & ENGINEERING TECHNOLOGY

Volume: 6 Issue: VII Month of publication: July 2018

DOI: <http://doi.org/10.22214/ijraset.2018.7141>

www.ijraset.com

Call:  08813907089

E-mail ID: ijraset@gmail.com

A Comparative Study of Aceto - Orcein and Papanicolaou Staining Methods for the Demonstration and Enumeration of Barr body in Buccal Smears

Joshna Johnson¹ and J. Raheese²

¹ UG student, ² Assistant professor Department of pathology, Presentation Centre of Allied Sciences, KUHS university Thrissur, Kerala, India

Abstract: Barr body or Sex chromatin represents inactive X chromosome and are normally found only in female somatic cells, rendered inactive in a process called lyonization. Barr body is Plano convex or in triangle in shape with broad base on nuclear ring, measuring about 0.7-1.2 micrometres. Barr body may appears to be bipartite composed of two hemispherical masses attached closely to each other or as an inverted pyramid with a central pale area. These are normal morphological variant. The Barr body may be found in any nucleus with an open vesicular chromatin pattern. The determination of sex of an individual is an important subject in Forensic Medicine and Criminology and Civil Law. The determination of sex is necessary in both living and dead bodies. The expert opinion of the medico legal specialist regarding positive identification of an individual will be required for the following reasons. For the identification of the sex of individual whether living or dead, for deciding cases related to, intersex condition and in concealed sex. Barr body is an inactivated X chromosome in the normal female somatic cell. Inactivation of these chromosomes is known as Lyonization. The objective of this study is to compare the efficiency and reliability of AO stain and PAP stain in sex determination by identifying Barr bodies in buccal smears. 200 buccal smears are collected from 100 female students. One of the smear were stained with Aceto-Orcein and the other with PAP stain. PAP stain excelled in both the efficiency and accuracy, compared the Aceto-Orcein stain. PAP stain provides good Barr body differentiation from nucleus, increased cytoplasmic transparency, good differentiation of different cell types and reduced pit falls formation but is time consuming when compared to Aceto-Orcein stain.

Key words: Forensic, Barr bodies, Buccal smears, Gender determination, AO stain, PAP stain, Lyonization, Sex chromatin.

I. INTRODUCTION

Barr bodies or Sex chromatin represents the inactive X chromosomes and are normally found only in female somatic cells [1]. Murray Llewellyn Barr OC FRSC FRS (June 20, 1908-May 4, 1995) was a Canadian physician and medical researcher who discovered with graduated student Ewart George Bertram in 1948, an important cell structure the 'Barr body'. During embryonic development one X chromosomes becomes inactive [2]. An unusual gene called X Inactivation specific transcript -XIST initiates the pattern of X inactivation in embryonic cells. If more than two chromosomes are present in an abnormal cells, all but one of them is inactivated. Thus a number of chromatin masses (n) expected can be predicted using formula Number of Barr bodies= $n-1$ where n =number of X chromosomes in cells. In humans with more than one X chromosome, the number of Barr bodies visible at interphase is always one fewer than the total number of X chromosomes. For example, men with Klinefelter syndrome (47, XXY karyotype) have a single Barr body. Whereas women with Triple X syndrome (47, XXX) have two Barr bodies. Barr body will be totally absent in females with Turners syndrome (45, X0). The distribution of Barr body present in an individual cell can be understood by Lyon inactivation hypothesis. The hypothesis, named after Mary Lyon state it, suggesting that the dosage compensation in mammals is by inactivation of all but one X chromosome in cells with more than one X chromosome. The inactivated X chromosome may also appear as drumstick found in neutrophils. Drumsticks are nuclear appendages measuring 1.5 micrometre in diameter. Barr body can be demonstrated in buccal, vaginal, blood, epithelial cells of urinary sediment, skin, hair, nail, dental pulp and amniotic fluid [3]. special stains for nucleus such as PAP, Aceto-Orcein, H & E [4], Cresyl violet, Carbol fuchsin, Thionine stain, Leishman stain, Alkaline methylene blue, Beibrich Scarlet-Fast Green stain, Feulgen and Guard stain and fluorescent stains are used to visualise them [5,1, 14,15]in nuclear membrane of epithelial cells. PAP stain is a multi-chromatic staining developed by George Nicholas Papanicolaou, the father of cytopathology [6, 7]. The universal stain for pre cancer and caner

of oral cavity is PAP stain, which has been used in different laboratories with many modifications. (Asthana A 2014 Papanicolaou1942 [8]) .Our study aimed to compare the Aceto-Orcein and PAP staining methods for the demonstration and enumeration of Barr body in buccal smears.

II. AIM AND OBJECTIVES

A. Aim

Our study aimed the comparative study of AO stain and PAP staining methods for the demonstration and enumeration of Barr body in buccal smears.

B. Objectives

- 1) To assess the quality of staining of the Barr bodies in buccal smears by Aceto- Orcein and PAP staining technique
- 2) To compare the nuclear and cytoplasmic features shown by both stains
- 3) To check the pitfalls formation in PAP stain and Aceto-Orcein stain.

III. MATERIALS AND METHODS

A total of 100 students in the department of MLT included in this study.200 buccal smears were collected from 100 students. One of the smears were stained with Aceto-Orcein and the other with PAP stain.

A. Inclusion Criteria

Buccal smears of healthy individuals were included in this study

B. Exclusion Criteria

Samples such as Skin, Hair, Nail, PAP smear, FNAC slides, Effusions,

C. Methods of Collection of Sample

Written consent was obtained from all the students participated in this study. Explain the simplified procedure of the buccal smear collection. Before samples were taken, rinse their mouth with several changes of water to eliminate debris and excess saliva from the oral mucosa. Exfoliated epithelial cells were obtained from right and left buccal mucosa with the help of a wooden stick. Samples were spread on a clean, grease free, pre numbered glass slide and immediately fixed with fixative (Absolute Alcohol) to avoid exposure to dry air, and otherwise the cells will degenerate.

D. Method for Processing of Samples

For this study to be conducted ,200 samples were taken in total, with 100 smears for PAP stain and 100 smears for Aceto-Orcein stain obtained from students. The smears collected were subsequently stained with PAP and Aceto-Orcein. For Aceto-Orcein staining, place a drop of Aceto-Orcein stain on a pre-numbered clean glass slide, prepare buccal smear and immediately spread it with a coverslip, and examine under high power objective .For PAP staining, the smears were fixed in absolute alcohol for 15-30 minutes, hydration in 80%, 70%, 60% alcohols and distilled water for at least 10 dips, and stained in Harris haematoxylin for 20 minutes, the slides were washed under tap water for 1-2 minutes. Differentiated in 1% acid alcohol (2 dips) ,blued in running tap water (10 dips).Then slides were transferred to 70%,80%,90% alcohols(10 dips) .After staining in OG 6 for 10 minutes, dehydration in 70%,80%,90% alcohol (10 dips) then stained in EA 36 for 10 minutes. These were rinsed in three changes of 95% alcohol for a few seconds each. Finally those were dehydrated in absolute alcohol, cleared in xylene, and mounted in DPX. Examine the slides under high power objective .100 cells were observed in each slide. Out of 100 cells the total number of Barr body present cells were counted. Also , a comparison was made between the factors such as, staining reaction ,quality of Barr bodies, number of Barr body present cells, cost effectiveness of both stains, nuclear staining, cytoplasmic staining, nuclear membrane integrity and cytoplasmic transparency in the smears stained with PAP and Aceto-Orcein.

IV. RESULT

The study was conducted at Histopathology and Cytology Laboratory of Presentation Centre of Allied Sciences, Ernakulum. Two smears where collected from 100 students with a normal oral mucosa. One of the smears (100 smears) were stained with Aceto-Orcein staining and the other smears (100 smears) were stained with the PAP stain. When we compares the staining quality of Barr body in buccal smear (Table 1) PAP is better than Aceto-Orcein, since Aceto-Orcein the nucleus, Barr body, and cytoplasm are in same colour. But in PAP Barr body attain a deep purple colour, as compared to that of cytoplasm and nucleus, so it is easily

recognizable. A comparison of nuclear and cytoplasmic staining features of both stains (Table 2) shows that 78 smears show optimal nuclear features in PAP, and 22 smears are sub optimal. In Aceto-Orcein staining 58 smears show optimal and 42 are suboptimal nuclear features. Since staining deposit may obscure the nuclear details in Aceto-Orcein staining. The differentiation and cytoplasmic transparency were optimal in 75 smears in PAP staining. In 25 smears the cytoplasmic stain penetration was sub optimal, mainly in thick buccal smears. In Aceto-Orcein, 20 smears are optimal and 80 are sub optimal. Table 4 implies the Barr body staining quality of both stains it seems that in PAP staining there is a good Barr body differentiation (deep purple coloured Barr body in blue colour nucleus) as compared to Aceto-Orcein. Since in Aceto-Orcein, Barr body, nucleus, and cytoplasm are in same colour so we cannot differentiate them properly and presence of staining deposits may give false positive reaction. A comparison of the Percentage distribution of Nuclear Staining (Light - Deep stained), Nuclear Membrane Integrity (Smooth-Rough), Cytoplasmic Transparency (High-Low) and Cytoplasmic Staining (Light Stained-Dark Stained) in Aceto-Orcein and PAP Staining the data shows that the International Journal Of Applied Research Parameters (Nuclear Staining, Nuclear Membrane Integrity, Cytoplasmic Staining, and Cytoplasmic Transparency) between both stains the PAP Stain excelled in both efficiency and accuracy, from the Aceto-Orcein stain. When we compare the cost effectiveness of both stains it seems that the cost involved in PAP (INR-999) is lesser compared to Aceto-Orcein (INR -2213) per month.

Aceto-Orcein Staining

Cellular Components	Colour
Nucleus	Brown
Barr body	Dark brown
Cytoplasm	Light brown

PAP STAINING

Colour	Cellular components
Blue	Nucleus
Deep purple	Barr body
Pink/orange	Cytoplasm- superficial cell
Green	Cytoplasm-intermediate cell

Table.1.staining reaction of Barr body in buccal smears

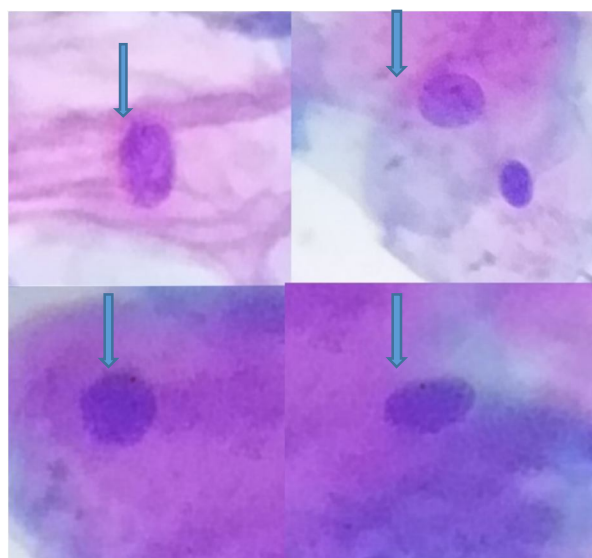


Fig 2 PAP stained Barr body

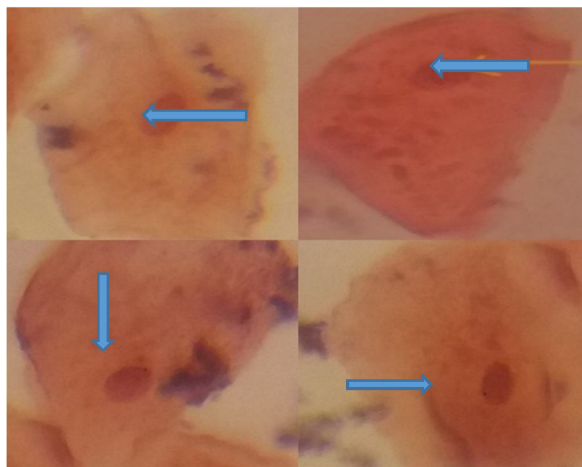


Fig 2 Aceto-Orcein stained Barr body

Stain	Number of samples	Barr Body (%)
Aceto-Orcein	100	5-20
PAP	100	8-25

Table. 2. Comparison of the Barr body in Aceto-Orcein and PAP.

Staining technique	Nuclear staining		Cytoplasmic staining	
	Optimal	suboptimal	Optimal	suboptimal
Aceto-Orcein	58	42	20	80
PAP	78	22	75	25

Table .3 Optimal, Suboptimal Nuclear and Cytoplasmic Features of PAP and Aceto-Orcein.

Staining Technique	Barr Body Staining	
	Optimal	Sub optimal
Aceto-Orcein	65	35
PAP	80	20

Table 4. Comparison of Barr Body Staining Quality Using Aceto-Orcein and PAP.

Parameter Observed	Nuclear Staining (%)		Nuclear Membrane Integrity (%)		Cytoplasmic Staining (%)		Cytoplasmic Transparency (%)	
	Light Stained	Dark Stained	Smooth	Rough	Light Stained	Dark Stained	High	Low
Aceto-Orcein	86	14	21	79	19	81	14	86
PAP	35	65	90	10	85	15	81	19

Table 5. The Percentage distribution of Nuclear Staining (Light –Dark Stained), Nuclear Membrane Integrity (Smooth-Rough), Cytoplasmic staining (Light-Dark Stained), Cytoplasmic Transparency (High-Low) in PAP and Aceto-Orcein.

Aceto-Orcein (One month)		PAP (One month)	
Reagents	Cost	Reagents	Cost
Orcein powder	1863 (5g)	Harris haematoxylin	562
Glacial acetic acid	350 (500ml)	Orange Gelb 6	195
		Eosin Azure 36	242
INR	2213		999

Table 6. Comparison of the Cost Effectiveness of Both Stains.

V. DISCUSSION

The most important challenge of the science of criminal investigation is the concrete identification of persons, subjects, scenes, and actions, possibly connected to the crime [5]. Demonstration of nuclear sex plays a vital role as far as sexing of the individuals is concerned [9]. The Sex chromatin or Barr body is a condensation of chromatin present at the nucleus of female somatic cells only [5]. Manjula Bhai et al, and Suazo et al, did not report any Barr body positive cell in males [9, 10, 11, and 12]. Study conducted by A.D Dixon and J.B .D Torr, David W Smith et al ,Vincent E.Aimakhu and AI Kadiri Claudette, Hajaj Gonzaleze et al, Patricia Munoz et al showed absence of Barr body in males [9,13]. In my study buccal mucosal scrapes were obtained with a wooden stick by smear preparation using Aceto- Orcein and PAP stain for the demonstration of Barr body. Navdeed Kumar et al, used wooden stick for collection of buccal smear [9, 13]. In this study I adopt buccal smear because buccal epithelial cells can be collected easily with simple, inexpensive, quick and in non-invasive manner. PAP stained and Aceto-Orcein stained buccal smears were then analysed by zigzag method to view all the cells [9]. Similar study was conducted by Mittal et al, A.D Dixon and J.B.D Torr and David W Smith et al, who collected buccal smear for the identification of Barr body [9, 10, 11, 12, 13] Reddy et al, in 2012 examined buccal mucosal cells samples stained with Aceto-Orcein to asses confocal microscopy for the detection of Barr body positive cells and find out female sample showed 18-72% of cells showing Barr body positive cells [11]. In the study by Datar U et al, 2013 in which the PAP stain was used the range of Barr body positive cells was observed in 4-20 in females [11]. In my study the PAP staining is better technique compared to Aceto-Orcein staining in producing smears excelled in nuclear and cytoplasmic

staining features, with reduced pitfalls formation. Which is very much related to the study of Datar U et al. In the study by Datar U et al, 2013 in which the PAP stain was used the range of Barr body positive cells was observed 4-20% in females[11]. When I compared the accuracy of both stains, the PAP was better for Barr body compared to Aceto-Orcein. The efficiency of both stains to show effectively the Barr body in given samples, for that International Journal of Applied Research parameters (nuclear staining, nuclear membrane integrity, cytoplasmic staining, and cytoplasmic transparency) were observed between both stains [11]. Considering above compared parameters between both stains I concluded that the PAP stain excelled in both efficiency and accuracy for demonstration of Barr body from Aceto-Orcein stain.

VI. CONCLUSION

In my study "A Comparative Study of Aceto-Orcein and PAP Staining Methods for the Demonstration and Enumeration of Barr body In Buccal Smears" I concluded that, the conventional PAP staining is better than Aceto-Orcein staining for the demonstration of Barr bodies. Since it provides good Barr body differentiation from nucleus, well defined nuclear details, increased cytoplasmic transparency, better nuclear membrane integrity. It provides good differentiation of different cell types in buccal smear. It also reduce pitfalls formation compared to Aceto-Orcein. But it has disadvantages that wet fixation is time consuming, the concentration of alcohol is sometimes questionable and quota of supply is limited and irregular. The colour preservation in PAP is not long lasting. Aceto-Orcein technique is a quicker method, simpler and less technique sensitive. The disadvantages of Aceto-Orcein technique includes we cannot preserve the cells for longer time, because it is a wet preparation, Mounting is not possible. In Aceto-Orcein, Barr body, nucleus, and cytoplasm are in same colour so we cannot differentiate them properly and presence of stain deposit may give false positive reaction. There is no differentiation between the cell types. Since I concluded that PAP stain proved to be a better and more specific stain compared to Aceto-Orcein for visualising Barr bodies and nuclear features in buccal smears.

VII. ACKNOWLEDGEMENT

We extremely grateful to Mrs.Praveena TB Principal In charge Presentation centre of Allied Sciences, Puthenvelikkara, and Ernakulum for giving me the golden opportunity to do this work and providing all moral support and guidance which help me to complete the work successfully. I heartily thanking Dr. Sangeetha K Nainar Head of Clinical Laboratory and Translational Research Department Malabar Cancer Centre Thalasseri, she helped me with lot of suggestions during my work and he gives a way to learn about so many new things, I am really grateful to her. I am also grateful to Rev.Fr.Shygen Kallathil Managing director of Presentation Centre of Allied Sciences, Puthenvelikkara, Ernakulum for the support extended to us for this work.

REFERENCES

- [1] Anoop UR, Remesh V, Balamurali PD, Nirima O Premalatha B, Karthicksree VP- Role of Barr bodies obtained from oral Smears in the determination of sex. *India Journal of Dental Reserch*: 2003; 15:5-17.
- [2] Janigce Yahn & J T Lee – X chromosome X inactivation
- [3] Tusar Mittal, Muralilidhar Saralaya K, Ajee Kuruvilla, Chandrayya Achary – Sex determination from buccal mucosal Scrapes - 2013 Jan-Jun; 5(1):64-67.
- [4] Skip, Brown M, Div HT- The science and application of H&E stain-(Asccp) :05-09.
- [5] Sruthi Singh, Radhika M Bavle, Sreelatha S Hoster, Reshma V Vandrang, Shiny Bopaiah – special stains to disclose Barr bodies in buccal scrape for gender determination. *International Journal of Contemporary Medical Research*. 2017; 4(3):777-780.
- [6] Gill G.W. - What is the PAP stain anyway scan-1999:10(2)
- [7] Modules of histology and cytology and cytology; staining methods: Washington University in st.louis 2014: page148.
- [8] Asthana A Singh A.K – comparison of outline PAP and REAP technique. *International Journal medical and dental Science* 2014, 3(2): 484-489
- [9] Navdeep Kaur, Ruhi Sidhu, Sunira Chandra, Neeraj Taneja – Buccal Barr bodies accuracy Reliability of in sex determination: vol; 2; pg: 168-173
- [10] Tibin Kaithapilly Baby, Priya Thomas, Jayanthi Palani, Rekha Krishna Pillai, Bindhu Pushparajan Ramakrishnen.-sex determination efficiency of PAP and AF stain in buccal smears.vol:9, pg:46.
- [11] Mittal T, Saralaya KM, Kuruvilla A, Achary C. Sex determination from buccal scrapes *Int J Legal Med* 2009;123: 437-440
- [12] Manjula Bhai KH, Yadwad BS, Patil PV: A study of Barr bodies in Indian, Malaysian and Chinese subjects. *Forensic Med Toxicol* 1997; 13:43-44
- [13] Dixon AD, Torr JB: Sex chromatin in oral smears. *Br Med J* 1956; 2:799-800
- [14] Talari Archana, Rithika Bashamalla, Guttikonda Venkateswara RAO, Taneeru Sravaya, Yeluri Sivaranjini, Madala Jaya 9- Kiran – Cytological assessment of barr body in buccal scrapes: A comparative study-*Journal of pierre fauchard academy*; mar2017 .page 11- 13.
- [15] Hilda B Ritter – A simple permanent Aceto-Orcein stain for free cells cultures and homogenates- feb 1938, pages 167-170.



10.22214/IJRASET



45.98



IMPACT FACTOR:
7.129



IMPACT FACTOR:
7.429



INTERNATIONAL JOURNAL FOR RESEARCH

IN APPLIED SCIENCE & ENGINEERING TECHNOLOGY

Call : 08813907089  (24*7 Support on Whatsapp)