



# IJRASET

International Journal For Research in  
Applied Science and Engineering Technology



---

# INTERNATIONAL JOURNAL FOR RESEARCH

IN APPLIED SCIENCE & ENGINEERING TECHNOLOGY

---

**Volume: 7      Issue: IV      Month of publication: April 2019**

**DOI: <https://doi.org/10.22214/ijraset.2019.4476>**

**[www.ijraset.com](http://www.ijraset.com)**

**Call:  08813907089**

**E-mail ID: [ijraset@gmail.com](mailto:ijraset@gmail.com)**

# Diabetic Retinopathy, An Eye Disease Prediction System using Convolutional Neural Network

Sheetal Mutha<sup>1</sup>, G.J. Chhajed<sup>2</sup>

<sup>1,2</sup>Department of Computer Engineering, VPKBIET, Baramati, India

**Abstract:** "Diabetic Retinopathy" is the certifiable issue that is made by the diabetes and there are enormous number of diabetes patients worldwide, which impact the vision and results in visual deficiency and DR happens because of harm of the corridors and veins that are available in the fundus of the eye retina and its avoidance stays testing. Fundus pictures assume a principal job for the examination of DR. With the visual investigation of the fundus pictures and thought of shading photos, Ophthalmologists specifically inspect the presence and seriousness of DR. This procedure turns out to be expensive and time engaging. The framework for forecast of Diabetic Retinopathy is being proposed and is for the examination of fundus picture by dissecting its area of premium and applying convolutional neural network for order of the fundus pictures and to create and send a mechanized examination programming for ophthalmologists and patients in clinical applications, which thusly will accelerate the task and make it more affordable.

**Keywords:** Diabetic Retinopathy, Image Processing, Deep Learning

## I. INTRODUCTION

The World Health Organization anticipated that there were a large number of individuals optically damaged around the world. Regardless of the way that the quantity of visual deficiency cases has been undeniably decreased lately, it is anticipated that 80 percent of the instances of visual weakening are preventable or treatable. These days Diabetic Retinopathy (DR) is one of the significant purposes behind being in charge of causing vision misfortune and blindness[1][2][3]. Likewise, these illnesses will encounter a vast development later on because of increment in diabetes and maturing populace in the present populace. Worldwide screening programs have been orchestrated to check the expansion of preventable eye illnesses. However, lamentably DR exists at a disturbing rate for such projects to distinguish and treat retinopathy productively on an individual premise.

### A. What is Diabetic Retinopathy (DR)?

The The wording "DR-Diabetic Retinopathy" is known as dynamic pathology and it is found in people who have diabetes mellitus for a long time. It causes a gathering of sores in the retina. The number just as sorts of injuries that are accessible on the retina can decide the seriousness and likelihood of the sickness. It is an ailment which is in charge of deficient insulin - a hormone that moves the sugar into the cells consumed from the blood[4][5].

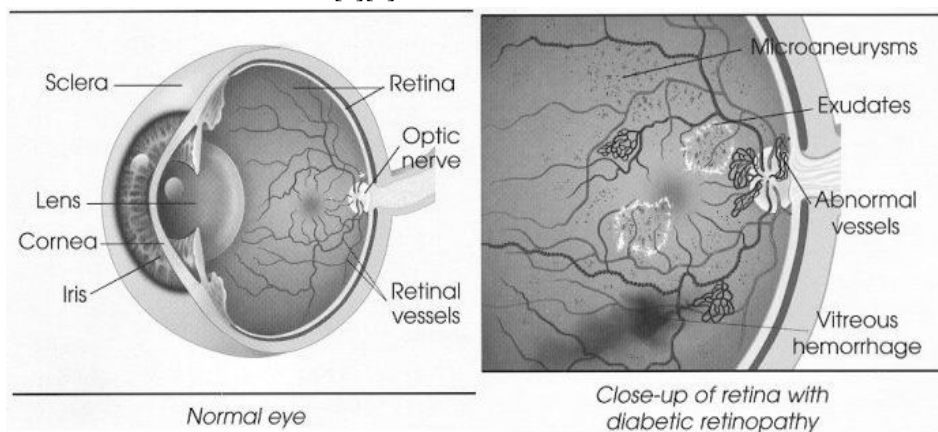


Fig. 1. Normal Retina And Diabetic Retinopathy

Accordingly, more sugar gain ascendancy in the blood which can hurt the whole body including veins. The accompanying figure portrays the fundus pictures with diabetic retinopathy(DR)[15][16][17].

**B. There are Two Types of DR**

- 1) **Non-Proliferative DR (NP-DR):** This is the beginning period of the sickness in which side effects will be mellow or nonexistent. In NPDR, the veins in the retina are debilitated. Modest lumps in the veins, called microaneurysms, may release liquid into the retina. This spillage may prompt swelling of the macula.<sup>4</sup>
- 2) **Proliferative DR (P-DR):** This is the further developed type of the illness. At this stage, course issues prevent from having the retina of oxygen. Therefore new, delicate veins can start to develop in the retina and into the vitreous, the gel like liquid that fills the back of the eye. The fresh recruits vessels may spill blood into the vitreous, blurring vision. What are the stages of Diabetic Retinopathy?

**C. Diabetic Retinopathy has four Stages**

- 1) **Mild Non proliferative Retinopathy.** At this stage, microaneurysms occur. They are small areas of balloon-like swelling in the retina's tiny blood vessels.
- 2) **Moderate Non proliferative Retinopathy.** This stage is when blood vessels that nourish the retina are blocked.
- 3) **Severe Non proliferative Retinopathy.** In this stage, Many more blood vessels are blocked, depriving several areas of the retina with their blood supply. These areas of the retina send signals to the body to grow new blood vessels for nourishment.
- 4) **Proliferative Retinopathy.** At this advanced stage, the signals sent by the retina for nourishment trigger the growth of new blood vessels. These new blood vessels are abnormal and fragile. They grow along the retina and along the surface of the clear, vitreous gel that fills the inside of the eye. By themselves, these blood vessels do not cause symptoms or vision loss. However, they have thin, fragile walls. If they leak blood, severe vision loss and even blindness can result.

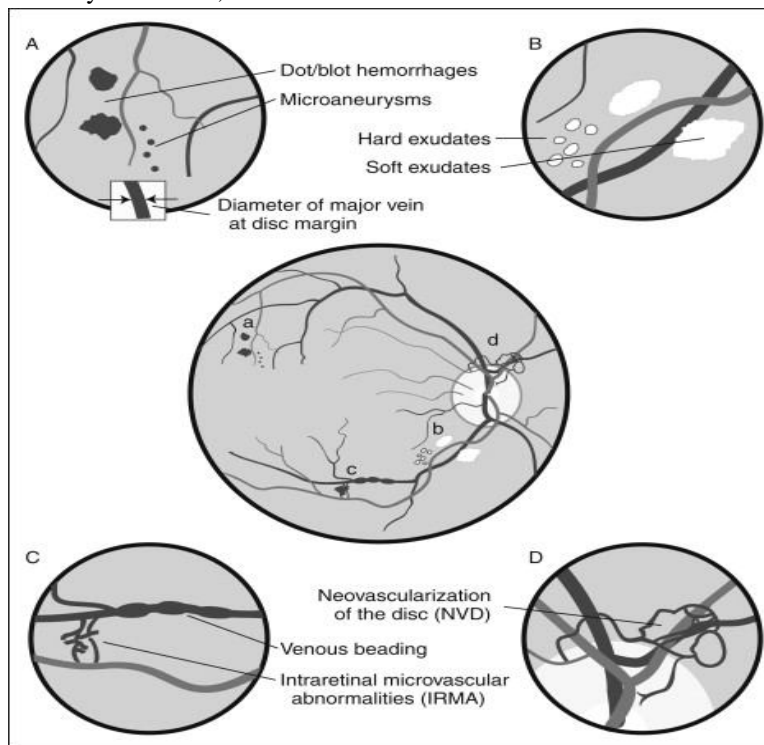


Fig. 2. Normal and abnormal features of DR image.

**II. LITERATURE SURVEY**

Approach one is based on Retinal Image Analysis Using Machine Learning: Algorithm Santhakumar R, et al. Recommended a technique for the screening apparatus, comprising of Patch and image level expectation[6]. Sohini Roychowdhury, et al. Discuss about The identification of neovascularization and vascular beading brought about by proliferative DR, and druse brought about by macular degeneration[7]. Approach 2 is based on Features Extracted from Fundus Images Using SVM: Shishir Maheshwari, et al. Presents a methodology based out of automated conclusion of glaucoma framework, introducing another mode for a modernized examination of glaucoma utilizing computerized fundus pictures dependent on EWT i.e Empirical Wavelet Transform[8]. Ramon Pires, et al. Focuses on the type of system utilized for highlights of the retinal pictures, using the BossaNova and Fisher Vector

techniques[9].R. Adalarasan, et al. Portrays a system utilizing versatile channels separated in green channel of the picture[10]. Approach 3 is based on Neural Network for Detection of Diabetic Retinopathy: Xiyang Liu, et al. Talk about a strategy dependent on PC vision for the electronic determination of slit lamp images [11]. B. Sumathy et al. Indicate for what is abnormal in the fundus pictures with picture preprocessing procedure and grouping with AI[12]. Approach 4 is based on Computer Aided Diagnosis System For Diabetic Retinopathy:

Mike Voets, et al. Replication thinks about are identified with finding of diabetic retinopathy in fundus photos. The profound learning can be utilized to diagnose diabetic retinopathy[13]. Romany F. Mansour Control examines portrays that the transformative processing techniques can show critical job for lifting DR-CAD utilitarian parts[14].

### III. PROPOSED METHODOLOGY

Recognize DR utilizing fundus camera pictures to maintain a strategic distance from vision misfortune and visual deficiency as a major aspect of early malady analysis of such patients.

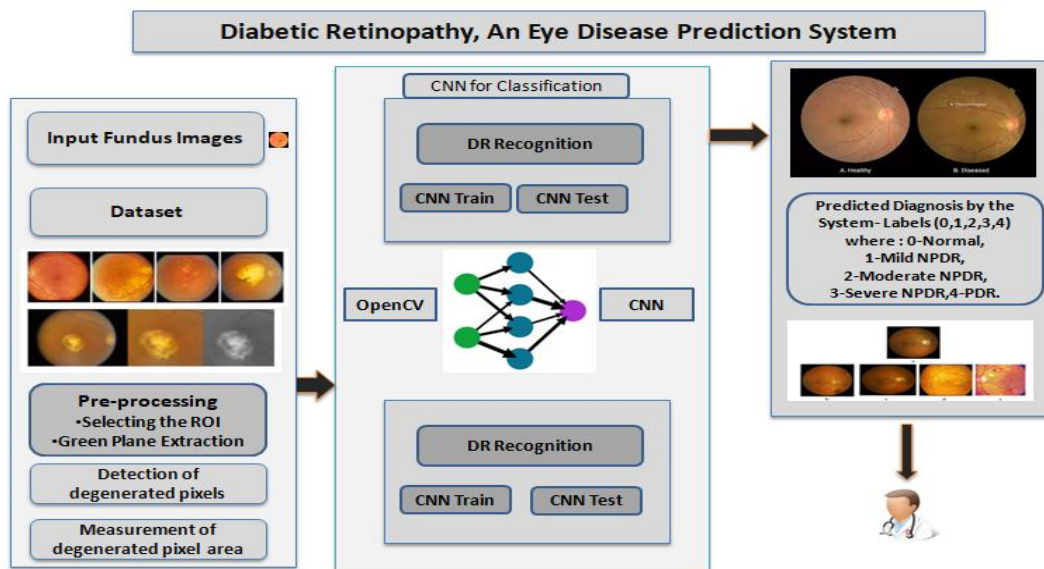
The intent of the proposed framework are as per the following:

- A. Provide a stage to identify the ailment from the retinopathy picture.
- B. To give help to ophthalmologists, which thusly will support to diminish the manual identification time.
- C. To give assistance to regular man at remote spots to recognize the ailments, whenever changed over to easy to use item.

1) *Diabetic Retinopathy Prediction System:* Distinguish Diabetic Retinopathy (DR) utilizing fundus camera pictures to keep away from vision misfortune and visual impairment as a major aspect of early sickness determination in patients. Diabetic Retinopathy (DR) is one of the predominant reason for vision misfortune and visual deficiency in maturing populace. Right now, there is no mending for DR, anyway early discovery and resulting treatment may keep the serious visual perception misfortune or moderate the progression of the illness. The forecasting of DR is the proportion of exploring whether the patient is influenced by DR, given the activity set of the patients input fundus picture . This procedure mix utilization of a colossal foremost of fundus pictures with labels shifted from 0 to 4 Diabetic retinopathy (DR) expectation arrangement of guidelines will empower specialists to assessment varieties from different fundus camera pictures with the assistance of picture preprocessing and profound learning utilized for order to process and analyze the fundus pictures quickly and correctly diminishing the manual screening time. Above all, it diminishes the time-span for executing the total system over a larger dataset.

### IV. SYSTEM ARCHITECTURE

#### A. The Proposed System



The particulars of the framework is as per the following:

- 1) *Original Fundus Retinal Image*: The dataset is gathered from kaggle site. Which includes fundus images identified with Diabetic Retinopathy regarding distinctive kinds of DR.
  - 2) Preprocessing:
    - a) Selecting the Region of Interest(ROI):
      - i) The first retinal picture is edited to choose the ROI.
      - ii) A ROI (Region of Interest) is a space of a picture, which is graphically selected from a window showing that picture. Any ROI is utilized as a cover o expel pixels from the picture.
      - iii) Evacuating pixels implies setting their power to zero.
      - iv) While doing the rationale activities on dim scale pictures pixel esteems are refined as string of paired numbers. The AND as well as activities are utilized for concealing, that is for choosing sub-pictures in a principle picture.
    - b) *Green Plane Extraction*
      - i) Green plane is extracted and a series of morphological opening operations are applied.
      - ii) Erosion supersedes by dilation with a specific structuring element. The erosion operation takes portion of data as input. Firstly the image which is to be eroded. And secondly is a set of coordinate points known as a structuring element i.e. kernel
  - 3) *Detection Of Degenerated Pixels*
    - a) To recognize the declined locale (dull pixels) molecule examination is performed.
    - b) A molecule is an adjacent locale of non-zero pixels.
    - c) These bit are separated from a dim scale picture by thresholding the picture into foundation and frontal area states.
    - d) Zero-esteemed pixels are put out of sight state, and the non-zero esteemed pixels are place in the closer view. Molecule examination comprises of a progression of handling activities.
    - e) Geometric highlights of the declined territory are determined, for example, zone, volume.
  - 4) *Measurement of Degenerated Pixels Area*: To ascertain the complete declined zone, histogram is determined, which gives the quantity of non-zero pixels and zero-pixels. The quantity of non-zero pixels speaks to the declined territory.
  - 5) *Classification and identification of the type of DR*
    - 1) *Using CNN*: Input for CNN is taken from Kaggle website <https://www.kaggle.com/c/diabetic-retinopathy-detection/data> Output is - Presence of DR in each image on a range of 0 to 4.

A CNN comprises of an information layer, yield layer and various shrouded layers. The layers of a CNN by and large subsist of convolutional layers, pooling layers, completely associated layers and standardization layers. CNN will be utilized to prepare the pictures investigation motor for perceiving essential information from pictures. As for the venture embraced, the info will be the fundus pictures and the yield forecast toward the end will be the class mark as indicated by the accompanying range:

- 0 - No DR
- 1 - Mild
- 2 - Moderate
- 3 - Severe
- 4 - Proliferative DR

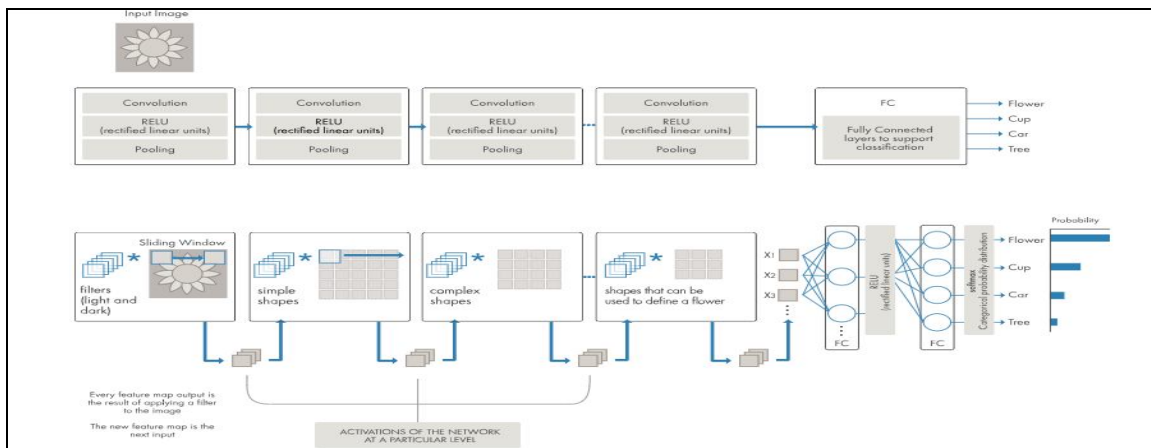


Fig. 4. Convolution Neural Network

## V. ALGORITHM STEPS

Diabetic Retinopathy Detection and Prediction Algorithm steps

- 1) *Input*: Fundus Images from dataset
- 2) *Output*
  - a) DR detection decision and
  - b) DR type prediction
- c) Input Fundus image from dataset
- d) Preprocessing of image
- e) Selecting the Region of Interest(ROI)
- f) Green plane extraction
- g) Detection of degenerated pixels(Particle analysis to detect non-zero pixels)
- h) Measurement of degenerated pixels area(Histogram area calculation)
- i) Identification and Prediction of the type of DR using CNN

## VI. MATHEMATICAL MODEL

Let us assume,

$I = \{I_1, I_2, I_3, \dots, I_n\}$  as the image in dataset.

- 1) Input Test Images ( $I$ ) =  $fI_g$
- 2) Preprocessing of Images  $P = \{A, B, C_g\}$

Where,

- a)  $A$  = Input Images  $fA_g$
- b)  $B$  = Two methods for preprocessing  $fB_1, B_2g$

Where,

- i)  $B_1$  = Selecting the Region of Interest (ROI)
- ii)  $B_2$  = Green Plane Extraction
- iii)  $C$  = Output of preprocessed images
- 3) Detection Process( $D$ ) =  $fE, R_1, R_2, \dots, R_n, (f_1, f_2), (f_3, f_4)g$

Where,

- a)  $E$  = Detection of degradation pixels.
- b)  $fR_1, R_2, \dots, R_n$  = Particle analysis to detect non-zero pixels.
- c)  $f(f_1, f_2), (f_3, f_4)g$  = detected non-zero pixels.
- 4) Measurement of degenerated pixels area ( $M$ ) = ( $H$ value,  $C$ value)

Where,

- a)  $H$ value = Histogram Value.
- b)  $C$ value = CNN Value.
- 5) Classification and identification of DR images ( $R$ )

$f_s1, s_2, s_3, \dots, s_n$  = Prediction of Classification and identification of the type of DR using CNN.

- 6) Output:  $N = \{v_1, v_2, v_3, v_n\}$

Are the number of identified and classified DR image  $I$ .

Our System  $S = \{I, P, D, M, R, N_g\}$

## VII. RESULT AND DISCUSSIONS

### A. Dataset Used

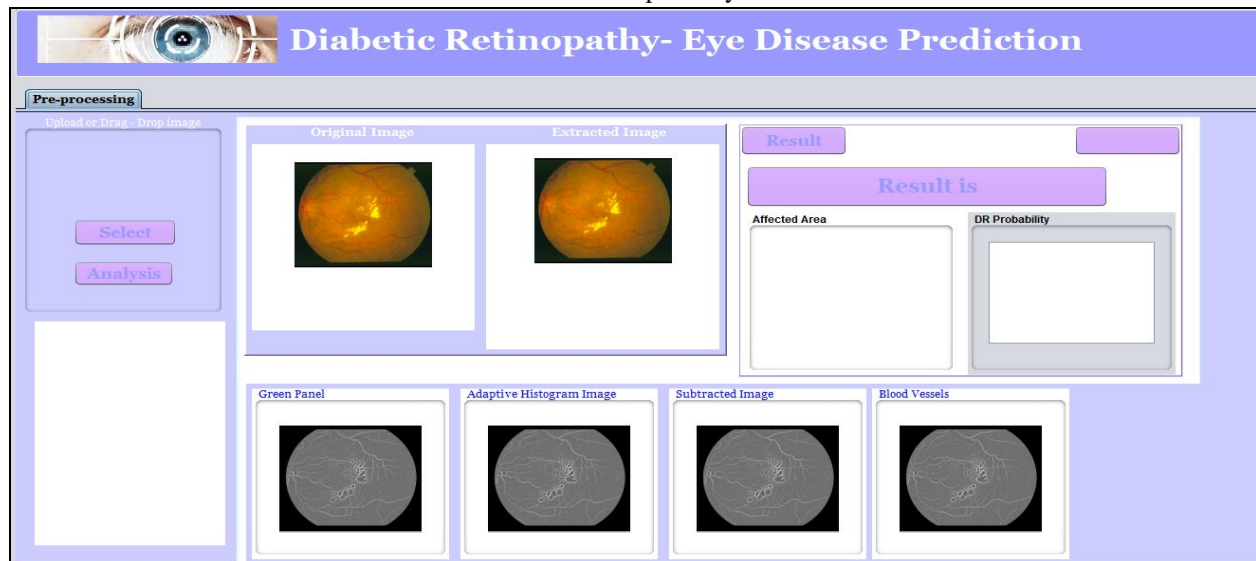
- 1) Data set of Fundus Images.
- 2) The dataset comprises of retinal fundus images. These images are distributed into 5 different classes depending on their attribute.
- 3) Kaggle diabetic retinopathy database.
- 4) Publicly accessible by California Healthcare Foundation on Kaggle website.

**B. Experimental Flow**

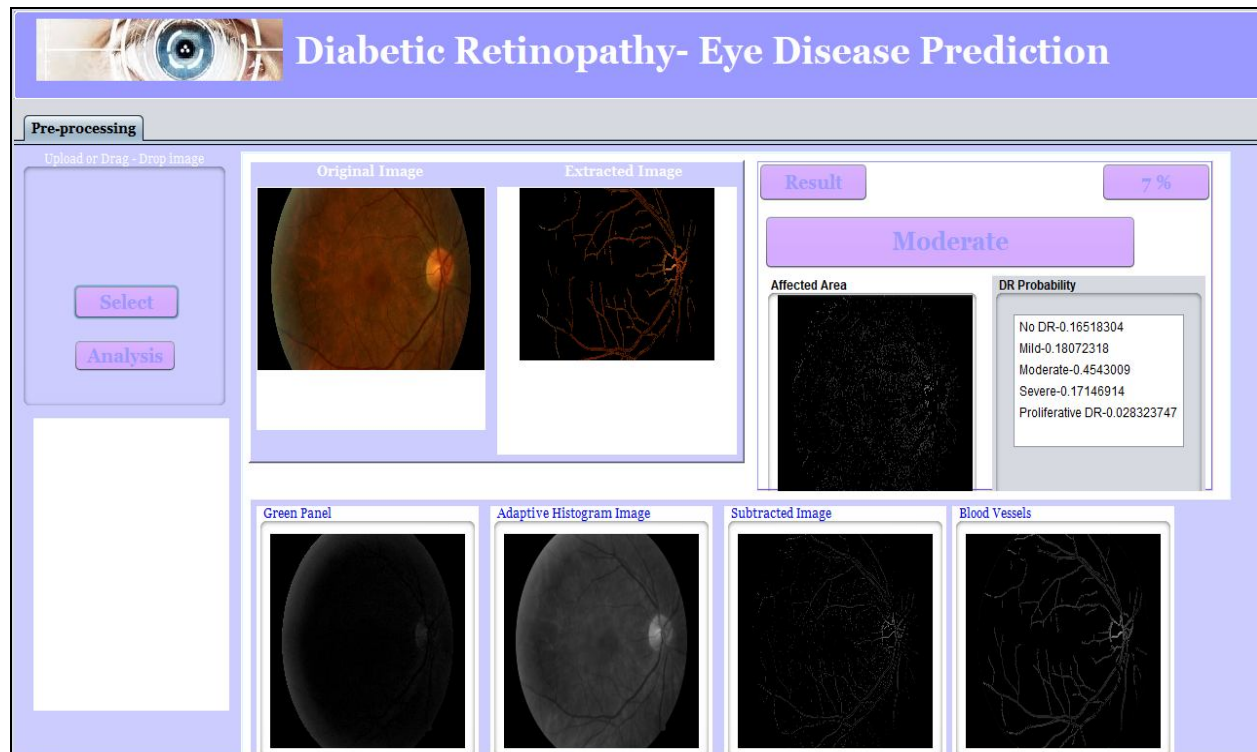
The proposed system for now being is trained on remote system having configuration -

- 1) *Hardware Utilized* - Dell - G7 15.6" Laptop - Intel Core i7 - 16GB Memory - NVIDIA GeForce GTX 1060 - 128GB Solid State Drive + 1TB Hard Drive.
- 2) *Software Utilized* - Net-beans, MySQL, JDK, Python, keras and Tensor- flow.
- 3) *Input Size* - The total images used are around 8,000 images, and for now the system is being trained and tested on around 1200 to 2000 images with respect to each label depicting a class.

The Home Screen of the Proposed system is as follows



And the Detection and Prediction screen is as shown below



The experimental observations are recorded as shown in the following confusion matrix

Confusion Matrix For Multiple Class

Confusion Matrix For Multiple Class						
No Of Output States	No Of Output States					
	0	1	2	3	4	
0	1971	19	1	8	0	
1	16	1129	2	23	9	
2	8	3	1891	87	50	
3	2	25	159	1786	16	
4	0	24	4	8	1525	
ground truth	2000	1200	2000	2000	1600	

### VIII. RESULTS

The following metrics used to evaluate the classification performance: accuracy, precision, and recall. Accuracy indicates as the sum of correct classifications over the total count of input instances.

$$Accuracy = (TP + TN) / (TP + TN + FP + FN)$$

The precision is the percentage of images that are correctly classified as positive out of all the images that are classified as positive, and the recall is the percentage of images that are correctly classified as positive out of all the images that are actually positive. The metrics for precision and recall are defined as

$$Precision = \frac{TP}{TP + FP}$$


$$Recall = \frac{TP}{TP + FN}$$

The sensitivity measures the part of actual positive phase of DR that is accurately diagnosed. On the other hand, specificity measures the part of negative stage accurately diagnosed. The larger the sensitivity and specificity, the improved is the diagnosis.

Two performance measures are measured namely Sensitivity and Specificity. Sensitivity gives the percentage of pixels correctly classified as vessels by the method and specificity gives the percentage of non-vessels pixels classified as non-vessels by the method as follows:

$Sensitivity = \frac{TP}{(TP) + (FN)}$	$Specificity = \frac{TN}{(FP) + (TN)}$
--	--

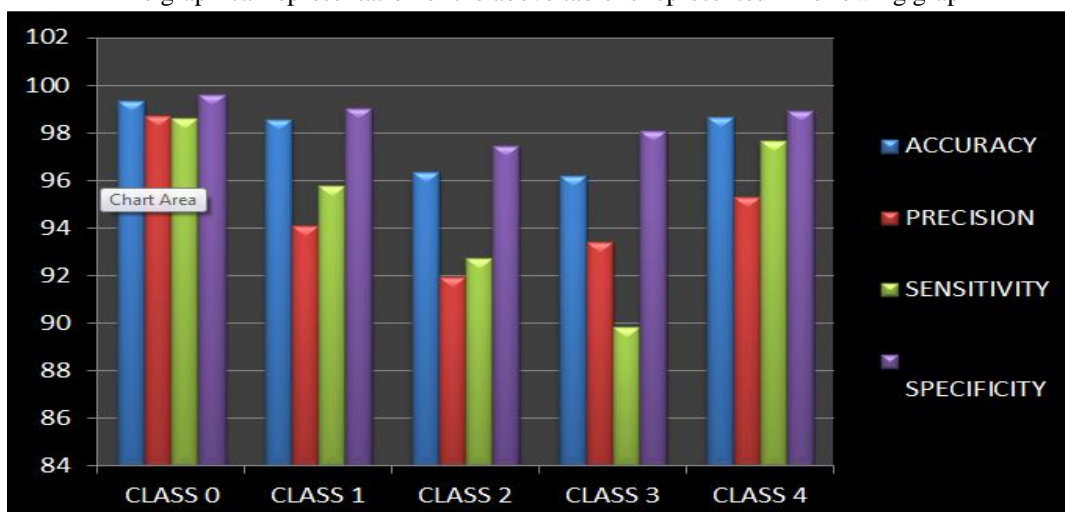
Class-wise Distribution of images





	ACCURACY	PRECISION	SENSITIVITY	SPECIFICITY
CLASS 0	99.35	98.7	98.6	99.59
CLASS 1	98.56	94.08	95.76	99.02
CLASS 2	96.36	91.93	92.74	97.48
CLASS 3	96.2	93.41	89.84	98.1
CLASS 4	98.68	95.31	97.69	98.91

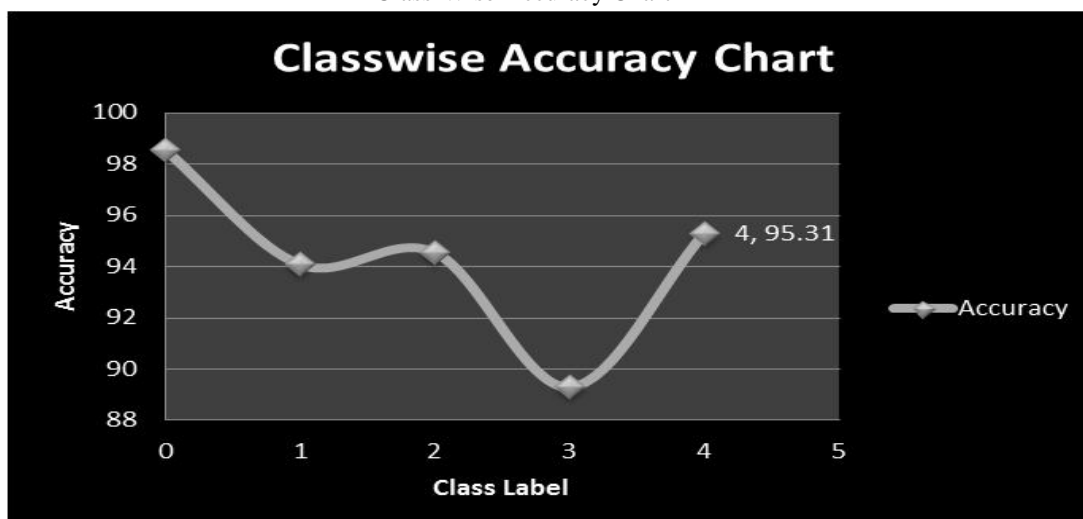
The graphical representation of the above table is represented in following graph



The severity of the disorder is measured depending on the area calculated from the preprocessing and also from the CNN algorithm, Depending on the severity, there are four phases such as mild, moderate, severe and proliferate phase. A treatment can also be based on the severity. Certain known treatments are Vitrectomy, Scatter laser treatment, Focal laser treatment and Laser photo coagulation.

$$\text{The disease severity is computed as} = \frac{\text{Affected area}}{\text{Total area of retina}}$$

Class-Wise Accuracy Chart



## IX. CONCLUSIONS

The significant quantity of feat are devolve on deepening the image quality by upgrading image distinction and background gleam over inexperienced channel anatomical structure pictures and the system is able to achieve 97% accuracy. Thus, perceptive overall literature's and individual contributions, it is unreal that deep learning schemes can be of significance to strengthen all the comprising useful parts of the diabetic retinopathy, as well as pre-processing by enhancing pictures ROI choice and green plane extraction and classification of the required outcome.

In recent research it is discussed the Gcforest outperforms CNN in case of solving computer vision applications more accurately. Thus, our future work would be to extend it accordingly.

## REFERENCES

- [1] Diabetic Retinopathy causes, diagnosis and treatment available from <https://www.aoa.org/patients-and-public/eye-and-visionproblems/glossary-of-eye-and-vision-conditions/diabetic-retinopathy>
- [2] Single-field fundus photography for diabetic retinopathy screening: a report by the American Academy of Ophthalmology. 2004. Available from: <https://www.ncbi.nlm.nih.gov/books/NBK71159/>
- [3] American Academy of Ophthalmology Retina Preferred Practice Pattern Panel: Diabetic Retinopathy Preferred Practice Pattern. AAO. San Francisco, 2017. Available from <https://www.aao.org/preferred-practicepattern/diabetic-retinopathy-ppp-updated-2017>
- [4] Diabetes Sep 2006, 55 (9) 2401-2411; DOI: 0.2337/db05-1635. Available from <http://diabetes.diabetesjournals.org/content/55/9/2401>
- [5] Pires, R., Avila, S., Jelinek, H.F., Wainer, J., Valle, E. and Rocha, A., 2017. Beyond lesion-based diabetic retinopathy: a direct approach for referral. *IEEE journal of biomedical and health informatics*, 21(1), pp.193-200.
- [6] Santhakumar, R., Tandur, M., Rajkumar, E.R., Geetha, K.S., Haritz, G. and Rajamani, K.T., 2016, November. Machine learning algorithm for retinal image analysis. In *Region 10 Conference (TENCON), 2016 IEEE* (pp. 1236-1240). IEEE.
- [7] Roychowdhury, S., Koozekanani, D.D. and Parhi, K.K., 2014. DREAM: diabetic retinopathy analysis using machine learning. *IEEE journal of biomedical and health informatics*, 18(5), pp.1717-1728.
- [8] Maheshwari, S., Pachori, R.B. and Acharya, U.R., 2017. Automated diagnosis of glaucoma using empirical wavelet transform and correntropy features extracted from fundus images. *IEEE journal of biomedical and health informatics*, 21(3), pp.803-813.
- [9] Pires, R., Avila, S., Jelinek, H.F., Wainer, J., Valle, E. and Rocha, A., 2017. Beyond lesion-based diabetic retinopathy: a direct approach for referral. *IEEE journal of biomedical and health informatics*, 21(1), pp.193-200.
- [10] Adalarasan, R. and Malathi, R., 2018. Automatic Detection of Blood Vessels in Digital Retinal Images using Soft Computing Technique. *Materials Today: Proceedings*, 5(1), pp.1950-1959.
- [11] Liu, X., Jiang, J., Zhang, K., Long, E., Cui, J., Zhu, M., An, Y., Zhang, J., Liu, Z., Lin, Z. and Li, X., 2017. Localization and diagnosis framework for pediatric cataracts based on slit-lamp images using deep features of a convolutional neural network. *PloS one*, 12(3), p.e0168606.
- [12] Sumathy, B. and Poornach, S., 2018. Automated DR and prediction of various related diseases of retinal fundus images. *Biomedical Research*, 29.
- [13] Voets, M., Mllersen, K. and Bongo, L.A., 2018. Replication study: Development and validation of deep learning algorithm for detection of diabetic retinopathy in retinal fundus photographs. *arXiv preprint arXiv:1803.04337*.
- [14] Mansour, R.F., 2017. Evolutionary Computing Enriched Computer- Aided Diagnosis System for Diabetic Retinopathy: A Survey. *IEEE reviews in biomedical engineering*, 10, pp.334-349.
- [15] General Information Diabetic Retinopathy available from <https://en.wikipedia.org/wiki/Diabetic-retinopathy>
- [16] Details on Diabetic Retinopathy available from <http://care.diabetesjournals.org/content/26/suppl-1/s99>
- [17] Mutha, Sheetal. (2019). Diabetic Retinopathy, an Eye Disease Prediction System: Survey. *International Journal for Research in Applied Science and Engineering Technology*. 7. 201-207. 10.22214/ijraset.2019.1035.



10.22214/IJRASET



45.98



IMPACT FACTOR:  
7.129



IMPACT FACTOR:  
7.429



# INTERNATIONAL JOURNAL FOR RESEARCH

IN APPLIED SCIENCE & ENGINEERING TECHNOLOGY

Call : 08813907089  (24\*7 Support on Whatsapp)