



IJRASET

International Journal For Research in
Applied Science and Engineering Technology



INTERNATIONAL JOURNAL FOR RESEARCH

IN APPLIED SCIENCE & ENGINEERING TECHNOLOGY

Volume: 7 Issue: IV Month of publication: April 2019

DOI: <https://doi.org/10.22214/ijraset.2019.4560>

www.ijraset.com

Call:  08813907089

E-mail ID: ijraset@gmail.com

A Novel Approach for Detection of Diabetic Retinopathy using the Concept of Computer Vision

Tripti Singh¹, Akhilesh Sharma²

^{1,2}Department of Computer Science & Engineering, Chouksey Engineering College

Abstract: Diabetic retinopathy (DR) and diabetic macular edema are basic confusions of diabetes which can prompt vision misfortune. The reviewing of DR is a genuinely mind boggling process that requires the discovery of fine highlights, for example, micro aneurysms, intraregional hemorrhages, and intraregional micro vascular anomalies. Along these lines, there can be a decent measure of grader fluctuation. There are distinctive techniques for acquiring the reference standard and settling contradictions among graders, and keeping in mind that it is generally acknowledged that mediation until full accord will yield the best reference standard, the contrast between different strategies for settling differences has not been inspected broadly. According to the extending use of sugar materials in human life and creating example of the machine life, the prevalence of diabetes is on the rising. It is observed all patients with this affliction for the most part experience the evil impacts of decrease or mishap their vision. For the modified examination of diabetic retinopathy (DR) and affirmation of a diabetic eye from a sound eye. In this paper basically we proposed an approach where we try to find the diabetic retinopathy by using of the human retina eye. In this work basically we did the comparative analysis for the healthy eye and diabetic retinopathy eye. As per the result our proposed approach performs well as compare to previous existing approach

Keywords: Machine Learning, Sugar, Retinopathy, Retina, Filtering

I. INTRODUCTION

At present, the headway of diabetes is a champion among the most basic troubles in therapeutic thought. The proportion of patients that experience the evil impacts of diabetes is extending. As shown by the International Diabetes Federation report, on an overall scale 382 million people have diabetes, and around 4.3 million of them are in Iran [1]. Of late, diabetic retinopathy (DR) is an average purpose behind visual inadequacy in diabetic patients [2]. An early assurance of diabetes can construct the shot of neutralizing activity of visual disability, and besides when in doubt; the vision will a little bit at a time decrease. Nevertheless, if the patients negligent about this condition, it will manufacture the chance of mischief to their vision. As such, the early area of diabetes is basic to reduce the chance of vision what's increasingly, visual hindrance. Experts and ophthalmologists use a remarkable device called "fundus camera" to choose the eye issues [3]. Starting at now, utilizing propelled photography has an immense effect in field of ophthalmology, through giving the probability of picture taking care of for help to clinical investigations and prescriptions. Ophthalmologists usually use the ophthalmoscope for eye examinations. Ophthalmologists take photographs of the retina for further examination on retina-related sickness. From time to time modified devices are used for picture interpretation advance. The systems that are made by the blend of PCs and therapeutic science for dismembering data, are called PC Aided Diagnosis (CAD) [4]. For instance, these CAD systems which expected for retinopathy acknowledgment, should be prepared to recognize the hidden symptoms of retinopathy. So according to the depicted criteria by ophthalmologists, the end is performed. These structures use propelled pictures of retina as information and after that subject to a figuring, help ophthalmologists in picture examination. A common CAD structure includes four major advances: Image pre-getting ready, locale of interest (ROI) definition, features extraction and decision what's more, gathering Optic circle is way and leave zone of vessels and visual recognition nerves to retina and its restriction and division is a basic issue in retina pictures customized separating systems [6]. Intra-retinal oily exudates are one the reactions of DR that is clear and are in like manner a sign for closeness of the Oedema. If the exudates and oedema appear in the yellow region of the retina, it is the key driver of vision setback [7]. From this time forward, in this examination we have tried to structure a brisk what's progressively, precise CAD system for determination the DR by using propelled retina pictures and portraying these photos in two classes, which are eyes with DR and non-DR pictures (sound eyes). [5]. Diabetic retinopathy (DR) and diabetic macular edema (DME) are among the fundamental purposes behind vision hardship around the globe. A couple of techniques for assessing the reality of diabetic eye disorder have been developed, including the Early Treatment Diabetic Retinopathy Study Grading System [8], the Scottish Diabetic Retinopathy Grading System [9], and the International Clinical Diabetic Retinopathy (ICDR) disease earnestness scale [10]. The ICDR scale is one of the more for the most part used clinical scales and includes a 5-point grade for DR: no, delicate, moderate, extraordinary, and proliferative. The assessing of DR is a really

awesome procedure that requires the unmistakable verification and assessment of fine features, for instance, microaneurysms (MAs), intraretinal hemorrhages, intraretinal microvascular varieties from the standard, and neovascularization. In this way, there can be a respectable part of grader variability, with intergrader kappa scores going from 0.40 to 0.65 [8, 11– 14]. This isn't shocking in light of the way that grader variance is an exceptional issue with human comprehension of imaging in other remedial fields, for instance, radiology [15] or pathology [16]. A couple of methodologies have been proposed for settling contrasts between graders what's more, getting a reference standard. One philosophy includes taking the larger part decision from a social event of something like 3 self-governing graders. Another involves having a social occasion of somewhere around 2 graders work openly and a while later having a third generally logically senior grader conference inconsistencies, with that individual's decision filling in as the reference standard. Last, a social affair of somewhere around 3 graders may at first survey openly and after that with everything taken into account talk about inconsistencies until there is full accord on the last grade. The complexity between various techniques for settling logical inconsistencies has not been dissected comprehensively. Deep learning [17] is a gathering of AI techniques that licenses PCs to pick up capability with the most judicious features explicitly from pictures, given a sweeping dataset of checked points of reference, without deciding rules or features explicitly. It has similarly been associated starting late in therapeutic imaging, making exact counts for a grouping of request assignments, including melanoma [18], chest danger lymph center point metastasis [19,20], likewise, DR [21– 23] Because the framework is set up to envision names that have been joined with the photos, it is fundamental that the names definitely address the state of illness found in the image, especially for the appraisal sets. In this examination, we investigate the vacillation in different procedures for checking on, meanings of reference measures, and their effects on structure models for the area of diabetic eye disease. This paper present the technique for detection of diabetic Retinopathy using the concept of computer vision & . The rest of the paper is organized as follows. Necessary background and underlying principle on diabetic Retinopathy is given in Section II whereas Section III describes proposed methodology & Implementation details. Experimental results and its analysis are given in Section V. Finally, Section VI concludes the paper.

II. LITRECTURE REVIEW

A modernized framework for the acknowledgment of splendid wounds (exudates) in retinal pictures is displayed by El Abbadi and AlSaadi [124]. The technique has been improved to detach and limit the optic circle and recognize exudates. In this examination, surface examination procedure used for registering surface dependent on truthful estimation relies upon quantifiable qualities of the power histogram. In the preprocessing step, they used the green channel for better acknowledgment of the optic plate and bruises. After they ousted the optic hover according to the shape and separation over, they expelled exudates with a particular breaking point. The suggested methodology was apply on standard database and achieved promising results. Mansour [25] offered another procedure called the Genetic Calculation and Vertex Chain Code (GAVCC), where a cross-point number framework was used for vascular bifurcation and between zone revelation. This system jobs geo-metrical parameters of the retinal vascular tree for diagnosing hypertension and separated retinal exudates thus from shading retinal pictures. The cultivated precision exhibits a prevalent in their proposed structure. Ramlugun et al. [26] used the green channel for improved area of vessels. To improve the retinal vasculature adaptively, they used multifaceted nature compelled flexible histogram leveling (CLARE). The photos were confined into eight by eight tiles, and after that histogram leveling was secretly prompted non-covering pertinent areas. Close-by histograms using a fasten limit that makes certain close-by complexities are constrained and can't be raised to the most extraordinary. Also, the broad vessels are successfully perceived from the establishment because of a high interior multifaceted nature. For the CLARE, a low fasten limit is used. Regardless, for little vessels a high fasten limit is used for low offset refinement with the establishment. Then again, the use of a high fasten limit assembles the hullabaloo in the image, and in this way raises the likelihood of getting false distinguishing pieces of proof. As a response for this issue, a hysteresis thresholding computation is used. Starting there forward, the two dimensional (2D) Gabor composed channel technique is used for division. Two estimations of 0" are used, a generous motivating force for considerable vessels and a humbler impetus for little vessels. In this consider, the used technique for thresholding in [27] is used since it could great with the Gabor channel. Finally, they used the hysteresis thresholding figuring to deal with the issue. The suggested system associated on DRIVE dataset, and achieved results show the precision of this procedure was better than the gotten precision by techniques without CLARE. Another technique for revelation of veins was organized by Youssef and Solouma [28]. The strategy starts with an edge acknowledgment estimation making an over parceled picture. Next, another part based computation is used to perceive the veins exactly. This figuring considers retinal vein characteristics, including powers, width expand, and presentations for the particular division reason. The removed vein tree, nearby optic plate are subtracted from the over separated picture to get fundamental exudates estimation. The last exudates estimation is picked up by morphological changing according to the presence of exudates. This methodology got promising outcomes with respect to affectability and identity. The course adaboost classifier was proposed by Cheng and Jhan [29]. They united it with Support Vector Machine (SVM) and

adaboost, and a continuous individual by walking acknowledgment structure with a single camera. They got the individual by walking cheerful regions with a fixed size window, and performed credit extraction to contender zones and adaptable pictures with a Haar-like square shape quality check. They totaled bystander portrayal by using the offered course adaboostSVM classifier, as it can conform to a couple obviously classifiers, it can feasibly make course classifiers according to getting ready set. Along these lines, by using the adaboost classifier in their system, they lessened screw up rates of structure. Two potential examinations associated on fundus pictures of diabetic patients were proposed by Dupas et al. [30]. The robotized ID of microaneurysms and exudates was coordinated on to two little picture databases, where wounds were checked physically. The PC helped explanatory structure for the assessing and recognizable proof of diabetic retinopathy. Loathsome region optical levelheadedness tomography (SD-OCT) is an extensively used gadget for the assurance and evaluation of retinal disorders. Utilizing interferometry, low clarity light is reflected from retinal tissue to make a two-dimensional grayscale image of the retinal layers. Differentiations in reflectivity of retinal layers produce various powers on SD-OCT check, thinking about noninvasive view of specific retinal layers [31-34]. This clear cross-sectional life structures of the retina is much of the time suggested as "in-vivo histology" and is instrumental in the assessment of a couple of ordinary retinal pathologies including diabetic retinopathy (DR), age-related macular degeneration (AMD), macular hole, macular edema, vitreo-macular balance (VMT), choroid neovascularization, and epiretinal film. SD-OCT can be also used to study retinal nerve fiber layer (RNFL) thickness for the evaluation of glaucoma [35]. Retinal layer morphology and retinal thickness estimations are used to perceive and check retinal varieties from the standard, for instance, macular edema, and these estimations are additionally used to screen malady movement and reaction to treatment (31-33). Except for retinal thickness estimations, current SD-OCT gives constrained target quantitative information, and in this way pictures must be abstractly deciphered by an eye expert (1). Accordingly, discoveries are helpless to human predisposition and mistake. In a perfect world, OCT information ought to be followed quantitatively and unbiasedly so as to screen the movement of variations from the norm just as help in the analysis of different pathologies. The test with illnesses, for example, DR is that the patient doesn't know about the sickness until the adjustments in the retina have advanced to a dimension that treatment will in general be less successful. Along these lines, computerized early recognition could restrain the seriousness of the malady and help ophthalmologists in exploring and treating it all the more proficiently. Basically there is mainly three challenges is faced by the current available Watermarking technique and those challenges are:

- 1) Most of algorithm did not proper concept of Computer Vision on medical processing
- 2) Latency are high in previous approaches
- 3) Lack of Accuracy problem as it's a medical
- 4) There is need of process on which is able to process the Diagnosis Diabetic Retinopathy in very less time with proper accuracy and quality.

III. PROPOSED METHADODOLOGY & IMPLIMENTATION

In this section we discuss about the implementation details of previous existing work and our proposed work. Here we implement the previous existing work which are based on masking & thresholding approach , here we also presnt our proposed approach which is able to find the good quality result.

A. Proposed Diabetic Retinopathy Using the concept of computer vision

As we know about Computer vision is the science that aims to give a similar, if not better, capability to a machine or computer. Computer vision is concerned with the automatic extraction, analysis and understanding of useful information from a single image or a sequence of images.

According to our proposed approach basically we design a system which is able to handle the retina images and based on the analysis it will able to identify that present retina image is effected by diabetic or not. Here we performs followings steps which are followings:

- 1) Task perform on Input image and separate the RGB image in to different parts
- 2) Find the histogram of green part
- 3) Remove the small objects from the binary image
- 4) Get the rid of blobs
- 5) Find the area of blobs
- 6) Find the all properties of blobs like number of blobs, area, size etc.
- 7) Perform Convex Hull Scan
- 8) Find the optic nerve boundary

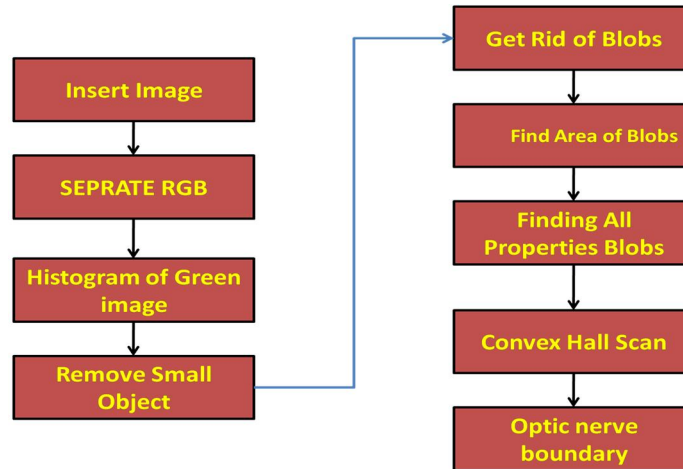


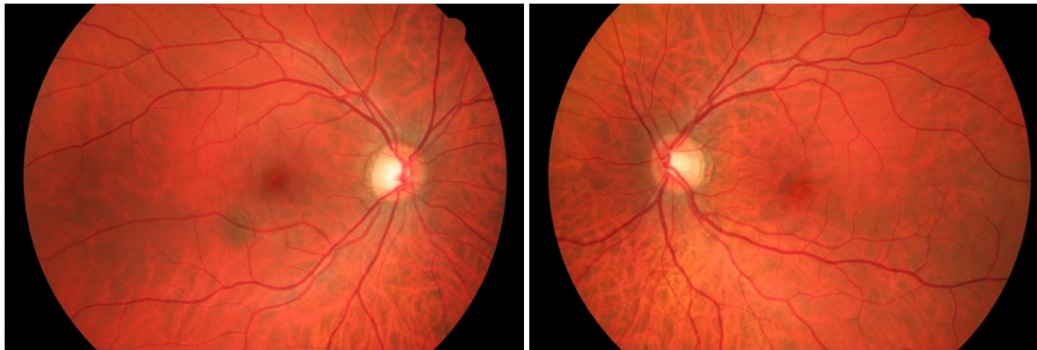
Fig. 3.1 Proposed System

IV. RESULT ANALYSIS

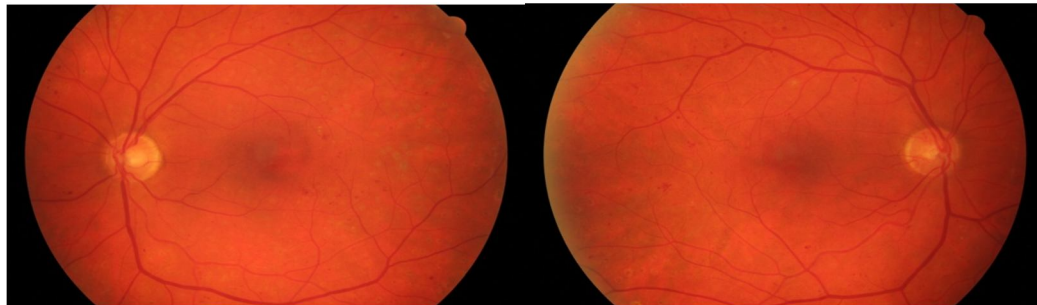
In this section we present the comparative study about our proposed approach with all different type of existing approach. Here we will use some existing scientific parameter which will prove proper justification for our proposed approach. Here we take 2 health & two unhealthy retina images and based on that we perform the result analysis:

A. Test Images

B. Healthy Retina Images



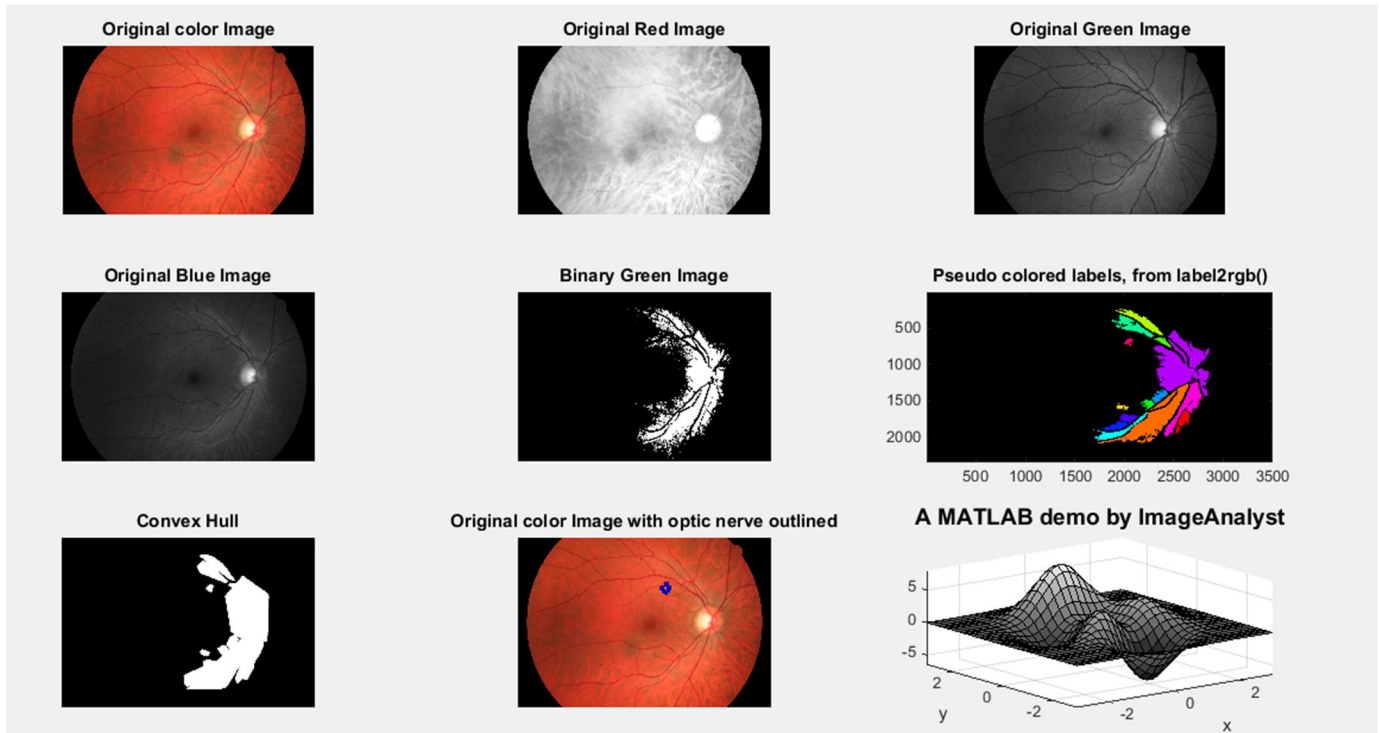
C. Unhealthy Retina Images



D. Time Complexity Analysis

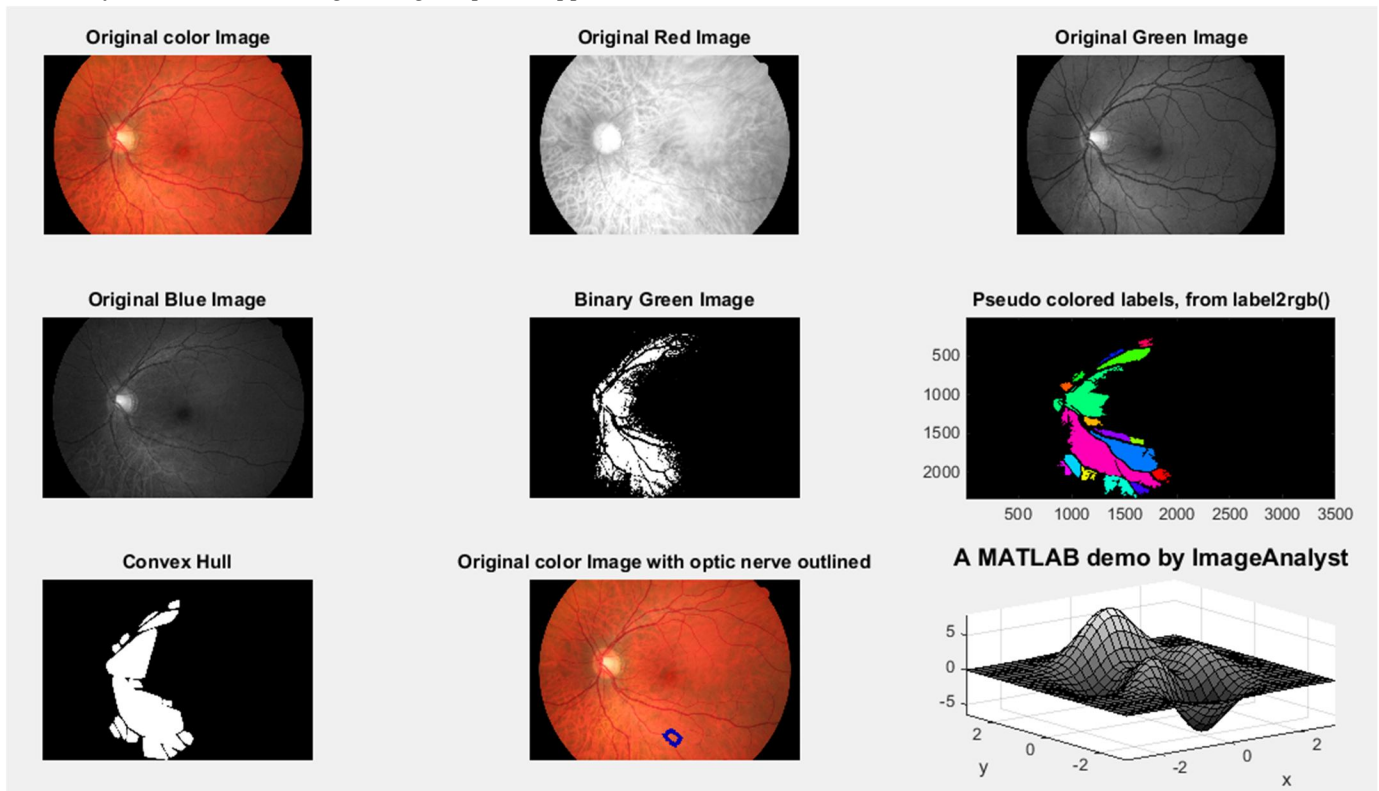
Images	Thresholding Based Approach	Proposed Approach
Healthy retina 1	53 Sec	32 Sec
Unhealthy Retina 2	52 Sec	14 Sec
Healthy retain 3	44 Sec	30 Sec
Unhealthy retina 4	36 Sec	20 Sec

E. Result of 1 Health retina Image Using Proposed Approach



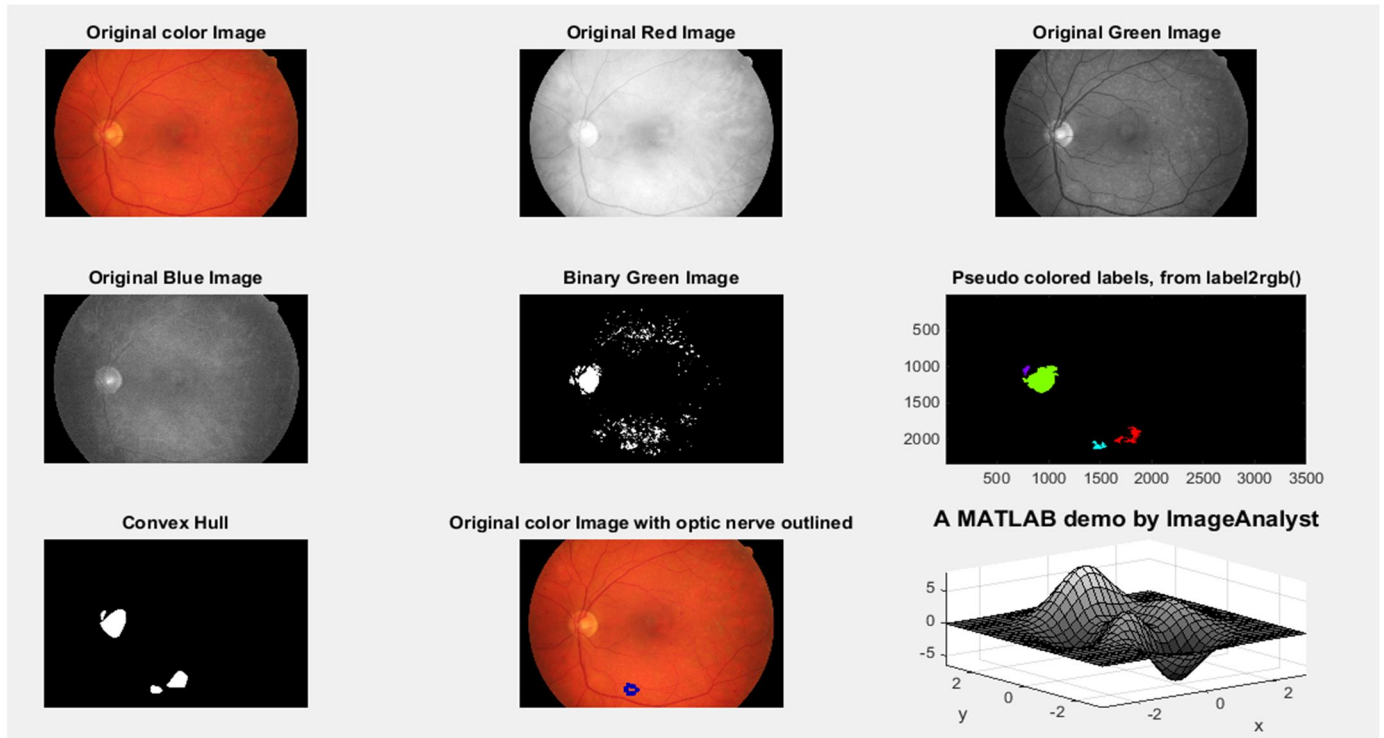
According to result here we are getting big convex hull so there is no any diabetic effect.

F. Result of 3 Health retina Image Using Proposed Approach



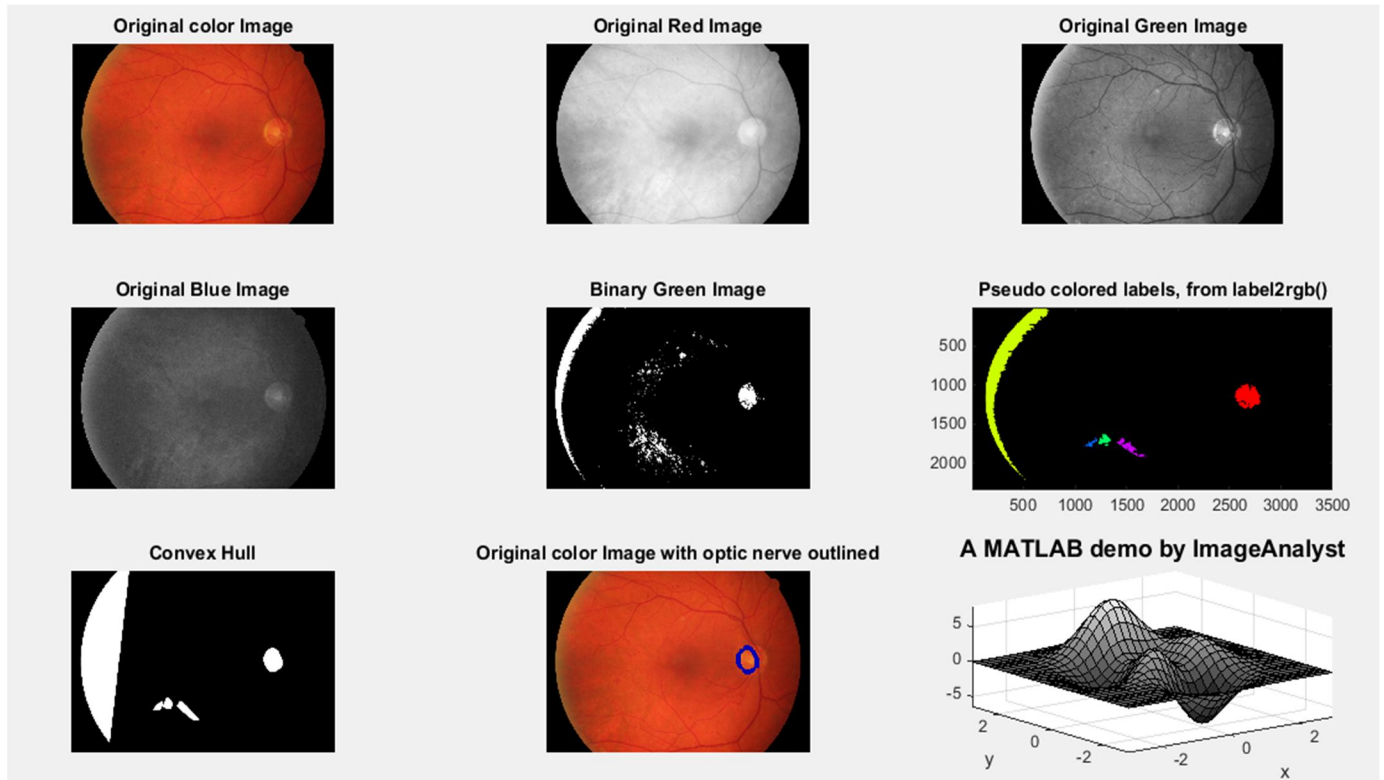
According to result here we are getting big convex hull so there is no any diabetic effect.

G. Result of 2 Unhealthy retina Image Using Proposed Approach



According to result here we are getting small convex hull so there is diabetic effect.

H. Result of 4 Unhealthy retina Image Using Proposed Approach



According to result here we are getting small convex hull so there is diabetic effect. So overall our proposed approach performs well interms of quality & time complexity

V. CONCLUSIONS

DR is a standout amongst the most widely recognized microvascular difficulties of diabetes with the possibility to cause serious vision misfortune and visual deficiency and an overwhelming impact on personal satisfaction. In spite of a strong collection of proof in regards to the significance of exacting metabolic control and treatment of related hazard factors Journal of Ophthalmology 7 especially hypertension, inability to keep up target HbA1c levels is a noteworthy contributing reason for advancement and movement of DR. Screening conventions utilizing mydriatic and, ideal, nonmydriatic retinography ought to be actualized in the essential consideration setting. As indicated by the International Federation of Diabetes (IFD), there will be 642 million individuals with diabetes on the planet in 2040, with a predictable emotional weight of the malady, especially troubling in the most extraordinary populace sections, that is, the youngsters and the older subjects.. Here we present a novel approach which is based on computer vision according to this approach we are able to get accurate result in minimum time.

REFERENCES

- [1] International-Diabetes-Federation. (2013, 15 Aug). Diabetes In IRAN. Available: <http://www.idf.org/membership/mena/iran>
- [2] Singh and R. C. Tripathi, "Automated early detection of diabetic retinopathy using image analysis techniques," International Journal of Computer Applications, vol. 8, pp. 18- 23,2010.
- [3] F. Wood. (2007, 15 March). Photo Release NIDEK Announces World's First Auto-Focus, Auto-Alignment Fundus Camera. Available: <http://globenewswire.com/newsrelease/2007/04/03/357460/1165611en!Photo-Release-NIDEKAnnounces-World-s-First-Auto-Focus-Auto-AlignmentFundus-Camera>.
- [4] htrnl N. Hadavi, M. J. Nordin, and A. Shojaeipour, "Lung Cancer Diagnosis Using CT-Scan Images Based on Cellular Learning Automata," in 2th International Conference On Computer and Information Sciences (ICCOINS), kuala lumpur, 2014.
- [5] P. Sharma, S. Malik, S. Sehgal, and J. Pruthi, "Computer Aided Diagnosis Based on Medical Image Processing and Artificial Intelligence Methods," International Journal of Information and Computation Technology, vol. 3, pp. 887-892,2013.
- [6] C. Pereira, L. Gonyalves, and M. Ferreira, "Optic disc detection in color fundus images using ant colony optimization," Medical & biological engineering & computing, vol. 51, pp. 295-303, 2013.
- [7] A. Osareh, M. Mirmehdi, B. Thomas, and R. Markham, "Automated identification of diabetic retinal exudates in digital colour images," British Journal of Ophthalmology, vol. 87, pp. 1220-1223,2003.
- [8] Early Treatment Diabetic Retinopathy Study Research Group et al. Grading diabetic retinopathy from stereoscopic color fundus photographs an extension of the modified airle house classification: Etdrs report number 10. Ophthalmology, 98(5):786-806, 1991.
- [9] iabetic retinopathy screening services in scotland: A training handbook July 2003: page 17.
- [10] http://www.ndrs-wp.scot.nhs.uk/?page_id=1609. Accessed: June 21, 2017. 1
- [11] American academy of ophthalmology. international clinical diabetic retinopathy disease severity scale, detailed table. <http://www.icoph.org/dynamic/attachments/resources/diabetic-retinopathy-detail.pdf>. Accessed: Oct 14, 2016. 1
- [12] Ingrid U Scott, Neil M Bressler, Susan B Bressler, David J Browning, Clement K Chan, Ronald P Danis, Matthew D Davis, Craig Kollman, Haijing Qin, Diabetic Retinopathy Clinical Research Network Study Group, et al. Agreement between clinician and reading center gradings of diabetic retinopathy severity level at baseline in a phase 2 study of intravitreal bevacizumab for diabetic macular edema. Retina (Philadelphia, Pa.), 28(1):36, 2008.
- [13] Helen K Li, Larry D Hubbard, Ronald P Danis, Adol Esquivel, Jose F Florez-Arango, Nicola J Ferrier, and Elizabeth A Krupinski. Digital versus film fundus photography for research grading of diabetic retinopathy severity. Invest Ophthalmol Vis Sci, 51(11):5846- 5852, 2010.
- [14] apna Gangaputra, James F Lovato, Larry Hubbard, Matthew D Davis, Barbara A Esser, Walter T Ambrosius, Emily Y Chew, Craig Greven, Letitia H Perdue, Wai T Wong, et al. Comparison of standardized clinical classification with fundus photograph grading for the assessment of diabetic retinopathy and diabetic macular edema severity. Retina (Philadelphia, Pa.), 33(7), 2013. 1,
- [15] Paisan Ruamviboonsuk, Khemawan Teerasuwanajak, Montip Tiensuwan, and Kanokwan Yuttitham. Interobserver agreement in the interpretation of single-field digital fundus images for diabetic retinopathy screening. Ophthalmology, 113(5):826-832, 2006.
- [16] Joann G Elmore, Carolyn K Wells, Carol H Lee, Debra H Howard, and Alvan R Feinstein. Variability in radiologists' interpretations of mammograms. New England Journal of Medicine, 331(22):1493-1499, 1994.
- [17] Joann G Elmore, Gary M Longton, Patricia A Carney, Berta M Geller, Tracy Onega, Anna NA Tosteson, Heidi D Nelson, Margaret S Pepe, Kimberly H Allison, Stuart J Schnitt, et al. Diagnostic concordance among pathologists interpreting breast biopsy specimens. Jama, 313(11):1122-1132, 2015.
- [18] Yann LeCun, Yoshua Bengio, and Geoffrey Hinton. Deep learning. Nature, 521(7553):436- 444, 2015.
- [19] Andre Esteva, Brett Kuprel, Roberto A Novoa, Justin Ko, Susan M Swetter, Helen M Blau, and Sebastian Thrun. Dermatologist-level classification of skin cancer with deep neural networks. Nature, 542(7639):115-118, 2017.
- [20] Yun Liu, Krishna Gadepalli, Mohammad Norouzi, George E Dahl, Timo Kohlberger, Aleksey Boyko, Subhashini Venugopalan, Aleksei Timofeev, Philip Q Nelson, Greg S Corrado, et al. Detecting cancer metastases on gigapixel pathology images. arXiv preprint arXiv:1703.02442, 2017.
- [21] Babak Ehteshami Bejnordi, Mitko Veta, Paul Johannes van Diest, Bram van Ginneken, Nico Karssemeijer, Geert Litjens, Jeroen AWMvan der Laak, Meyke Hermesen, Quirine F Manson, Maschenka Balkenhol, et al. Diagnostic assessment of deep learning algorithms for detection of lymph node metastases in women with breast cancer. Jama, 318(22):2199-2210, 2017.
- [22] Varun Gulshan, Lily Peng, Marc Coram, Martin C Stumpe, Derek Wu, Arunachalam Narayanaswamy, Subhashini Venugopalan, Kasumi Widner, Tom Madams, Jorge Cuadros, et al. Development and validation of a deep learning algorithm for detection of diabetic retinopathy in retinal fundus photographs. Jama, 316(22):2402-2410, 2016.
- [23] Rishab Gargeya and Theodore Leng. Automated identification of diabetic retinopathy using deep learning. Ophthalmology, 2017.

- [24] Daniel Shu Wei Ting, Carol Yim-Lui Cheung, Gilbert Lim, Gavin Siew Wei Tan, Nguyen D Quang, Alfred Gan, Haslina Hamzah, Renata Garcia-Franco, Ian Yew San Yeo, Shu Yen Lee, et al. Development and validation of a deep learning system for diabetic retinopathy and related eye diseases using retinal images from multiethnic populations with diabetes. *Jama*, 318(22):2211–2223, 2017.
- [25] N. K. EI Abbadi and E. H. AI-Saadi, "Automatic Detection of Exudates in Retinal Images," *International Journal of Computer Science Issues (IJCSI)*, vol. 10, pp. 237-242, 2013.
- [26] R. F. Mansour, "Using Genetic Algorithm for Identification of Diabetic Retinal Exudates in Digital Color Images," *Journal of Intelligent Learning Systems & Applications*, vol. 4, pp. 188- 198,2012.
- [27] G. S. Rarnlugun, V. K. Nagarajan, and C. Chakraborty, "Small retinal vessels extraction towards proliferative diabetic retinopathy screening," *Expert Systems with Applications*, vol. 39,pp. 1141-1146,2012.
- [28] D. Zhang, Q. Li, and J. You, "A modified matched filter with double-sided thresholding for screening proliferative diabetic retinopathy," *IEEE Transactions on Information Technology in Biomedicine*, vol. 13, pp. 528-534,2009.
- [29] D. Youssef and N. H. Solouma, "Accurate detection of blood vessels improves the detection of exudates in color fundus images," *Computer methods and programs in biomedicine*, vol. 108, pp. 1052-1061,2012.
- [30] W.-C. Cheng and D.-M. Jhan, "A cascade classifier using Adaboost algorithm and support vector machine for pedestrian detection," in *IEEE International Conference on Systems Man and Cybernetics (SMC)*, 2011, pp. 1430-1435.
- [31] G.J. Jaffe, J. Caprioli: Optical coherence tomography to detect and manage retinal disease and glaucoma. *Am J Ophthalmol* 137, 156-169 (2004) DOI: 10.1016/S0002-9394(03)00792-X
- [32] An automated approach for early detection of DR using OCT images 206 © 1996-2018 2. A. Baghaie, Z. Yu, R.M. D'Souza: Stateof-the-art in retinal optical coherence tomography image analysis. *Quant Imag Meg Surg* 5, 603 (2015)
- [33] L.M. Sakata, J. DeLeon-Ortega, V. Sakata, C.A. Girkin: Optical coherence tomography of the retina and optic nerve—a review. *Clin Exp Ophthalmol* 37, 90-99 (2009) DOI: 10.1111/j.1442-9071.2009.02015.xPMid:19338607
- [34] D. Huang, E.A. Swanson, C.P. Lin, J.S. Schuman, W.G. Stinson, W. Chang, M.R. Hee, T. Flotte, K. Gregory, C.A. Puliafito: Optical coherence tomography. *Science* 254, 1178-1181 (1991) DOI: 10.1126/science.1957169PMid:1957169 PMCID:PMC4638169
- [35] C.P. Gracitelli, R.Y. Abe, F.A. Medeiros: Spectral-domain optical coherence tomography for glaucoma diagnosis. *Open Ophthalmol J* 9, 68-77 (2015) DOI: 10.2174/1874364101509010068 PMid:26069519 PMCID:PMC4460228



10.22214/IJRASET



45.98



IMPACT FACTOR:
7.129



IMPACT FACTOR:
7.429



INTERNATIONAL JOURNAL FOR RESEARCH

IN APPLIED SCIENCE & ENGINEERING TECHNOLOGY

Call : 08813907089  (24*7 Support on Whatsapp)