



IJRASET

International Journal For Research in
Applied Science and Engineering Technology



INTERNATIONAL JOURNAL FOR RESEARCH

IN APPLIED SCIENCE & ENGINEERING TECHNOLOGY

Volume: 7 Issue: VI Month of publication: June 2019

DOI: <http://doi.org/10.22214/ijraset.2019.6233>

www.ijraset.com

Call:  08813907089

E-mail ID: ijraset@gmail.com

An Elementary Method for the Computation of Artery to Vein Ratio in Fundus Images

Vinay Savant¹, Nayana Shenvi²

^{1,2}Dept. of Electronics and Telecommunication Engineering, Goa College of Engineering, Goa University, India

Abstract: Medical research has shown that the artery to vein ratio can be used to detect Hypertensive Retinopathy. This ratio can be calculated by carefully studying the fundus images of the patients. Modern softwares can be used to process these images. This article will describe a simple method to compute the ratio of mean artery width to mean vein width. The images for testing of the described method have been taken from local eye clinic run by Althea Barbosa, Goa and few have been collected from online database STARE and DRIVE.

Keywords: Hypertensive Retinopathy, AVR, Fundus image, Artery, Vein.

I. INTRODUCTION

Eyes are the most important sense in our body. With age, high blood pressure can affect the retinal vessels and the condition is termed as Hypertensive Retinopathy. There are two types of vessels, arteries and the veins. Initial stages of Hypertensive Retinopathy shows changes in the width of the arteries. Hence the ratio of artery diameter to vein diameter is different than that in normal patients. 15 images each of Hypertensive Retinopathy and healthy patients have been collected [1]. A sample fundus image is shown in Figure 1.

II. RELATED WORK

Claudia Kondermann et al [2] worked to categorize the two types of vessels but the case was to detect the increase in the width of the arteries for the detection of Diabetic Retinopathy patients. The ideas used were support vector machines and artificial neural networks. Different properties of the vessels were put to use. Arteries are brighter than veins, there is clear inner tube seen in an artery which is not to be seen in the vein. If we carefully observe the fundus images, at a particular coordinate of the image, arteries have less caliber if we compare both the vessels.

Aziah Ali et al [3] have used Gabor Wavelets and a generalized cut-off of the pixel values to track the vessels. In vessel following methodology, the tubular skeleton lines are followed to build up a way that are probably going to be a piece of the vessel foundation. Chanjira Sinthanayothin et al [4] have presented the paper to detect the optic plate. The optic circles were found by distinguishing the territory with the most noteworthy variety in comparison to the neighbouring pixels. Calculations by software were used to recognize the primary locales of the fundus image. Once the optic plate location is found, its location can be used to emphasize more on the vessels near the same.

Yiming Wang et al [5] proposed a method where boundaries of veins are first separated by Sobel Edge operators. To make the calculation quick, edge diminishing is utilized to protect only one seed point in each cross section of the vessels.

Kevin Noronha et al [6] have described a paper in the similar field Radon transform was used to partition the blood vessel from the rest of the image. They used Hough Transform to locate the central optic plate.

Helena M. Pakter et al [20] have used micrometric method for direct measurement of the diameter and digitized them. The resolution was found using cubic spline method. 10 moderate coordinates were created in the direction vertical to the vessel edge. Vessel widths were naturally separated from this curve, with cut-foci characterized where the outside edge position is equal to two times the mean noise along the slice.

III. DATASET

Fundus Photography records the retina, the neurosensory tissue in our eyes which deciphers the optical pictures we see into the electrical driving forces our mind gets. The retina can be captured legitimately as the understudy is utilized as both a passage and exit for the fundus camera's enlightening and imaging light beams. Ophthalmologists utilize these retinal photos to pursue, analyse, and treat eye maladies. A fundus camera is a particular low power magnifying instrument with an appended camera. Its optical plan depends on the aberrant ophthalmoscope. Fundus photos are visual records which archive the current ophthalmoscopic look of a patient's retina. One picture is worth, in this occurrence, a thousand words in the doctor's notes. They enable the doctor to further examine a patient's retina, to distinguish retinal switches on development, or to audit a patient's retinal discoveries with an associate.

Fundus photos might be helpful if there is another sickness affecting the fundus and for the arranging of extra treatment choices. The medicinal need of fundus photography and other symptomatic imaging must be recorded in an organized manner with the goal that the clinician can think about photos of a patient from different courses of events.

Reports of a patient's medicinal record must comprise of an ongoing, applicable history, advance notes and fundus photos delineating and supporting the significant conclusion. The photographs should be marked properly, for example, which eye, the date, and patient subtleties. The patient's records should contain archived results of the fundus photography as well as a portrayal of varieties from past photos.

30 fundus images have been collected from local eye clinic and some have been obtained from online database STARE, DRIVE. 15 belong to patients suffering from Hypertensive Retinopathy while 15 images of healthy patients have been collected for the testing of the algorithm.

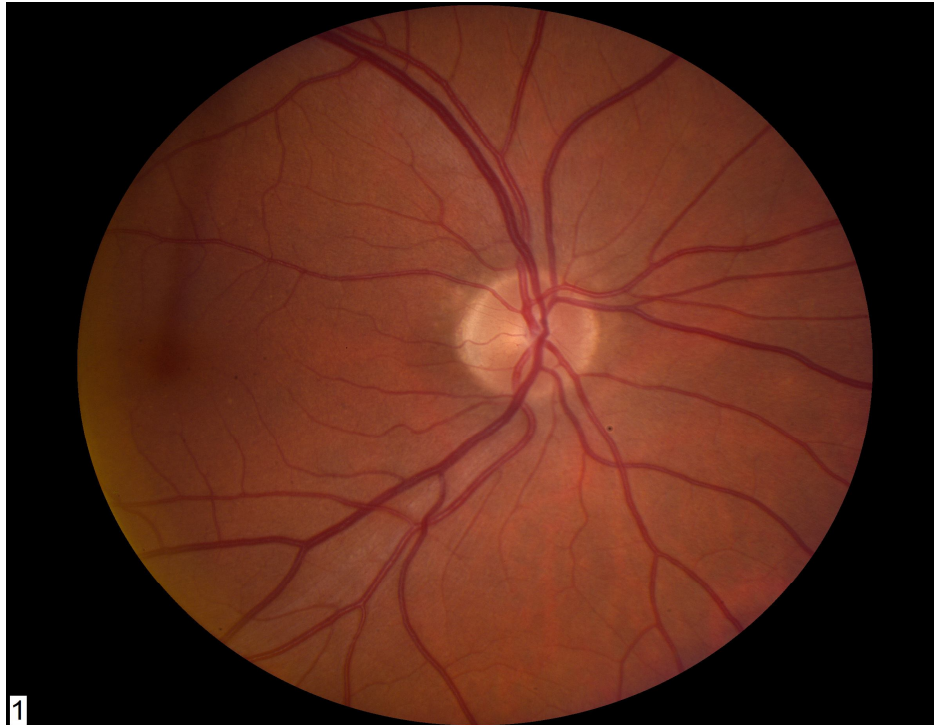

Fig. 1 A sample fundus image.

IV. PROPOSED IDEA

Preprocessing of pictures is first step and needed on the grounds that during the procedure of capturing the retinal image from a fundus camera, the brightness of the picture isn't uniform, so decrease of the conflicting brightening is a must. This will be done by using contrast limited Adaptive Histogram Equalization. Since the arteries and the veins become more separate in the green band of the image [7] [8] [9]. The original image is converted to the green channel to detect only the vessels as the background subtraction becomes easier in the green channel. The Vessels are detected using Otsus method. Once the vessels are separated, the following step is to separate out the arteries and the veins [10] [11]. The branch junction are detected and subtracted from the vessel detected image. The image is then divided into square sections. In order to do this the image is first converted into binary vessel image. Since the vessel coordinates has one as their pixels values, few columns are given zero values. Hence these would include pixel columns containing the vessels. The conversion of these values will separate the vessel paths. Each of these sections may contain one or more than one vessels [12] [13]. Each of the vessels in such sections is considered in any order. Since arteries are lighter than veins, they have less intensity and subsequently they have more values in their pixel coordinates as shown in figure 2. Similarly veins are darker as compared to arteries and hence have less pixel values in the coordinates they lie. Under the same coordinate of the original image, the point of the edge can stored to check for the diameter [15] [16]. This is because under the same horizontal coordinate roof, veins will have higher caliber at that point on its edge compared to the point on the artery edge considering both these points under the same coordinate roof as shown on figure 3.

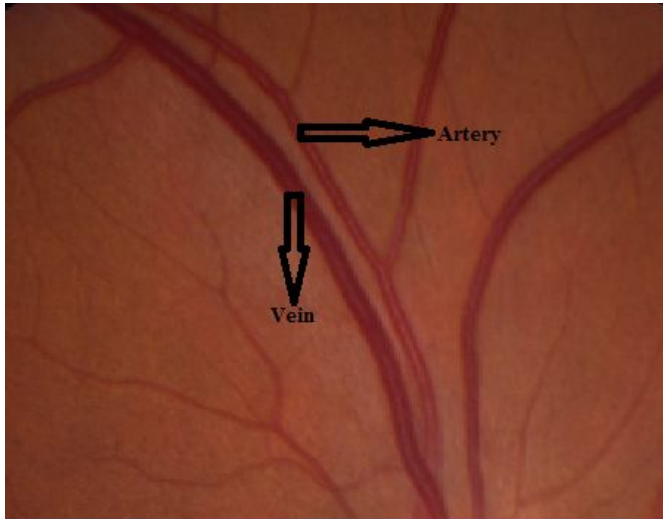


Figure 2. A section of a fundus image displaying an artery and a vein.

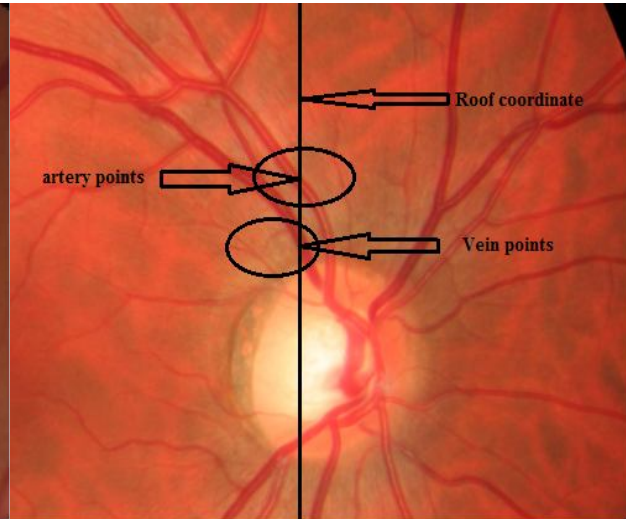


Figure 3. shows that under same line, artery will always be less than the vein.

Every section extracted is given unique number identity to identify its properties like mean width, intensity values. The mean of all the pixels values of all the coordinates of a section is calculated. The section having the least mean is a vein since veins have lower intensity values as they are darker than arteries. All the sections having the mean values around this lowest value will be termed as veins [17]. The ones having considerable difference between it and the minimum mean vein value found before will be thought of as an artery.

The boundaries of these sections are located and their coordinates are noted down. The geodesic distance is found between the points of one boundary and the points of the other boundary. Remember that during the computation of the distance between the points, the distance between the points of the same boundaries are excluded. The distance formula is not considered here as the pixel area is not equal to 1sqcm. The shortest distance from each point on the smaller edge to the all the points on the other edge is diameter width of that section at that point. Similarly all the points are calculated for the shortest distance which will be the diameter of the vessel at that point [18] [19]. Average of all the distance of all the points are taken separately for arteries and veins. The ratio is calculated.

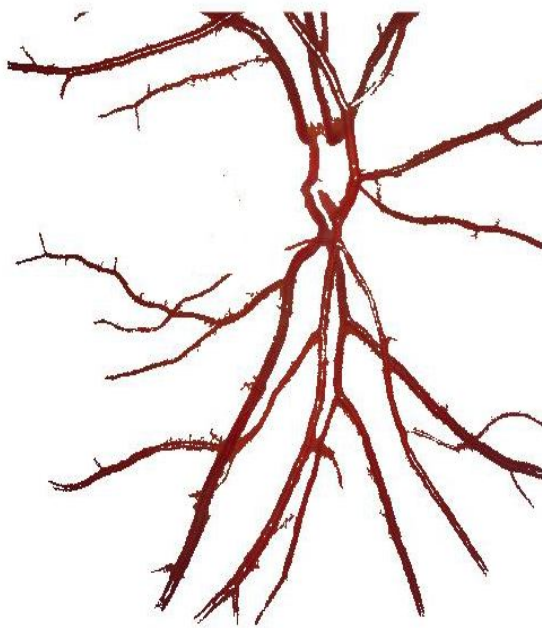


Figure 4. Vessels extracted

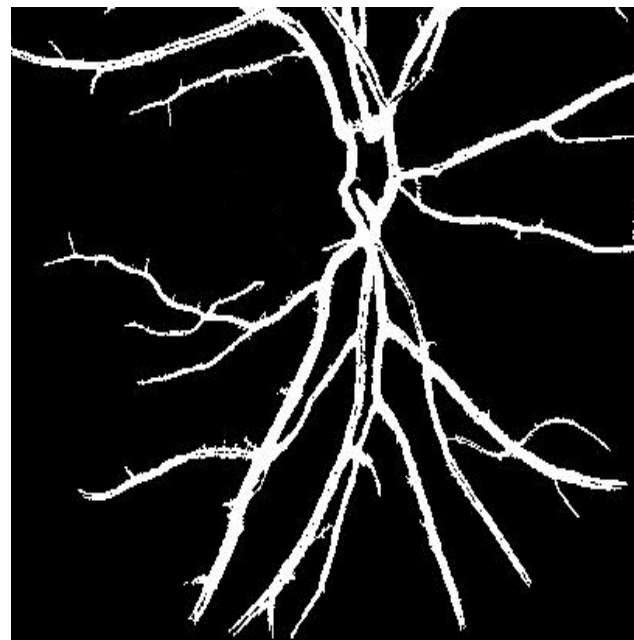


Figure 5. Vessels in binary

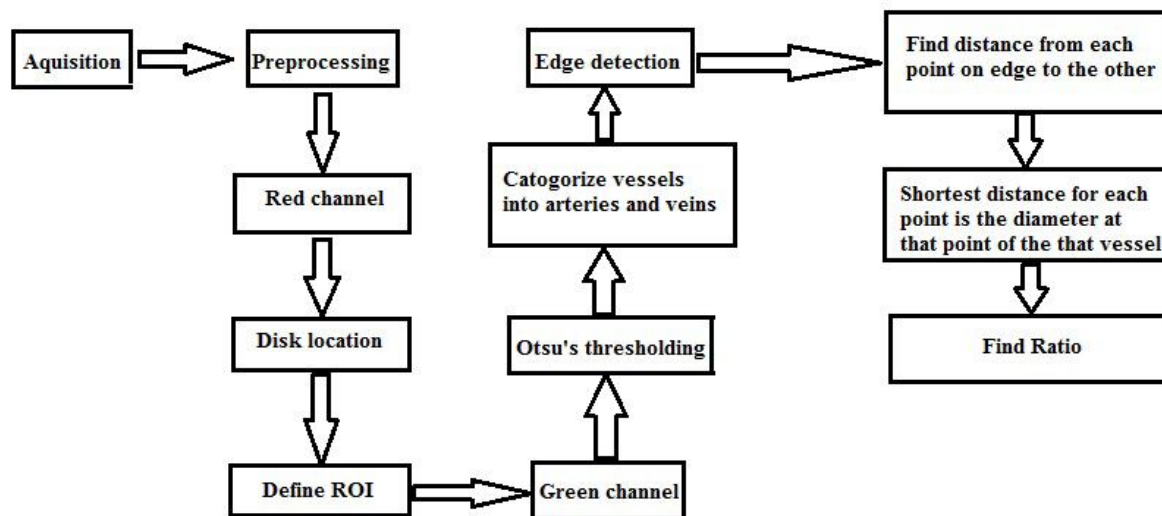


Figure 6. Showing the flowchart for the determination of AVR.

V. EXPERIMENTAL RESULTS

The A healthy patient generally have an AVR of around 0.667 whereas a HR patients has an AVR of 0.2-0.5. 12 HR Patients showed an AVR between 0.2 and 0.5 which simulate to an accuracy of 80 percent. 14 out of 15 healthy images showed an AVR between 0.667 and 0.71 which simulate the accuracy to be 93.33 percent.

VI. CONCLUSION

The simple method described will help the ophthalmologists for the early discovery of HR as the early abnormalities are found in the retinal vessels. The proposed system recorded the methods in the affirmation of AVR. These strategies could likewise recognize other different retinal diseases which demonstrate its variations vessels in the retina.

VII. ACKNOWLEDGMENT

We express my sincere gratitude towards Dr. Althea Barbosa, Eye Care Centre, Goa and Dr. Nolan De Souza, Retina eye clinic, Panaji for guiding me throughout the project. We express our gratitude towards the helpful and supportive faculty, laboratory assistants and non-teaching staff of Electronics and Telecommunication Department, Goa College of Engineering for always providing the help whenever needed.distribution.

REFERENCES

- [1] "www.healthline.com/health/hypertensive-retinopathy".
- [2] C. Kondermann, D. Kondermann and M. Yan, "Blood vessel classification into arteries and veins in retinal images," in Proc. SPIE 6512, Medical Imaging 2007: Image Processing, San Diego, CA, United States, 2007.
- [3] A. Ali, A. Hussain and W. M. D. Wan Zaki, "Vessel extraction in retinal images using automatic thresholding and Gabor Wavelet,," in 2017 39th Annual International Conference of the IEEE Engineering in Medicine and Biology Society (EMBC), Seogwipo, 2017.
- [4] C. Sinthanayothin, J. F. Boyce, H. Cook and T. H. Williamson, "Automated localisation of the optic disc, fovea, and retinal blood vessels from digital colour fundus images,," British Journal of Ophthalmology, vol. 83, pp. 902-910, 1999.
- [5] Y. Wang and S. C. Lee, "A fast method for automated detection of blood vessels in retinal images," in Conference Record of the Thirty-First Asilomar Conference on Signals, Systems and Computers (Cat. No.97CB36136), Pacific Grove, CA, USA, 1997.
- [6] K. Noronha, N. K.T and P. K. Nayak, "Support System for the Automated Detection of Hypertensive Retinopathy using Fundus Images,," in International Conference on Electronic Design and Signal Processing (ICEDSP) , 2013.
- [7] S. Nemeth, V. Joshi, C. Agurto, P. Soliz and S. Barriga, "Detection of hypertensive retinopathy using vessel measurements and textural features,," in 36th Annual International Conference of the IEEE Engineering in Medicine and Biology Society, Chicago, IL, USA, 2014.
- [8] S. Khitrana, M. U. Akram, A. Usman and U. Yasin, "Automated system for the detection of hypertensive retinopathy,," in 4th International Conference on Image Processing Theory, Tools and Applications (IPTA), Paris, 2014.



- [9] Y. G. Zhang, X. Y. Guo, L. Hu, . Q. H. Dang, D. Chen, D. Cui and Q. Jiao, "Novel Approach for Blood Vessel Edge Detection in Retinal Images," in 2nd International Conference on Biomedical Engineering and Informatics, Tianjin, 2009.
- [10] C. L. Wang, C. S. Chan, Y. K. Chan and A. S. Kuo, "Malignant Hypertensive Retinopathy Diagonising system based on Retina image," in International Journal of Advanced Computational Engineering and Networking, ISSN: 2320-2106., 2015.
- [11] A. Elbalaoui, M. Fakir, K. Taifi and A. Merbouha, "Automatic Detection of Blood Vessel in Retinal Images," in 13th International Conference on Computer Graphics, Imaging and Visualization (CGiV), Beni Mellal, 2016.
- [12] A. M. Latha, C. N. Evangeline and S. S., "Colour Image Segmentation of Fundus Blood Vessels for the Detection of Hypertensive Retinopathy," in Fourth International Conference on Biosignals, Images and Instrumentation (ICBSII), Chennai, 2018.
- [13] S. R. Nirmala and S. Chetia, "Retinal blood vessel tortuosity measurement for analysis of hypertensive retinopathy," in International Conference on Innovations in Electronics, Signal Processing and Communication, Shillong, 2017.
- [14] A. Ruggeri, E. Grisan and M. De Luca, "An automatic system for the estimation of generalized arteriolar narrowing in retinal images," in 29th Annual International Conference of the IEEE Engineering in Medicine and Biology Society, Lyon, 2017.
- [15] D. Ortíz, M. Cubides, A. Suárez and M. L. Zequera, "Support system for the preventive diagnosis of hypertensive retinopathy," in Annual International Conference of the IEEE Engineering in Medicine and Biology Society. IEEE Engineering in Medicine and Biology Society, 2010.
- [16] P. Modi and T. Arsiwalla, "<https://www.ncbi.nlm.nih.gov/books/NBK525980/>," Hypertensive Retinopathy, [Updated 2019 Jan 23].
- [17] E. Grisan, M. Foracchia and A. Ruggeri, "A Novel Method for the Automatic Grading of Retinal Vessel Tortuosity," in IEEE Transactions on Medical Imaging, 2008.
- [18] S. Irshad and M. U. Akram, "Classification of retinal vessels into arteries and veins for detection of hypertensive retinopathy," in Cairo International Biomedical Engineering Conference (CIBEC), Giza, 2014.
- [19] V. Joshi, R. M. Joseph and M. . D. Abramoff, "Automated measurement of retinal blood vessel tortuosity," in SPIE 7624, Medical Imaging 2010: Computer-Aided Diagnosis, 2010.
- [20] Helena, Sandra, Marcelo, Leila, Luciana, Vitor, Manuel and Flavio, "Computer-Assisted Methods to Evaluate Retinal Vascular Caliber: What Are They Measuring?," Investigative Ophthalmology and Visual Science, vol. 52, pp. 810-815, February 2011.



10.22214/IJRASET



45.98



IMPACT FACTOR:
7.129



IMPACT FACTOR:
7.429



INTERNATIONAL JOURNAL FOR RESEARCH

IN APPLIED SCIENCE & ENGINEERING TECHNOLOGY

Call : 08813907089  (24*7 Support on Whatsapp)