



# **iJRASET**

International Journal For Research in  
Applied Science and Engineering Technology



---

# **INTERNATIONAL JOURNAL FOR RESEARCH**

IN APPLIED SCIENCE & ENGINEERING TECHNOLOGY

---

**Volume: 7      Issue: VI      Month of publication: June 2019**

**DOI: <http://doi.org/10.22214/ijraset.2019.6352>**

**[www.ijraset.com](http://www.ijraset.com)**

**Call:  08813907089**

**E-mail ID: [ijraset@gmail.com](mailto:ijraset@gmail.com)**

# Stratification of Brain Tumor using Threshold Segmentation and Classification by CNN

Divyansh Dixit




DDI-PG Student, Department of Electronics and Communication, RGPV University, INDIA

**Abstract:** Image segmentation can be illustrated as in which we isolate the image into various parts as pixels. In segmentation, we basically address the picture into increasingly justifiable structure. Segmentation essentially is utilized to recognize the articles, boundaries and other appropriate information in the computerized pictures. This paper is a mix of two techniques segmentation and CNN based classification using MATLAB. The aim is to get higher accuracy and improved result. It is a productive technique to detect tumor at an early stage.

**Keywords:** Tumor, Segmentation, CNN, Filtration

## I. INTRODUCTION

Tumor[1] is a peculiar growth of tissues or mass which probably exist inside or on the brain. Two different terms are utilized for this anomalous and abnormal part in the brain known as tumor and cancer.

- A. Tumor and cancer are two different terms in medical science but often utilized conversely which is misleading.
- B. Tumor can be solid mass of abnormal tissues or fluid inside a solid tissue layer. In medical science Tumor is termed as neoplasm. Tumor can be inspected into essential and auxiliary tumor[2]. Primary tumor is produced using cells of that organ where tumor locates. Nervous system helps in the development of the essential tumor and its improvement is moderate. Glias cells are the structure squares of such tumor and these sorts of tumor which is identified with the sensory system are called as Gliomas.
- C. Malignancy is a snappy and wild improvement of irregular tissues which harms the contiguous wellbeing tissues of mind.
- D. Tumor is classified into Benign[3], Malignant[4] and pre-Malignant[5].
  - 1) Benign  contains has non-cancerous characteristic.
  - 2) Malignant  contains cancerous symptoms.
  - 3) Pre- malignant  has pre-cancerous attribute.
- E. The auxiliary tumor is produced using cells which live in different pieces of the body. It very well may be spread quickly. As such, it will in general be said that malignant growth cells are the explanation behind the auxiliary tumor. So, it is concluded that all tumor is not cancer, but all cancers are tumor. Tumor can be categorized based on various criteria as given below:
  - 1) Tumor confinement in skull
  - 2) Tumor confinement in brain
  - 3) Localization in compartmentOther than this, tumor is also classified based on cells which compose the tumor Like
  - a) Tumor made of neuron cells
  - b) Tumor made of glila cells
  - c) Tumor made of germs cell
  - d) Tumor made of meninges

## II. MR IMAGE CHARACTERISTICS OF BRAIN TUMOR

MRI is an imaging procedure[6] in which part of a body is scanned using strong magnetic and radio waves it is an imaging method which is comparatively much better and useful then X-ray. MR images do not utilize harmful radiations and still provides enough information for disease diagnosis[7] and decision making for the doctors. MR Images are utilized in pre-handling of brain tumor ID and finding. We utilize various kinds of MR depictions according to the necessity. T1, T2 and FLAIR are the arrangements utilized as a contribution to the preprocessing step.

- 1) TE is time of echo which is the time difference between the delivery of RF pulse and the receiving of echo signal.
  - 2) TR is repetition time which is the reception time between two continuous pulses applied in a same sequence.
- T1-weighted images [8]: contain dark appearance of CSF and fluid. Gray matter (GM) is darker than white matter (WM). T1 gives better result in the case of brain structure images and fat seems brighter in this sort. TE and TR time (TR≈500msec, TE≈14msec) is less to deliver the images (uses longitudinal relaxation).
- T2-weighted images [9]: which contain higher signal intensity of CSF and fluid as compare to tissue and for that reason it appears bright. T2 used long time (TR≈4000msec, TE≈19msec) for TE and TR to deliver images (traverse relaxation). T2 is brighter for water and fluid, ideal for the oedema tissue
- FLAIR [10] is just like to T2 but it has attenuated CSF fluid, but abnormalities remain bright. It is good for imaging the cerebral oedema. It uses very long TE and TR time (TR≈9000msec, TE≈114msec) for producing images.

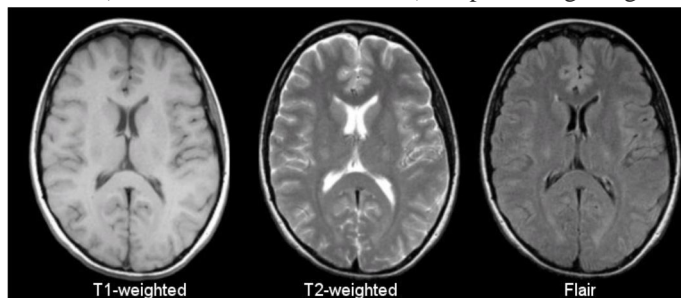


Fig.1 Tissues T1-weighted T2-weighted FLAIR

### III. IMAGE FILTRATION AND DE-NOISING

Image filtration and de-noising is the introductory step in achieving our target. This step includes certain restoration methods to reduce additive noises which are induced in images while acquisition, transmission or compression operation. Filtration of image enhances the nature of image and ensures better processing and accurate results.

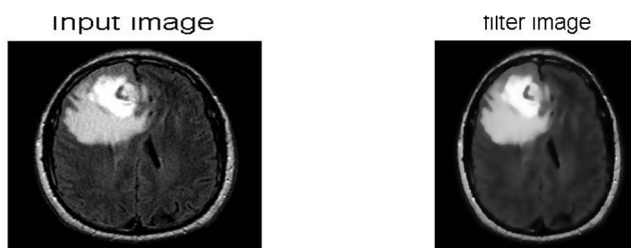


Fig.2 Example of noisy image and de-noisy image

### IV. CLASSIFICATION USING CNN

Convolution neural system is prepared on set of 600 pictures to arrange tumor influenced pictures. CNN contains two layers which are info layer, yield layer and different shrouded layers. Convolution layers apply a convolution movement to the data, passing the outcome to the accompanying layer. The convolution imitates the reaction of a lone neuron to visual lifts.

#### A. Structure of CNN In Layers

- 1) *Convolution Layer*: Convolution is the primary layer to excerpt features from an input image. Convolution safeguards the connection between pixels by learning image features by utilizing little squares of input information.
- 2) *Pooling Layer*: Pooling layers section would decrease the quantity of parameters when the images are excessively large. Spatial pooling additionally called sub sampling or down sampling scale down the dimensionality of every map however holds the important information.
- 3) *Relu Layer*: ReLU represents Rectified Linear Unit for a non-linear operation. The yield is  $f(x) = \max(0, x)$ . ReLU layer is important as its motive is to introduce non-linearity in ConvNet.

### V. PROPOSED METHODOLOGY

Image analysis system provides an efficient approach to evaluate the medical image and detect the abnormalities of those images. This analysis system will able to reveal more possible aspect of images by applying the grey scaled segmentation with the advance classification technique of neural network which is CNN (convolution neural network). This experiment provides the best combination for image analysis system. The proposed work is segregated into two parts. First is pre-processing and second is post pro-processing. Dataset of brain MR Images are using as an input. For the implementation 10 brain MRI images are utilized which also contain non-tumor and tumor affected images. The format of downloaded images is in .jpeg format and it can be easily used by Mat-lab environment.

#### A. Pre-Processing

In the first part, the input of MR Images is picked from database.

- 1) *Step 1:* Apply filtration (by using Mat lab command) process on images to minimize the commotion from the image
- 2) *Step 2:* Check the quality of image. If quality of image is not good, then reject that image and pick another image from database. If yes, then further processing is started and Move to the next part.

#### B. Post Processing

- 1) *Step 1:* The result of the previous step is used as an input of the post-processing part.
- 2) *Step 2:* The filtered image is preceded for the threshold segmentation by Mat-lab command
- 3) *Step 3:* The process of resizing image into 200 X 200 image matrix.
- 4) *Step 4:* Move image for classification
- 5) *Step5:* convolution neural network technique is classified the image into tumor part and non - tumor part.
- 6) *Step6:* If image contain tumor then move for further process of computing area.

#### C. Area Calculation

- 1) *Step7:* Classified tumor section of depiction is using as an input
- 2) *Step8:* Convert the image into pixels
- 3) *Step9:* Compute numbers of rows and column in pixels by  $[r2\ c2] = \text{size}(I)$
- 4) *Step4:-* Initialize a variable  $a=0$
- 5) *Step4:-* For  $I=1:1:r2$  do
- 6) *Step4:-* For  $j=1:1:c2$  do
- 7) *Step4:-* If  $I(i,j) == 255$  do
- 8) *Step4:-*  $a=a+0$
- 9) *Step4:-* Else do
- 10) *Step4:-*  $a=a+1$
- 11) *Step4:-* End IF
- 12) *Step4:-* End For
- 13) *Step4:-* End For
- 14) *Step4:-* Display the area.

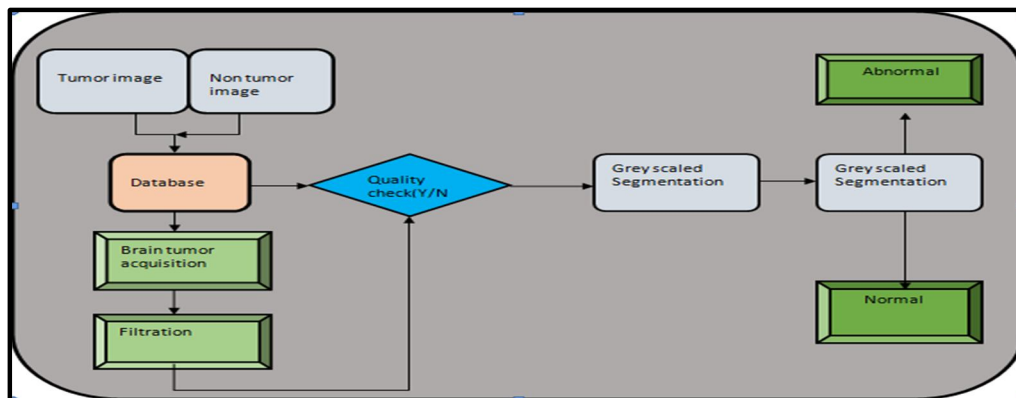
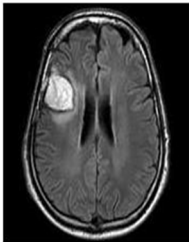
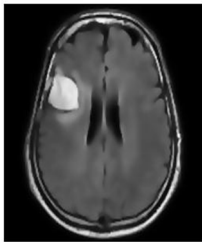

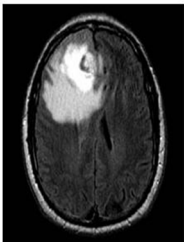
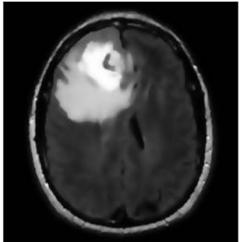


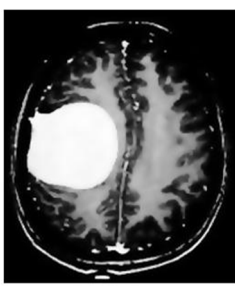

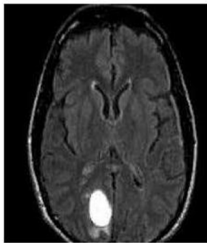
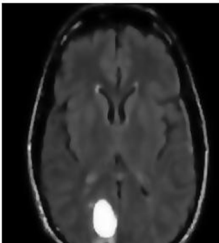



Fig.3 Graphical Representation of Proposed work

**VI. RESULT**

S.No	Input Image	Filter Image	Tumor Alone	Tumor Size
Bt1				2230
Bt2				6634
Bt3				8602
Bt4				2164

### CONCLUSION AND FUTURE RECOMMENDATION

In this dissertation, an experiment has been conducted to detect the lump from the MR depictions. Image percolation has been utilized to intensify the nature of image, next step is image segmentation which has given better outputs of the image and the result of the segmentation is used as an input image to the classification process. As well as the survey is conducted of different techniques which are used for the purpose of categorization of brain tumor MR images.

Dataset comprises of 10 pictures of tumor and non-tumor. In this examination, a model has been proposed for the effective tumor discovery of cerebrum MR pictures. Following advances are received for identification.

- 1) *Step 1:* taking input image.
- 2) *Step 2:* filter image.
- 3) *Step 3:* segmentation of MR image by gray scaled technique.
- 4) *Step 4:* Apply classification technique of convolution neural network to detect the tumor from brain MR images. Accuracy of the classification is 87% which is calculated by way of the formula.
- 5) *Step 5:* last task is to compute the area of the identified image by algorithm.

#### A. Future Recommendation

Analysts are expected to offer thoughtfulness regarding escalate the system of tumor affinity by utilizing the distinctive type of neural system. It is interested to investigate the conduct and consequence of the diverse type of neural system like ANN, CNN, PNN, DNN and basic neural system by utilizing more modest number of named pictures to perform well. Various parameters would be utilized for this examination like exactness, time, particularity, productivity and numerous others. There is having to present a computerized master framework which can distinguish the tumor at its previous stage with the goal that a superior arranging could be sorted out for treatment.

### REFERENCES

- [1] Tom M., Rolf B., Ole D.L., and Mark L.R., Brain tumor invasion: biological, clinical, and therapeutic considerations, Copyright 1998 by Wiley-Liss, Inc.
- [2] Thompson P.M., Moussai J., Zohoori S., Goldkorn A., Khan A.A., Mega M.S., Small G.W., Cummings J.L., Toga A.W., "Cortical variability and asymmetry in normal aging and Alzheimer's disease". *Cereb Cortex*. 8(6), 492-509, 1998.
- [3] Pàez-Ribes, Marta, et al. "Antiangiogenic therapy elicits malignant progression of tumors to increased local invasion and distant metastasis." *Cancer cell* 15.3 (2009): 220-231.
- [4] Begin, Michel E., et al. "Differential killing of human carcinoma cells supplemented with n-3 and n-6 polyunsaturated fatty acids." *Journal of the National Cancer Institute* 77.5 (1986): 1053-1062.
- [5] Ru B, Wang X, Yao L. Evaluation of the informatician perspective: determining types of research papers preferred by clinicians. *BMC Med Inform Decis Mak*. 2017;17(S2). doi:10.1186/s12911-017-0463-
- [6] Vaidyanathan M., Velthuizen R., Clarke L.P., Hall L.O., "Quantitation of brain tumor in MRI for treatment planning". *Proc. the 16th Annual International Conference of the IEEE on Engineering in Medicine and Biology Society*, 1, 555 -556, 1994.
- [7] Vezina G., "MR Imaging of Brain Tumors - Recent Developments". M.D Director of Neuroradiology - Children's National Medical Center, Washington D.C.
- [8] Werring, David J., et al. "Cognitive dysfunction in patients with cerebral microbleeds on T2\*-weighted gradient-echo MRI." *Brain* 127.10 (2004): 2265- 2275.
- [9] Hajnal, Joseph V., et al. "Use of fluid attenuated inversion recovery (FLAIR) pulse sequences in MRI of the brain." *Journal of computer assisted tomography* 16.6 (1992): 841-844.
- [10] Kato, Hiroyuki, et al. "Silent cerebral microbleeds on T2\*-weighted MRI correlation with stroke subtype, stroke recurrence, and leukoaraiosis." *Stroke* 33.6 (2002): 1536-1540.



10.22214/IJRASET



45.98



IMPACT FACTOR:  
7.129



IMPACT FACTOR:  
7.429



# INTERNATIONAL JOURNAL FOR RESEARCH

IN APPLIED SCIENCE & ENGINEERING TECHNOLOGY

Call : 08813907089  (24\*7 Support on Whatsapp)