



iJRASET

International Journal For Research in
Applied Science and Engineering Technology



INTERNATIONAL JOURNAL FOR RESEARCH

IN APPLIED SCIENCE & ENGINEERING TECHNOLOGY

Volume: 7 Issue: XI Month of publication: November 2019

DOI: <http://doi.org/10.22214/ijraset.2019.11087>

www.ijraset.com

Call:  08813907089

E-mail ID: ijraset@gmail.com

Toxicological Investigation, Physico-Chemical Determination and Histopathological Changes of Paint Effluent against *Tympanotonus Fuscatus* Var *Radula*

Beatrice O. Edeghagba¹, Frances N. Jolly², John O. Ajipe³, Oluwadara D. Babatunde⁴

¹Environmental biology unit, Department of Biological Science, Yaba College of Technology, P. M. B 2011, Yaba, Lagos.

Abstract: Water pollution as a result of discharge of untreated industrial effluents into water bodies has now become a global problem. Acute and chronic toxicity testings were carried out on paint effluent against *Tympanotonus fuscatus* var *radula* and histopathological examination was used in assessment. The Paint effluent was obtained from President Paints Limited, Atan, Ogun State while the periwinkles were handpicked from the mud flat area of the University of Lagos lagoon front. Acute toxicity test was done using varying concentrations (300, 400, 500, 600 and 700ml) of the paint effluents for 96 hours and the mean mortality was calculated using one way analysis of variance (ANOVA). Physicochemical parameters of the paint effluent were determined following APHA standard methods for examination of water and wastewaters. Heavy metal levels were detected using the Atomic absorption spectrophotometer (SOLAR SERIES S2). The result obtained for these parameters were compared with WHO and NESREA permissible limits. All parameters complied with the standard regulatory limits except for the DO ($1.80 \pm 0.02 \text{mg/L}$), Phosphate ($229.85 \pm 3.05 \text{mg/L}$), BOD ($132.00 \pm 4.00 \text{mg/L}$) and TSS ($154.50 \pm 2.50 \text{mg/L}$) which were not in conformity with WHO and NESREA guidelines respectively. However, for the metals, zinc had the highest value of $0.1790 \pm 0.0020 \text{mg/L}$ in the effluent while cadmium and chromium were not detected. The 96-h LC_{50} value obtained was 7.51ml and this low value indicated that the effluent was very toxic. Histopathology examination on the whole tissue of the organism exposed to the paint effluent revealed partially destructed digestive tract and foot muscles with several aggregates of inflammatory cells. This result revealed the harmful and toxic effect of the paint effluent on the periwinkles and as such, proper treatment before discharge to the environment is encouraged.

Keywords: Toxicity, Physico-chemical, Histopathology, Paint effluent, *Tympanotonus fuscatus* var *radula*

I. INTRODUCTION

Water pollution due to discharge of untreated industrial effluents into water bodies has now become a global problem (Nwakanma and Oleh, 2013). Industrial wastewater originates from the wet nature of most industries which require large quantities of water for processing and disposal of wastes. The pollution of the environment due to industrial wastewater depends on the activities of the industries, such as its process technology, their concentration through utility use, contaminants added in the process operation, nature of raw materials and process methodology (Kanu and Achi, 2011).

Wastewater is estimated to be made up of more than 95% water with small amounts of dissolved or suspended solid matters (USEPA, 2006). The quality and quantity of wastewater has been proven to be responsible for the deterioration of the receiving water bodies such as lakes, oceans, rivers, lagoons, among others. Parameters of concern are their physico-chemical properties such as nitrates and sulphide along with Biological Oxygen Demand (BOD), Chemical Oxygen Demand (COD), Total suspended solids (TSS), presence of metals etc. (Akpoy and Muchie, 2011).

In Nigeria, so many industries exist yet some of these industries do not have wastewater treatment facilities, and as such these industrial effluents have hazardous effects on water quality, habitat quality, and complex effects on flowing waters (Ethan *et al.*, 2003). Several efforts are being put in place by regulating bodies such as the National Environmental Standards and Regulations Enforcement Agency (NESREA) in Nigeria to ensure that industries all around the country comply with the standards set up by World Health Organization (WHO).

Pollution of the environment by paint industry is the major cause of water pollution. They do so through effluent discharge, gas emission and waste disposal in the form of organic and inorganic substances and hence, the removal of these toxic pollutant from

the effluent before discharging it into the environment and from raw material before public use is important and essential for the protection of human health and the environment as a whole (Iheoma *et al.*, 2015). In Lagos, Nigeria, there are many industries that discharge their effluents into the different water bodies around the metropolis (Samuel *et al.*, 2010). The paint industries, which constitute one of the major industries in Lagos is of particular interest because it discharges large amount of effluent than other industries in the metropolis (Samuel *et al.*, 2010). Wastewater from paint industries is generated basically from cleaning operations of mixers, reactors, blenders, packing machines and floors (Aboulhassan *et al.*, 2014). The effluent has high organic and inorganic toxic pollutants as a result of varying degree of chemicals used. The waste water from paint industries contains serious concentrations of biological oxygen demand (BOD) or chemical oxygen demand (COD), toxic compounds, colour and suspended solids (Aboulhassan *et al.*, 2006), but the contaminants under greatest regulatory scrutiny are total suspended solids, heavy metals, biological oxygen demand (BOD) and chemical oxygen demand (COD).

Histopathological changes have been used greatly as biomarkers by researchers in the evaluation of the health of fish and other aquatic organisms exposed to contaminants, both in the laboratory and field studies. One of the main advantages of using histopathological biomarkers in environmental monitoring is that it allows for the examination of specific target organs such as gills, kidney and liver, that are responsible for vital functions, such as respiration, excretion and the accumulation and biotransformation of xenobiotic in fish (Gernhofer *et al.*, 2001). Consequentially, histopathological studies are performed to evaluate the direct effects of contaminants on fish and any other experimental animal in laboratory bioassays (Drishya *et al.*, 2016).

Oladele *et al.*, (2018) carried out histopathological examination on the tissues of swiss albino mice (*Mus musculus*) treated with paint effluent. The result showed severe necrosis and fibromatosis colli of the kidney, hepatic necrosis of the liver, lung atrophy, tubular atrophy of the heart, loss of myocardial striation, tubular atrophy of the heart and tissue hyalination due to concentrations of the paint effluent. The result of his study showed that the paint effluent was harmful to the mice.

Periwinkle species (*Tympanotonus fuscatus* var *radula*) is a common name for a group of molluscan shell fish that has an elongated shell with regular increasing whorls, no spiny tubercle on the shell and much fine striation with blackish brown stripes on the shell (Moruf, 2015). It is a good bio-indicator for bio-monitoring of pollution because it has the ability to accumulate pollutants like heavy metals, polycyclic aromatic hydrocarbons and Polychlorinated biphenyls without being killed by the levels encountered in the environment; sedentary habit in order to be representative of the study area, sufficiently long lived to allow the sampling of more than one year-class. Also, if desired: be of reasonable size, giving adequate tissue for analysis (Moslen *et al.*, 2017).

The aim of this research, therefore, is to carry out further histopathology examination on the whole tissues of *Tympanotonus fuscatus* var *radula* exposed to paint effluent.

II. MATERIALS AND METHOD

A. Study Area

The study area was the Lagos Lagoon located in Lagos State, Nigeria. The lagoon lies between $6^{\circ} 22'N$ and longitude $3^{\circ} 23'E$ with a maximum length of 50km and 13km width. The specified sample site was the University of Lagos Lagoon front ($6^{\circ} 30'N$ and $3^{\circ} 23'E$) and its co-ordinates were taken using the Global positioning Application on a mobile phone (Figure 1A) The Lagos Lagoon is used for transportation and fishing both commercially and locally by its inhabitants and as such it aids economic activities.

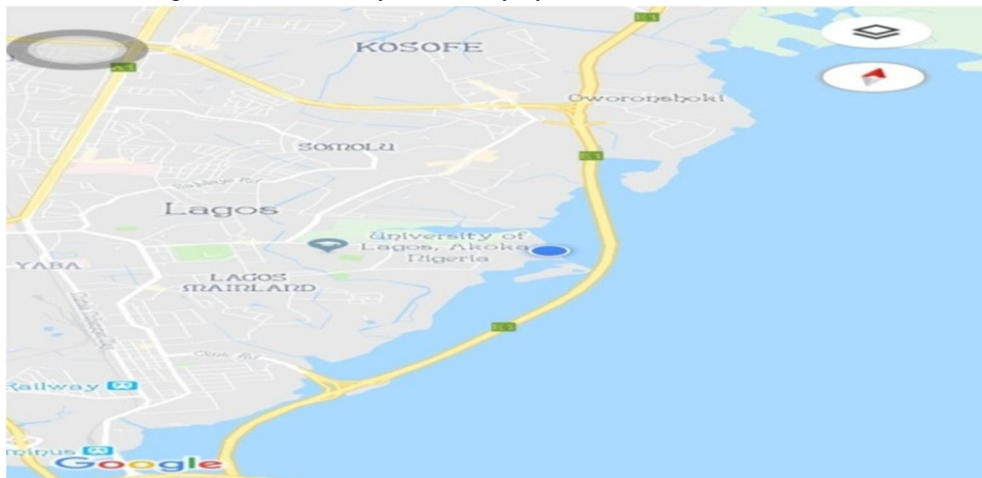


Figure 1A: Map of Study Area.

B. Collection and Acclimatization of Test Organism

Periwinkles (*Tympanotonus fuscatus var radula*) were collected from the mud flat area of University of Lagos Lagoon front. The collection was done in the morning (7- 9am) to avoid heat stress. The organisms were placed in a fresh polyethylene bag and was transported to Environmental Biology Laboratory of Yaba College of Technology for acclimatization. In the laboratory, the organisms were transferred from the polyethylene bag into a clean transparent plastic container with a lid fitted with net, and containing sediment which served as food substrate for the test organisms. The periwinkles were acclimatized for seven days at room temperature during which the lagoon water from source was used to wet their shells whenever they were dry.

C. Collection of Paint Effluent

The paint effluent used in this study was obtained from President Paint Limited, Atan, Lagos state, at the discharge point of the factory towards the terminal end via a pipe.

D. Instrumentation

Sensitive Weighing balance (Top loading balance), Atomic absorption spectrophotometer (SOLAR SERIES S2) for heavy metal analysis, Dissolved oxygen (DO) meter (DO-5509 model) in mg/L was used to measure the dissolved oxygen. Hydrogen ion (pH) concentration was determined using a pocket sized pH meter (pH-1 model). Electrical conductivity was measured with the aid of Hannah conductivity meter (BM-211 model).

E. Physico-chemical Parameters of Paint Effluent.

The paint effluent was analysed for physico-chemical parameters such as pH, alkalinity, conductivity, Total dissolved solids (TDS), Total suspended solids (TSS), Total solids (TS) phosphate, sulphates, chlorides, nitrates, biological oxygen demand (BOD), dissolved oxygen (DO) and chemical oxygen demand (COD). The levels of some heavy metals such as arsenic (As), lead (Pb), chromium (Cr), copper (Cu), zinc (Zn), cadmium (Cd) and mercury (Hg) were also determined using Atomic absorption spectrophotometer (SOLAR SERIES S2). Analysis was done in order to quantify the concentrations of the metals and other parameters in the paint effluent using the APHA (2005) standard method for examination of water and wastewaters. The analysis were carried out at the biochemistry laboratory, Biochemistry department of Lagos University Teaching Hospital (LUTH), Idi-Araba, Lagos State. The mean values obtained for the analysis were calculated using one way Analysis of Variance (ANOVA). Mean data were presented as Mean±Standard deviation. Furthermore, the values were compared with WHO and NESREA standards.

F. Range Finding/ Preliminary Test

After acclimatization, range finding or preliminary test was conducted in order to determine the definitive concentrations to be used for the acute toxicity test. This test was conducted using varying concentrations of the paint effluent (200ml, 300ml, 400ml, 500ml and 600ml). The effluent was standardized with the lagoon water to 1000ml and in the control experiment, no toxicant was added. 10 healthy species of the test organisms were introduced into each of the six bioassay container, each with 20g of sediment. The setup was in replicates and it was allowed to stand for 96hours. Observations were taken at 24hour interval.

G. Bioassay Test Procedure

The bioassay was carried out in 12 sterile plastic containers. The sediment used as substrate was collected from the same source (Figure 1A) in which the test organisms were collected. Using sensitive weighing balance, 20g of the sediment was weighed into each bioassay container. Healthy test organisms of the same size and length were selected for the bioassay. The weight and length of the selected organisms were also determined prior to experiment. The selected organisms were transferred from the acclimatization tank into the bioassay container using plastic bowl and spoon.

1) *Acute Toxicity Test:* The test media were prepared in different concentrations of 300ml, 400ml, 500ml, 600ml and 700ml and they were standardized to 1000ml using water from source. In the control experiment, no toxicant was added. About 20 healthy species of the test organism of the same size were introduced into each of the six different bioassay tanks. All the experiments were set up in replicates. All tests were conducted for a period of four days under laboratory conditions. Mortality assessment was carried out at definite intervals of 24, 48, 72 and 96 hours. The periwinkles were ascertained dead if they had completely retracted into the shell or if it failed to respond to prodding with a glass rod for a period of 15 minutes. Dead periwinkles were removed immediately and then its mortality recorded.

- 2) **Chronic Toxicity Test:** The test media was prepared in the different concentrations of the effluent with fractions of 96-h LC₅₀ value (7.51ml) obtained from the probit analysis (Odiere, 1999). The test media were prepared from the different sub-lethal concentration of 1.8ml, 0.50ml, 0.20ml, 0.13ml and 0.10ml and they were standardized to 1000ml with water from source. The control experiment was standardized with no toxicant added. 25 healthy periwinkles of the same sizes were introduced into each of the six bioassay tanks. The organisms were exposed to the paint effluent at sub-lethal concentrations of 0.00 for control and 1.8, 0.5, 0.2, 0.13 and 0.1ml for 14days. A renewal bioassay test for 48 hour was employed throughout the duration of the experiment experimental.
- 3) **Data Analysis:** Descriptive statistics (mean and standard deviation) was used on the data obtained for the physico-chemical parameters and heavy metals of the paint effluent. The mean values obtained were calculated using one way Analysis of Variance (ANOVA) and mean data were presented as Mean±Standard deviation.

Toxicological dose-response data involving quantal response for mortality assessments were analysed via probit using Stat graphics version 16.0. The indices derived from this analysis were:

LC₅₀ = Median lethal concentration at each exposure time that caused 50% mortality of exposed organisms and their 95% confidence limit

LC₅= Sublethal concentration at each exposure time that caused 5% mortality of exposed organisms and their 95% confidence limits (CL)

TF= Toxicity factor for relative potency of measurements, that is, the 96-h LC₅₀ of the test compound against the test organism.

Mean mortality were calculated using Analysis of Variance (ANOVA) and were presented as Mean±Standard deviation.

H. Histopathology Examination

At the end of the chronic exposure period, the periwinkle, *T. fuscatus var radula* were randomly selected from each concentration for histopathological examinations. The tissues were carefully removed from the shell and were carefully isolated from the control and experimental test animals. The tissues were rinsed in normal saline, placed in universal bottles and fixed in 10% buffered normal saline to prevent putrefaction and autolysis. The tissues were transported to the histopathology main laboratory at the Anatomic and Molecular pathology department of the Lagos University Teaching Hospital (LUTH), Idi-Araba, Lagos state, for examination. The fixed tissues were preserved for 5-10hours. Thereafter, were placed in different grades of alcohol (70%, 90% and 95%) in order to completely remove water from the fixed tissue. The dehydrated tissues were cleared with xylene at different levels to eliminate any extra alcohol from the tissues. The tissue samples were impregnated in molten paraffin wax at 60°C. The samples were embedded into molten paraffin blocks. Each of the blocks was placed on the rotary microtome and the sections were cut at 4 microns, after which they were gently placed on well labeled slides and with the aid of a curved floating forceps, the sections were floated on a hot water bath at a temperature of 45°C and prepared for proper adhesions of the tissues to the microscope slides. The slides were subsequently dried on hot air oven at a temperature of 60°C. The haematoxylin and Eosin technique were employed in the staining of the prepared slides.

III. RESULTS

A. Physical Parameters of Paint Effluent.

The result of the physical parameters obtained in the paint effluent (Table 1A) showed that the Total solids had the highest concentration, followed by Electrical conductivity, Total dissolved solids, Total suspended and pH respectively. Results of these parameters were compared with WHO and NESREA standards for permissible limits. The levels of pH, Total dissolved solids (TDS), Total solids (NESREA no value given) and Electrical conductivity (NESREA no value given) of the effluent were within WHO and NESREA permissible limits while the concentration of Total suspended solid exceeded the WHO and NESREA permissible limits (Table 1A)

Table 1A: Physical Parameters of the Paint Effluent

Parameters	Concentrations	WHO	NESREA
pH	6.75 ± 0.05	7.0 – 8.5	6.0 – 8.0
TS (mg/L)	480 ± 4.50	500	-
TSS (mg/L)	154.50 ± 2.50	30	100
TDS (mg/L)	231 ± 3.00	<2000	1200
Conductivity (ms/cm)	465.50 ± 2.50	7000	-

B. Chemical Parameters of Paint Effluent

The result for the chemical parameters in the effluent followed the sequence phosphate > biological oxygen demand (BOD) > chemical oxygen demand (COD) > sulphates > chloride > alkalinity and > nitrate respectively in decreasing order of magnitude. Similarly, the results determined were compared with WHO and NESREA standards for permissible limits (Table 1B). The concentrations of nitrate, chloride, sulphate, chemical oxygen demand (COD) and alkalinity of the effluent complied with the WHO and NESREA regulatory limits while the concentrations of phosphate and biological oxygen demand (BOD) in the paint effluent were in hundreds of fold higher than the WHO and NESREA limits. The concentration of dissolved oxygen (DO) did not conform with the permissible limit of 5mg/L for WHO, however, no value was indicated by NESREA (Table 1B)

Table 1B: Chemical Parameters of the Paint Effluent

Parameters	Concentrations	WHO	NESREA
DO (mg/L)	1.80 ± 0.02	5	-
BOD (mg/L)	132.00 ± 4.00	20	50
COD (mg/L)	43.07 ± 0.70	200	100
Nitrate (mg/L)	6.32 ± 0.09	10	10
Sulphate (mg/L)	163.03 ± 1.73	200	500
Phosphate (mg/L)	229.85 ± 3.05	5	10
Alkalinity (mg/ L)	8.90 ± 0.03	200	-
Chloride (mg/L)	9.89 ± 0.26	250	500

C. Heavy Metal Concentration of the Paint Effluent

Table 2 shows the results of the seven heavy metals analysed with zinc having the highest value in the paint effluent followed by copper, lead, mercury and arsenic respectively. However, cadmium and chromium were not detected in the paint effluent. Generally, the concentrations of all metals determined were in conformity with the NESREA and WHO standards (Table 2).

Table 2: Heavy Metal Concentration of the Paint Effluent

Heavy metals	Concentrations	WHO	NESREA
Arsenic (ppm)	0.0021 ± 0.0002	0.1	0.2
Cadmium (ppm)	ND	0.01	0.1
Chromium (ppm)	ND	0.05	1.0
Copper (ppm)	0.0500 ± 0.0012	1.0	1.0
Mercury (ppm)	0.0036 ± 0.0002	0.001	0.01
Lead (ppm)	0.0130 ± 0.0001	0.2	0.1
Zinc (ppm)	0.1790 ± 0.0020	5	5

ND: Not detected

D. Mean Mortality of *T. Fuscatus var Radula* in Different Concentrations of the Paint Effluent after Acute Exposure for 96 Hours

Results in Table 3 revealed that mortality occurred after 48, 72 and 96 hours of exposure in the different concentrations. The highest mean mortality (40%) was recorded at exposure time in 600ml and 700ml for *T. fuscatus var radula* accordingly. Also, it was shown that the periwinkles exposed to 600ml and 700ml concentration of the paint effluent had the same percentage mortality after 96 hour of exposure of 40%.

Table 3: Mean Mortality of *Tympanotonus fuscatus* var *radula* in Different Concentrations of the Paint Effluent after Acute Exposure for 96 hours

Concentrations (%)	Duration (hours)				Percentage Mortality
	24 hours	48 hours	72 hours	96 hours	
300	1.00±0.00 ^{ab}	2.50±0.71 ^{ab}	3.00±0.00 ^{ab}	6.00±1.41 ^a	30%
400	1.00±1.41 ^a	2.50±0.71 ^a	3.50±0.71 ^a	6.00±2.83 ^{ab}	30%
500	0.00±0.00 ^a	1.00±1.41 ^a	2.50±2.12 ^a	4.00±2.83 ^a	20%
600	0.50±0.71 ^{ab}	3.00±2.83 ^{ab}	4.00±1.41 ^a	8.00±1.41 ^a	40%
700	1.00±1.41 ^a	4.00±4.24 ^a	5.50±3.54 ^a	8.00±1.41 ^a	40%

E. Histopathology Changes

On examining the tissues of *T. fuscatus* var *radula* exposed to the paint effluent, results revealed that the effluent was toxic and harmful to the organism. The tissues exposed to 1.8ml and 0.1ml concentrations respectively (Figures 3 and 7) showed partially destructed digestive tract with presence of few aggregates of inflammatory cells. Figure 5 showed large fatty vacuoles with areas of shrinkage and degeneration of tubule cells. The tissues exposed to 0.1ml (Figure 7) revealed partially destructed digestive tract with presence of few aggregates of inflammatory cells, there were areas of shrinkage and degeneration of tubule cells, areas of necrosis, and large fatty vacuoles. Also, the tissues exposed to 0.5ml and 0.13ml concentrations of the Paint effluent showed partially destructed foot muscle with presence of several aggregates of inflammatory and the digestive tract is not seen. The basophilic portion with nucleus and the acidophilic cytoplasm of the acinar cells are seen. There are areas of shrinkage and degeneration of tubule cells, areas of necrosis, and few fatty vacuoles (Figure 4 and 6 respectively). However, none of these anomalies were detected in the control tissues (Figure 2). The control tissues showed normal foot muscle, internal organs, basophilic portion with nucleus and the acidophilic cytoplasm of the acinar cells.

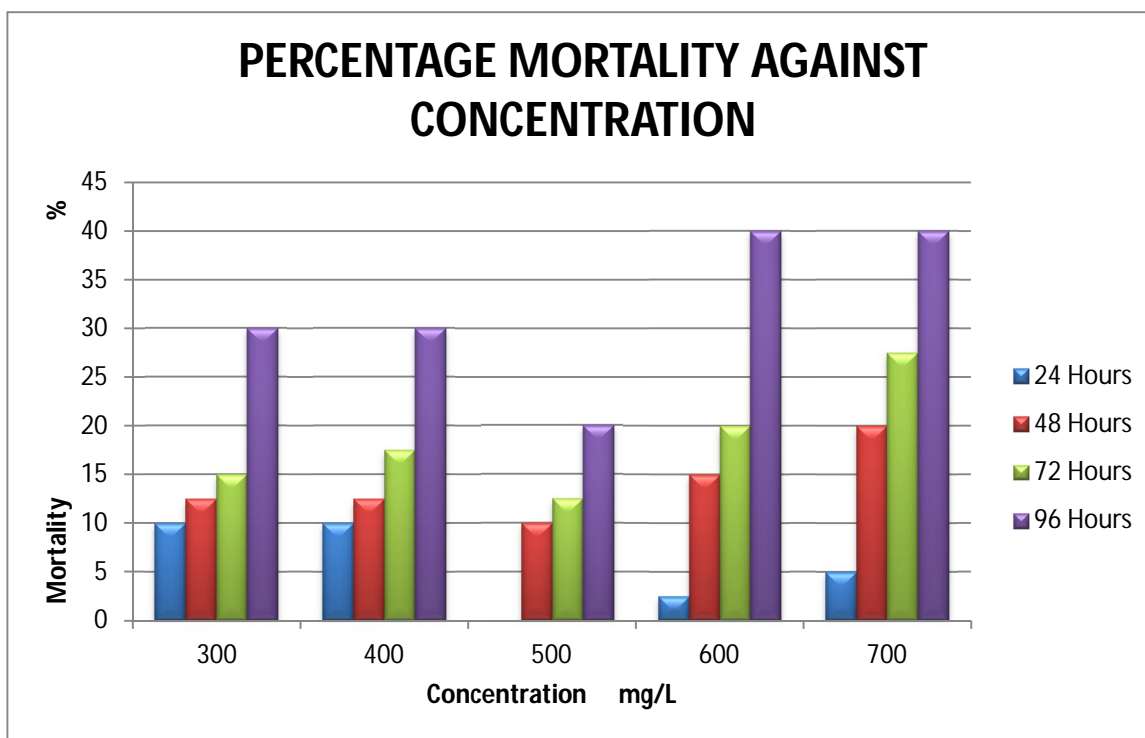


Figure 1B: Percentage Mortality against Concentration

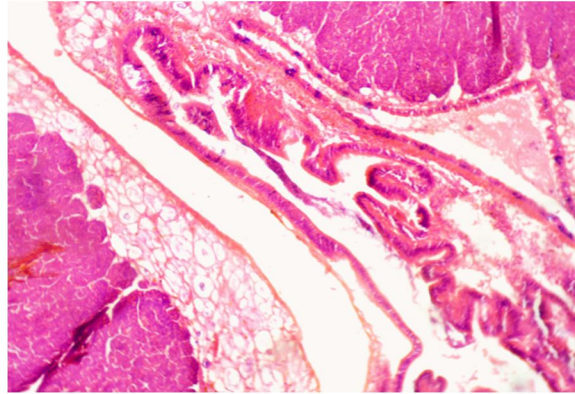


Figure 2: Control microphotograph of the tissue of *Tympanotonus fuscatus var radula*.

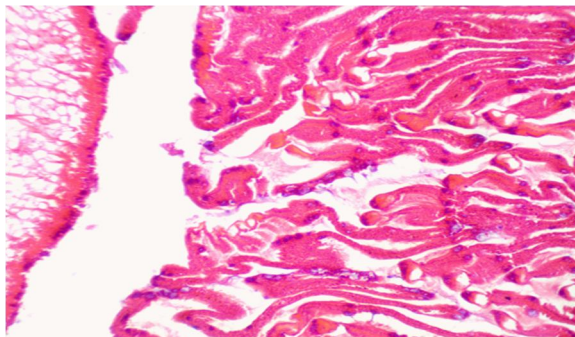


Figure 3: Microphotograph of the tissue of *Tympanotonus fuscatus var radula* exposed to 1.8ml concentration of the paint effluent.

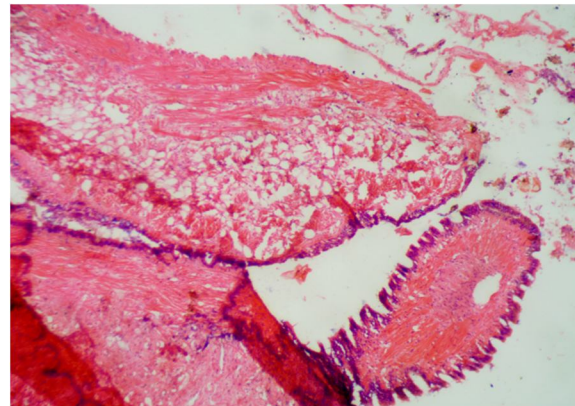


Figure 4: Microphotograph of the tissue of *Tympanotonus fuscatus var radula* exposed to 0.5ml concentration of the paint effluent.

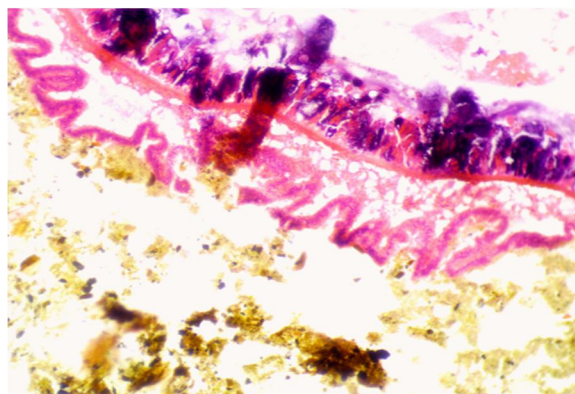


Figure 5: Microphotograph of the tissue of *Tympanotonus fuscatus var radula* exposed to 0.2ml concentration of the paint effluent

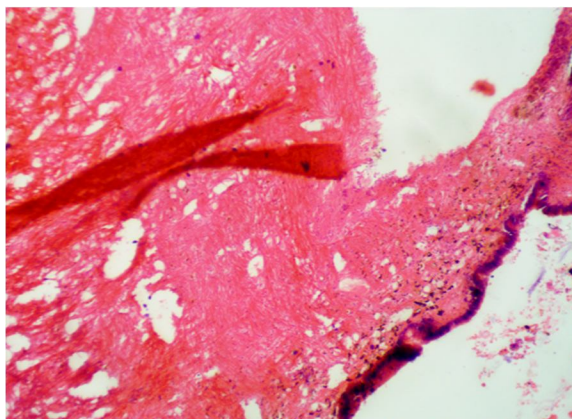


Figure 6: Microphotograph of the tissue of *Tympanotonus fuscatus* var *radula* exposed to 0.13ml concentration of the paint effluent.

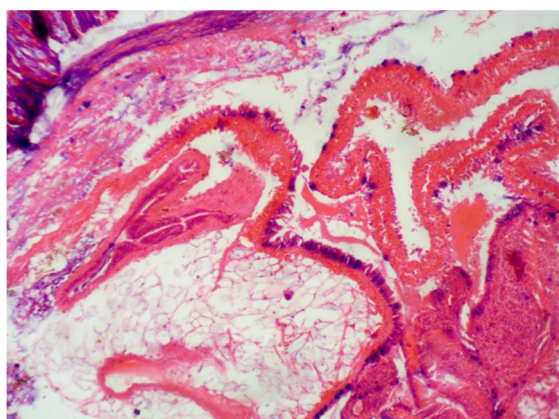


Figure 7: Microphotograph of the tissue of *Tympanotonus fuscatus* var *radula* exposed to 0.1ml concentration of the paint effluent.

IV. DISCUSSION

Result of acute exposure and mean mortality of *Tympanotonus fuscatus* var *radula* to the paint effluent showed that mortality was recorded after 48, 72 and 96 hours of exposure in the different concentrations. The highest mean mortality was recorded at exposure time for *T. fuscatus* var *radula* in 600ml and 700ml respectively 300ml (Table 3 and Figure 1B). This was followed by 400ml and 300ml accordingly, while the 500ml exposure recorded the lowest mortality. Generally, the values of the associated lethality decreased progressively as the exposure duration and time increased. It was evident from this study that an increase in the concentration of the effluent resulted in an increase in mortality rate. Similar results were obtained by Bassey et al., 2018 in *Clarias gariepinus* exposed to paint effluent and by Edori et al., (2014) in *Tympanotonus fuscatus* exposed to kerosene; Edeghagba et al., (2017) in *Tympanotonu. fuscatus* exposed to kerosene. The *T. fuscatus* var *radula* in higher concentrations were affected most and showed that the higher the effluent concentration, the higher the effect on the organism's behavior. This corroborate with the findings of Edori et al., (2014).

Findings from Table 3 showed that the paint effluent was toxic to the *T. fuscatus* var *radula* at high concentrations and longer exposure period. In this study, 40% mean mortality of *T. fuscatus* var *radula* was observed in the group exposed to 600 and 700ml concentration respectively, of the paint effluent after 96 hours (Table 3 and Figure 1B) and this was similar to the findings observed by Bassey et al., 2018, who observed 100% mortality of *Clarias gariepinus* exposed to 100% concentration of paint effluent. However, the differences in the mortality of the test organisms may be due to the differences in composition of the toxicant

The 96 hours LC_{50} value obtained in this study (7.51.ml) was lower than the one reported by Bassey et al., 2018 (LC_{50} of 39.81%; Edori et al., 2014 (LC_{50} of 111.14ml/L) but it was similar to the LC_{50} value of 9.50% reported by Pathan et al., (2009); Edeghagba and Badru, 2019 (LC_{50} of 4.92ml/L) on the evaluation of pharmaceutical effluent against *Tympanotonus fuscatus*

This study, recorded high BOD in the paint effluent (Table 1B), implying that oxygen might have been depleted, leading to suffocation of the organism, which in turn led to their death. Moreso, since the organism is a deposit feeder, it must have incorporated some part of the dissolved component in the paint effluent into its tissues and this eventually led to alterations in the

physiology of the organism and finally death. This observation was similar to the findings obtained by Edori *et al.*, (2014). *T. fuscatus var radula* in the control showed no abnormal behavior, no erratic movement and active behavioural response.

Chronic toxicity tests are more complex and the effects are more complex and are studied for longer period of time using low concentrations (Milda, 2007). In this research, it is most likely that the paint effluent may be neurotoxic and its effect may be attributed to the presence of lead and mercury in it. This observed behavioural changes was similar to the one observed by Ogelaka *et al.*, (2017), they studied the toxicity of herbicide-paraforce on *T. fuscatus*.

Results of physico-chemical determination (Table 1A), revealed that the pH value of the effluent was 6.75 ± 0.05 which is similar to the pH ranges of 6.25, 6.35 and 6.40 obtained by Onuegbu *et al.*, 2013, Bassey *et al.*, (2018) and Gandhi *et al.*, (2017) respectively in their works but slightly higher than the pH values (5.48 ± 0.07 and 5.8 ± 0.6) obtained by Osobamiro and Atewolara-Odule, (2015) and Jolly *et al.*, (2012). In this study, the pH value indicated that the effluent was slightly acidic. This value complied with the NESREA and WHO permissible limit and therefore, poses no danger on the receiving environment (Table 1A). According to Onuegbu *et al.*, 2013, the pH value obtained may be due to use of ammonia as buffer in the water based paint. pH is the measure of the acidity or alkalinity of waters, it is a very important parameter due to the fact that various chemical reactions that takes place in the aquatic environment are controlled by any change in its value. The sensitivity of aquatic organisms is affected by pH because most of their metabolic activities are pH dependent (Wang *et al.*, 2002), hence, any pH value higher or lower could kill aquatic lives (Tesfalem and Abdrie, 2017). Moreso, the toxicity of heavy metal gets enhanced at a particular pH (Berhun and Solomon, 2017).

Electrical conductivity (EC) value obtained in this study, was $4.65.50 \pm 2.50$ ms/cm (Table 1A) and within the WHO acceptable limits (Table 1A). However, it was significantly different than the average value (234us/cm) obtained by Onuegbu *et al.*, (2013). Berhun and Solomon (2017), said that, the Electrical Conductivity is used as a measure of the water's ability to conduct electric current and it is dependent on the presence of ions, their concentration, movement and water temperature. It is also used as a measure of salinity. Total dissolved solid (TDS) is a measure of total inorganic salts and other substances that are dissolved in water (Berhun and Solomon, 2017). High concentration of TDS affects water density and also influences oxygen solubility in water. Table 1A result in this work revealed a TDS value of 231 ± 3.00 mg/L which was similar to the one (224mg/L) reported by Onuegu *et al.*, 2013 and Chidozie and Nwakanma, (2017), obtained TDS value between the range of 208-270mg/L but was significantly greater when compared to the values (2.42 ± 1.02 and 5.26 mg/L) obtained by Bassey *et al.*, (2018) and Gandhi *et al.*, (2017) respectively. All the values obtained complied with WHO and NESREA permissible limits. Total suspended solids value was 154.50 ± 2.50 mg/L (Table 1A), a similar value (126.920 ± 1.892 mg/L) was obtained by Osobamiro and Atewolara- Odule (2015), but was lower than the values (55-1980mg/L) obtained by Berhun and Solomon, (2017). Also, the TSS value obtained in this study was significantly greater than the values (6.15 and 7.50 ± 2.11 mg/L) obtained by Onuegbu *et al.*, 2013 and Bassey *et al.*, (2018) and exceeded the maximum acceptable limits (30 and 100) respectively (Table 1A). TSS in an effluent is dependent on the amount of suspended particles, soil, silts and it is directly related to turbidity. According to Tesfalem and Abdrie (2017), high concentration of TSS may be due to the fact that the effluent contained large amount of suspended or insoluble particles and salts. High suspended solids concentrations can block light from penetrating water bodies, causes less oxygen to be released into the water bodies, increase water surface absorption of heat from sunlight and this in turn increases water temperature and lower oxygen level. This effluent if directly discharged into water bodies may be unsuitable for aquatic lives.

The Total solid value was 154.40 ± 2.50 mg/L as shown in (Table 1A). This value complied with WHO standards. However, when compared with the mean value (723mg/L) obtained by Onuegbu *et al.*, (2013) in their work on the physico-chemical analysis of effluents, the value was lower. According to Chidozie and Nwakanma, (2017), high solid contents in effluent discharged into water bodies is detrimental and undesirable as it may constitute organic and inorganic solids which reduces sunlight penetration and thus reduced the ability of microorganisms to photosynthesize.

The dissolved oxygen (DO) analysed in the paint effluent was 1.80 ± 0.02 mg/L (Table 1B). It is an important parameter for the survival of aquatic organism. DO above 5mg/L is supportive for marine life while concentrations below is very harmful. In this study, the DO value was lower than the limit set by WHO (Table 1B). This reduced DO value indicated that the paint effluent was organic in nature and as such required oxygen for decomposition by microorganism, also, the lower DO value may be due to high turbidity and suspended materials which affected the dissolution of oxygen (Jangua *et al.*, 2009). Hence, the paint effluent was capable of causing death to the *T. fuscatus var radula* because the oxygen required by the organism was depleted by microorganisms.

The chemical oxygen demand (COD) and biological oxygen demand (BOD) connotes pollution of water by oxygen depletion (Lokhade *et al.*, 2011). They are both useful parameters in water quality analysis and are both a function of DO. COD indicates the presence of non- biodegradable materials present in a sample. In this work the value obtained for COD was 43.07 ± 0.70 mg/L (Table

1B). The COD value obtained was below the NESREA and WHO permissible limit of 200 and 100mg/L respectively. (Table 1B) and this connoted that the paint effluent contains less non- biodegradable organic material. However, this value was lower than the values (1092, 425-1945 and 100-2190mg/L) reported by Onuegbu *et al.*, 2013; Tesfalem and Abdrie, (2017) and Berhun and Solomon, (2017) for the Paint effluent. This high COD value may be due to the presence of large amount of toxic substances and oxidizable inorganic compounds such as pigment and binders in the paint effluent. On the other hand, The BOD value of the paint effluent was higher than the corresponding COD which indicated that the substances contained in the effluent were basically biodegradable.

Biological oxygen demand (BOD) is the measure of the oxygen required by microorganisms while breaking down oxygen. The BOD value of the paint effluent was 132.00 ± 4.00 mg/L (Table 1B). This value was greater than values (66 ± 8 mg/L) reported by Jolly *et al.*, (2012) and mean value of 0.4mg/L reported by Danhusi *et al.*, (2012) but lesser when compared to the values (190.00 ± 12.62 mg/L and 47-600mg/L) reported by Bassey *et al.*, (2018) and Tesfalem and Abdrie, (2012) respectively. The high BOD value observed in the study was higher than the WHO and NESREA permissible limit as seen in (Table 1B). This high BOD value may be due to the presence of high organic compounds in the paint effluent. According to Onuegbu *et al.*, (2013), the presence of high organic compounds such as thickener, alkyd resins and acrylic co-polymer used as dispersants and binders may account for the high biodegradable organic matter which impacts the BOD. Since an increase in BOD will lead to a decrease in DO, hence, the increased oxygen consumption of oxygen in the paint effluent which posed a threat to the test organism exposed to the effluent.

The result for sulphate (SO_4^{2-}) and nitrates (NO_3^-) were 163.03 ± 1.73 mg/L and 6.32 ± 0.09 mg/L respectively (Table 1B). These parameters did not exceed the WHO and NESREA limits of 200 and 500mg/L respectively for sulphates and 10mg/L for Nitrate. In addition, the results were significantly greater than the average value (30mg/L and 0.25mg/L) obtained by Onuegbu *et al.*, (2013) but lower than the range values (492.93-524.87mg/L and 8.94-9.13mg/L), respectively obtained by Chidozie and Nwakanma, (2017). The implication is that, increased levels of nitrates in wastewaters may give rise to methaemoglobinemia (Osobamiro and Atewolara-Odule, 2015).

The result for phosphate (PO_4^{3-}) in the paint effluent was 229.85 ± 3.05 mg/L (Table 1B). This phosphate value was significantly higher than the range values (99.23-120.13mg/L) reported by Chidozie and Nwakanma, (2017) and the range values (2.265-66.375mg/L) obtained by Tesfalem and Abdrie, (2017). From our study, the values measured exceeded the standard limit of 5mg/L and 10mg/L set by WHO and NESREA. This high phosphate values may have occurred through the use of detergents during cleaning operations consequently, can cause an over growth of plants and algae, a process known as Eutrophication.

In Table 2 results, chromium and cadmium were not detected in the paint effluent. The concentration of copper in the paint effluent was (0.0500 ± 0.0012 ppm), significantly lower than the values (2.46mg/L) reported by Onuegbu *et al.*, (2013), the value (2.52 ± 0.12 mg/L) reported by Bassey *et al.*, (2018) and the range values (2.09- 189.16 mg/L) reported by Tesfalem and Abdrie, (2017). Also, Copper levels in this work, did not exceed the WHO and NESREA limits of 1.0mg/L (Table 2). According to Onuegbu *et al.*, (2013), Copper is a trace element that is required by living organisms in small quantities, but excess of it can cause serious adverse effects. Tesfalem and Abdrie, (2017), reported that Copper becomes toxic for organism when the rate of absorption is more than the rate of excretion (bioconcentration). In another comment by Figueiredo-Fernandes *et al.*, (2007), Copper causes histopathological changes in gills exposed to high concentrations. The effect could be represented by damage in edema, lifting of lamellar epithelia and an intense vasodilatation of the lamellar vascular

The value of zinc was 0.1790 ± 0.0020 ppm concentration. It was observed that zinc had the highest value among the heavy metals detected (Table 2), however, the value obtained was within the permissible limit of 5.0mg/l set by WHO and NESREA. Comparing this value with the results of other researchers, it value was lower than the one (0.98 ± 0.01) reported by Bassey *et al.*, (2018) and the one (35.6mg/L) obtained by Oladele *et al.*, (2018). In another report, the zinc value detected in this study, was higher than (0.067 ± 0.004) stated by Jolly *et al.*, (2012). According to Onuegbu *et al.*, (2013), the low concentration of zinc in the paint effluent may be attributed to the low dosage of white and red pigments during the paint formulation. Alkesh (2017), observed that, Zinc though is an essential element required by organism for survival but excess of it can pose substantial threats due to its ability to bioaccumulate.

Mercury concentration in Table 2 was (0.0036 ± 0.0002 ppm), and the value conformed to the regulatory bodies standards. However, this value was low when compared to the value (0.92 ± 0.02 mg/L) obtained by Bassey *et al.*, (2018). According to Zahir *et al.*, (2005), Mercury has no known role in biological systems. It is considered as a non-essential, non-biodegradable and lasting heavy metal, moreso, the bioaccumulation of Mercury is extremely poisonous.. There is no known nutritional requirement for mercury and its presence in sea foods such as periwinkles results from environmental contamination. Chronic exposure can lead to symptoms of central nervous system involvement (Vieira *et al.*, 2009).

Lead (Pb) has been reported to be toxic to aquatic life and as a potent pollutant to the natural ecosystem at low concentrations (Van Dyk *et al.*, 2007). It is one of the most common heavy metal found in paint industrial wastewater. In this study, the value of lead obtained was $(0.0130 \pm 0.0001 \text{ ppm})$, this value was within the WHO and NESREA allowable limits of 0.2 and 0.1 mg/L respectively (Table 2). However, when compared to the value (9.6 mg/L) reported by Danhusi *et al.*, (2012), Onuegbu *et al.*, (2013) who reported 0.09 mg/L of Lead in paint effluent and Tesfalem and Abdrie (2017), reported the range of Lead value as 0.68-18.73 mg/L in their work, consequently, these low concentration of Lead may be attributed to the low preferential usage of the metal as pigment and as drier for the gloss finishes.

Histopathological changes of *T. fuscatus var radula* tissues exposed to varying sublethal concentrations of the paint effluent showed that the plant effluent was toxic and had detrimental and deadly effect on the organisms. Figure 2, used as the control, showed no abnormalities, all the tissues were intact, the foot muscle, internal organs, basophilic portion with nucleus and acidophilic cytoplasm of the acinar cells were all normal. Figure 3 shows the 1.8 ml concentration of the paint effluent, it revealed partially destructed digestive tract with the presence of few aggregates of inflammatory cells and large fatty vacuoles, also, there were areas of shrinkage and degeneration of tubule cells. This abnormality seen in the tissue agreed with the work of Kullasoot *et al.*, (2016), who studied the histopathological effect of pulp and paper mill effluent on the digestive gland of river snails (*Filopaludina martensi*). They reported, increased number of enlarged vacuoles, enlarged tubule lumen and destruction of digestive cells. Figure 5 shows *T. fuscatus var radula* exposed to 0.2 ml of the paint effluent, where the digestive tract was partially destructed with presence of aggregates of inflammatory cells. There were areas of shrinkage and degeneration of tubule cells. Also, the lumen contained debris and other waste materials with abnormalities. Figure 7 is exposure of *T. fuscatus var radula* to 0.1 ml concentration, again the digestive tract was partially destructed with presence of several aggregates of inflammatory cells, areas of shrinkage and degeneration of tubule cells, areas of necrosis and large fatty vacuoles were seen. Figures 4 and 5 showed the tissue of test organism exposed to 0.5 ml and 0.13 ml concentrations and the histologic sections showed partially destructed foot muscle with presence of several aggregates of inflammatory cells, the digestive tracts were not seen because they had been degenerated, the basophilic portion of the nucleus and acidophilic cytoplasm of the acinar cells were seen. There were areas of shrinkage and degeneration of tubule cells, areas of necrosis and few fatty vacuoles. The tissue showed some level of abnormalities.

Histopathology results of this research, showed a wide spectrum of histopathological changes on the tissues which might impair the normal function of the organism that can be linked to the prolonged exposure of the organism to the chronic levels of the heavy metals contained in the paint effluent. According to Oladele *et al.*, 2018, the histological alterations observed in the tissues of mice exposed to paint effluent were attributed to the toxic substances such as the heavy metals contained in the effluent. Heavy metals are metallic element that has a relatively high density and they are toxic at low concentrations. They can bioaccumulate in the tissues of living organisms, hence they are stored faster in the body tissue than they can be excreted. Heavy metals such as cadmium, lead, chromium, mercury and arsenic, have high toxicity and carcinogenicity. These metals connote systemic toxicants that are known to induce multiple organ damage even in small concentrations (Freeman and Ovie, 2017).

T. fuscatus were exposed to low concentrations of the paint effluent containing heavy metals for a prolonged period (Table 3). The organism might have absorbed these heavy metals directly into their tissues during the process of feeding or through the ingestion of the contaminated water. The mechanism of heavy metal detoxification and excretion cannot be handled by the organism within a short time frame on prolonged exposure to the paint effluent and as a result of this, the heavy metals accumulated in their active tissues. This accumulation thus led to severe histopathological alterations in the tissues of the organisms (Figures 4 and 5). The alterations as evident in the tissues were areas of necrosis (areas of dead cells), presence of aggregates of inflammatory cells, tubule shrinkage and degeneration as well enlarged fatty vacuoles (Figure 7). The fact that tissues of the *T. fuscatus var radula* marked histopathological changes confirms that the paint effluent was toxic and pathogenic. The findings agreed with the work of Oladele *et al.*, (2018) on the histopathological effect of paint effluent on swiss albino mice (*Mus musculus*). Hence, histological biomarkers can be effectively used in ecotoxicological and biomonitoring tool for assessing the sub lethal level toxicity and chronic paint effluent exposure in aquatic ecosystems.

V. CONCLUSION

Conclusively, the 96th hour LC_{50} value obtained after acute exposure was 7.51 ml and this low value implied that the paint effluent was toxic. The 14 days chronic exposure of the test organism revealed some changes in the behaviour, morphology and physiology of the test organisms, however, the organisms in the control experiment not show these changes. Moreover, the mean mortality data trend at a particular concentration increased with an increase in the exposure time. The physico-chemical parameters determined in the paint effluent complied with the regulatory limits set by WHO and NESREA) except for Biological oxygen demand (BOD),

Phosphate, Total suspended solids and Dissolved oxygen (DO). The high BOD, phosphate and TSS values indicated that the paint effluent contained oxidizable or biodegradable organic and suspended materials and as a result, the DO value reduced below the standard level of 5mg/L which is supportive for marine life. This decreased DO value showed that the paint effluent, when discharged into the aquatic environment, is capable of causing death to the aquatic organisms based on the fact that the oxygen required for the survival of these are being consumed by microorganism during the process of biodegradation. The heavy metal levels analysed in the paint effluent were also in conformity with WHO and NESREA standards. However, on continuous discharge into the environment, serious environmental pollution and adverse effects on the health of living organisms could occur. Histopathological examination on the whole tissues of the periwinkle exposed to the paint effluent revealed several anomalies such as partially destructed digestive tract and foot muscles with few to several aggregates of inflammatory cells, necrosis, shrinkage and degeneration of tubule cells as well as formation of enlarged fatty vacuoles. These findings indicated that the paint effluent was toxic and harmful to the health of the *T. fuscatus* and as such, could pose substantial threat to other aquatic organisms

VI. ACKNOWLEDMENT

The authors are grateful for the provision of laboratory services of the Environmental biology unit of Yaba College of Technology and the Histopathology main laboratory at the Anatomic and Molecular pathology department of the Lagos University Teaching Hospital (LUTH), Idi-Araba, Lagos state towards the success of this research.

A. Conflict Of Interest

The authors declare that there is no conflict of interest.

REFERENCES

- [1] Aboulhassan, M.A., Souabi, S., Yaacoubi, A. and Bauduc, M. (2006). Improvement of Paint Effluents Coagulation using Natural and Synthetic Coagulant Aids. *Journal of Hazardous Materials*, 138: 40–45.
- [2] Aboulhassan, M.A., Souabi, S., Yaacoubi, A. and Bauduc, M. (2014). Treatment of Paint Manufacturing Wastewater. *International Journal of Science, Environment and Technology*, 3(5): 1747-1758.
- [3] Akpor, O.B. and Muchie, M. (2011). Environmental and Public Health Implications of Wastewater Quality. *African Journal of Biotechnology*, 10(13):2379-2387.
- [4] Alkesh, I.S. (2017). Heavy Metal Impact on Aquatic Life and Human Health- An Overview. IAIA17 Conference Proceedings/ IA's Contribution in Addressing Climate Change. 37th Annual Conference of the International Association for Impact Assessment, 4-7 April, 2017.
- [5] American Public Health Association (APHA), (2005). American Water Works Association (AWWA). Standard Methods for the Examination of Water and Wastewater. 21st Edition, Washington, D.C.
- [6] Bassey, E.O., Akaniyene, P.J. and Finian, T.O. (2018). Water Quality Contamination and Mortality of African Mud Catfish (*Clarias gariepinus*; Burchell, 1822) Fingerlings Exposed to Paint Effluents. *Asian Journal of Environment and Ecology*, 7: 1-12.
- [7] Berrhun, D. and Solomon, Y. (2017). Assessment of the Physico-chemical and Heavy Metal Concentration of Paint Industry in Addis Ababa, Ethiopia. *International Journal of Waste Resources*, 7: 306-310.
- [8] Chidozie, K. and Nwakanma, C. (2017). Assessment of Saclux Paint Industrial Effluents on Nkoho River in Abia State, Nigeria. *Journal of Ecosystem and Ecography*, 7: 240-247.
- [9] Dahunsi, S.O., Oranusi, S.U. and Ishola, R.O. (2012). Bioaccumulation Pattern of Cadmium and Chromium in Head Capsule and Body Muscle of *Clarias gariepinus* (Burchell, 1822) exposed to paint emulsion effluent. *Research Journal of Environmental and Health Sciences*, 4(2): 166-170
- [10] Drishya, M.K., Binn, K.S., Mohan, K.M., Amhikandevi, A.P. and Aswin, B. (2016). Histopathological Changes in the Gills of Fresh Water Fish, *Catla catla* Exposed to Electroplating Effluent. *International Journal of Fisheries and Aquatic Studies*, 4(5): 13-16
- [11] Edeghagba, Beatrice Onobhaze., Afolabi, Adetoun Adebunmi., Badru, Temitope Ibiwunmi and Nwokolo, Lovelyn Chioma. (2017). Ecotoxicological Assessment of Diesel and Kerosene Exposure on the Prosobranch Periwinkle, *Tympanotonus fuscatus* var *radula*. *YabaTech Anniv. Journal*, 1(1): 135-144
- [12] Edeghagba, B.O. and Badru, T.I. (2019). Chemical Evaluation of Effluent from A Pharmaceutical Industry using *Tympanotonus fuscatus*. *Nigeria Journal of Botany*, 32(1): 101-109.
- [13] Edori, O. S., Ekpete, O. A and Edori, E. S (2014). Quantal Response of Periwinkle (*Tympanotonus fuscatus*) after Exposure to Kerosene. *International Journal of Biochemistry Research and Review*, 4(3): 253-259.
- [14] Ethan, J.N., Richard, W.M. and Michael, G.K. (2003). The Effect of an Industrial Effluent on an Urban Stream Benthic Community: Water Quality vs. Habitat Quality. *Environmental Pollution*, 123(1): 1-13.
- [15] Figueiredo-Fernandes, A., Ferreira-Cardoso, J., Garcia-Santos, S., Monteiro, S., Carrola, J., Matos, P., and Fontainhas-Fernandes, A. (2007). Histopathological Changes in Liver and Gill Epithelium of Nile Tilapia, *Oreochromis niloticus*, Exposed to Waterborne Copper. *Pesquisa Veterinaria Brasileira*, 27(3): 103-109.
- [16] Freeman, O.E. and Ovie O.J. (2017). Heavy Metal Bioaccumulation in Periwinkle (*Tympanotonus* Spp) and Blue Crab (*Callinectes amnicola*) Harvested from a Perturbed Tropical Mangrove Forest in the Niger Delta, Nigeria. *Journal of Agriculture and Ecology Research International*, 11(1):1–12.
- [17] Gandhi, N., Sirisha, D. and Smita, A. (2017). Determination of Physico-chemical Properties of Different Industrial Wastewater of Hyderabad, India. *International Research Journal of Environmental Sciences*, 6(3): 1-10.
- [18] Gernhofer, M., Pawet, M., Schramm, M., Müller, E. and Triebkorn, R. (2001). Ultrastructural Biomarkers as Tools to Characterize the Health Status of Fish in Contaminated Streams. *Journal of Aquatic Ecosystem, Stress and Recovery*, 8:241-260.

- [19] Iheoma, C.C., Chinomso, M. E., Nwanonenyi, S. C. and Ifeoma C.U. (2015). Adsorption Treatment of Industrial Paint Effluent for the Removal of Pollutants by Local Clays. *International Journal of Scientific & Engineering Research*, 6(10): 690-703.
- [20] Jangua, M.Y., Ahmad, T. and Akhtar, N. (2009). Limnology and Trophic Status of Shahpur Dam Reservoir. *Pakistan Journal of Animal Plant Science*, 19(4): 224-273.
- [21] Jolly, Y.N., Hossain, A., Satter, A. and Islam, A. (2012). Impact of Heavy Metals on Water and Soil Environment of a Paint Industry. *Journal of Bangladesh Chemical Society*, 25(2): 159-165.
- [22] Kanu, I.P. and Achi, O.K. (2011). Industrial effluents and their impact on water quality of receiving rivers in Nigeria. *Journal of Applied Technology and Environmental Sanitation*, 1 (1):75-86.
- [23] Kullasoot, S., Tinnapan, N. and Chitchol, P. (2016). Histopathological Effects of Pulp and Paper Mill Effluent on the Digestive Glands of River Snails *Filopaludina martensi* (Gastropoda, Viviparidae) in the Mae Klong River, Western Thailand. *International Journal of Applied Environmental Sciences*, 11(4): 903-913.
- [24] Lokhande, R. S., Singare, P. U. and Pimple, D. S. (2011). Study of Physico-chemical Parameters of Wastewater Effluents from Taloja Industrial Area of Mumbai India. *International Journal of Ecosystem*, 1(1), 1-9.
- [25] Milda, Z.V. (2007). Review of the Methods for Acute and Chronic Toxicity Assessment of Single Substances, Effluents and Industrial Waters. *Acta Zoologica Lituonica*, 17: 3-11.
- [26] Moruf, R.O. (2015). Some aspect of the Biology of periwinkle, *Tympanotonus fuscatus var. radula* in the Mangrove swamp of Lagos Lagoon Front, Lagos. Nigeria. M.Sc.Thesis, University of Lagos, 2015, 97.
- [27] Moslen, M., Ekweozor, I.K.E. and Nwoka, N.D. (2017). Assessment of Heavy Metals and Bioaccumulation in Periwinkle (*Tympanotonus fuscatus var. radula* (L.)) Obtained from the Upper Reaches of the Bonny Estuary, Nigeria. *Journal of Heavy Metal Toxicity and Distribution*, 2(2): 3-5.
- [28] National Environment (Standards for Discharge of Effluent into Water or on Land) Regulations. Under section 26 and 107 of the National Environment Act, Cap 153.
- [29] Nwakanma, C. and Oleh, K.F. (2013). Comparative Study of the Physicochemical and Microbial Evaluation of Different Brands of Bottled, Sachet, Tap, Well water in Enugu Metropolis. *Proceedings of the 2nd Biennial International Conference on Biotechnology and National Development*, 9-13pp.
- [30] Odiete, W.O. (1999). *Environmental Physiology of Animals and Pollution*, 1st ed. Diversified Resources Limited, Lagos.
- [31] Ogelaka, D.F., Ogbomida, T.E., Odiwari, P.A., Ezemonye, L.N. and Okiemen, F.E. (2017). Toxicity of Non-Selective Herbicide-Paraforce to Periwinkle Snail (*Tympanotonus fuscatus var radula*). *Archives of Agriculture and Environmental Science*, 2(3): 194-201.
- [32] Oladele, E.O., Adewunmi, O. O., Yahaya, T. and Taiwo, A. (2018). Histopathological Effect of Paint Effluent on Swiss Albino Mice (*Mus musculus*). *Nigeria Journal of Pure and Applied Science*, 31(2): 3212-3219.
- [33] Onuegbu, T.U., Umoh, E.T. and Onwuekwe, I.T. (2013). Physico-chemical Analysis of Effluents from Jacobon Chemical Industries Limited, Makers of Bonalux Emulsion and Gloss paints. *International Journal of Science and Technology*, 2(2): 169-173.
- [34] Osobamiro, M.T. and Atewolara-Odule, O.C. (2015). Determination of some Physico-chemical Parameters and Levels of Some Heavy Metals in Industrial Wastewaters. *International Journal of Scientific and Engineering Research*, 6: 2229-5518.
- [35] Pathan, T.S., Sonawane, D.L. and Khillare, Y.K. (2009). Toxicity and Behavioural Changes in Freshwater Fish *Rasbora daniconius* Exposed to Paper Mill Effluent. *Journal of Biotechnology Resource*, 2(4): 263-266.
- [36] Rana, S. V. (2006). *Environmental Pollution, Health and Toxicology*. Alpha Science International Ltd. Oxford UK.
- [37] Samuel, O.B., Osuala, F. and Odeigah, P.G.C. (2010). Cytogenotoxicity Evaluation of Two Industrial Effluents using *Allium cepa* Assay. *African Journal of Environmental Science and Technology*, 4(1):21-27
- [38] Tesfalem, B.W. and Abdrie, S.H. (2007). Toxicity Study of Heavy Metals Pollutants and Physico-Chemical Characterization of Effluents Collected from Different Paint Industries in Addis Ababa, Ethiopia. *Journal of forensic science and criminal investigation*, 5(5): 1-7
- [39] USEPA, (2006). United States Environmental Protection Agency. "Terms of Environment Beginning With "E"". Assessed June 9, 2010.
- [40] Van Dyk, J.C., Pieterse G.M. and Van Vuren, J.H.J. (2007). Histological Changes in Liver of *Oreochromis mossambicus* (Cichlidae) after Exposure to Cadmium and Zinc. *Ecotoxicology and Environmental Safety*, 66: 432-440.
- [41] Viera, L.R., Gravato, C., Soares, A., Morgado, F. and Guiljermimo, L. (2009). Acute Effect of Copper and Mercury on the Estuarine Fish *Pomatoschistus microps*: Linking Biomarkers to Behaviour. *Chemosphere*, 76(10): 1416-1427.
- [42] Wang W., Wang A., Chen L., Liu Y. and Sun R. (2002). Effects of pH on Survival, Phosphorus Concentration, Adenylate Energy Charge and Na⁺-K⁺ ATPase Activities of *Penaeus chinensis* Osbeck Juveniles. *Aquatic Toxicology*, 60, pp. 75-83.
- [43] World Health Organisation (WHO), (2003). Guidelines for drinking water quality, health criteria and other supporting information 2nd edn.
- [44] Zahir, F., Rizwi, S.J., Haq, S.K. & Khan, R.H. (2005). Low Dose Mercury Toxicity and Human Health. *Environmental Toxicology and Pharmacology*, 20(2): 351-360



10.22214/IJRASET



45.98



IMPACT FACTOR:
7.129



IMPACT FACTOR:
7.429



INTERNATIONAL JOURNAL FOR RESEARCH

IN APPLIED SCIENCE & ENGINEERING TECHNOLOGY

Call : 08813907089  (24*7 Support on Whatsapp)