



iJRASET

International Journal For Research in
Applied Science and Engineering Technology



INTERNATIONAL JOURNAL FOR RESEARCH

IN APPLIED SCIENCE & ENGINEERING TECHNOLOGY

Volume: 7 Issue: XII Month of publication: December 2019

DOI: <http://doi.org/10.22214/ijraset.2019.12011>

www.ijraset.com

Call:  08813907089

E-mail ID: ijraset@gmail.com

An Observational Cadaveric Study on Accessory Piriformis Muscle in Relation of Sciatic Nerve

Dr. Isha herswani¹, Dr. Sunil Kumar Yadav², Dr. Sandeep M. Lahange³, Dr. Saurabh Jain⁴, Dr. Dharmendra Choudhary⁵, Dr. Neha Udainiya⁶

¹Ph.d scholar, ^{2,3}Associate Professor, ⁴Ph.d scholar, ⁵PG Scholar, P.G Dept of Sharir Rachana, National institute of Ayurveda

Abstract: An observational cadaveric study based on dissection were done on 46 yrs male labor body build person at the P.G dept of Sharir Rachana, NIA Jaipur while performing the dissection, unilateral accessory slip of piriformis muscle were found over right gluteal region with higher bifurcation of sciatic nerve component in gluteal region. This accessory slip was found which were passing through in between the tibial and common peroneal component of sciatic nerve. Usually sciatic nerve emerges in between the lower border of piriformis and upper border of superior gemelli muscle with bifurcation is related with popliteal fossa. These two associated structural variation of additional muscle slip with relation to sciatic nerve can cause over stretching of main piriformis fibers while performing lateral rotation of hip joint can lead to sciatic nerve impairment, results as back pain which is one of cause of piriformis syndrome. These kinds of structural changes can be reveled on imaging technique in living person and may lead to enhance deposit causative factors for related physiological disturbance.

Keywords: Accessory piriformis, higher bifurcation of sciatic nerve, Piriformis, piriformis syndrome

I. INTRODUCTION

The **Piriformis** lies partly within the pelvis in its posterior wall and partly in the gluteal region posterior to the hip joint. it is the key muscle of gluteal region.¹ Key muscle is important land mark of specific region in body to make it identified the other bodily structure like nerves, arties and veins. In gluteal region nearly, approximation of branches of lumbar and sacral plexus can be easily identified in relation of this key muscle. Because of its key position in the buttock region it is the landmark of the gluteal region. As it travels through the greater sciatic foramen and fills this by effectively divides this space into an inferior and superior part to give an emergence roots of branches of nerve of this region. Being the key element of this region, slight variation or any injury to this muscle will lead to effect the near by important nerves of lumbar and sacral region mainly to sciatic nerve. This sciatic nerve emerges through below to the muscle and curving inferolateral descends midway between the ischial tuberosity and greater trochanter. It rests on dorsal surface of body of ischium separated by tricipital tendon of obturator internus with gemellus superior and inferior. At the back of thigh, the nerve is closed to long head of biceps femoris and usually at close to popliteal fossa it divides into tibial and peroneal component. Relation of sciatic nerve with piriformis and gemellus muscle is important to give protection to underlying bony structure of femur and hip bone. The piriformis provides the key to understanding relationships in the gluteal region because it determines the names of the blood vessels and nerves².The surface marking of the superior border of the piriformis is indicated by a line joining the skin dimple formed by the posterior superior iliac spine to the superior border of the greater trochanter of the femur. Being flat and thin shape of this, its relative contraction can effect the adjacent nerve.

It is partly internal to the osteoligamentous pelvis and partly external, posterior to the hip joint.³ its three digitations are attached anteriorly between the pelvic sacral foramina, to the floor and margins of groves leading from them, from the iliac gluteal surface near the posterior inferior iliac spine, capsule of sacroiliac joint. the muscle exits through the greater sciatic foramen to be attached by a round tendon to the upper border of greater trochanter, posterosuperior to the trochanteric fossa.⁴ The upper border of piriformis lies along the gluteus medius and its lower border along the gemellus superior. This muscle act as lateral rotator of thigh and in flexed thigh it acts as an abductor.⁵This muscle arises from fleshy digitations form and at the time of inferior attachment but often partly blended with, the common tendon of the Obturator internus and gemelli. Adjacent nerve like inferior gluteal nerve, pudendal nerve, sciatic nerve, posterior femoral nerve and muscular branches of sacral plexus appear between the piriformis and gemellus superior.⁶ Accidentally during the dissection on cadaver with age of 46 yrs male labor build up body were dissected in P.G dept of Sharir Rachana, at National institute of Ayurveda, Jaipur where extra flat, thin slip of muscle were found in inferior relation to the piriformis muscle, overlying the sciatic nerve with separate belly and its tendon in right side of gluteal region. This structural variation of piriformis muscle were found in right lower limb with higher bifurcation of sciatic nerve in gluteal region instead of popliteal fossa. Here in this cadaver higher separation of two component is relates with presence of accessory slip of muscle.

II. OBSERVATION DURING DISSECTION

While performing the dissection in right gluteal region, after the lateral reflection of gluteus medius muscle, along the inferior border of gluteus minimus muscle, flat thin muscle piriformis were found. piriformis muscle passes through the greater sciatic foramen and nearly fills it.

It's superior border were adjacent to inferior border of gluteus medius muscle. While searching of its inferior border of piriformis by probing action through finger, extra slip of accessory to main muscle were found, located inferior to main muscle belly of piriformis, separated through slip of deep fascia in same direction of overlying muscle. By inserting finger medial to the sciatic nerve, interval between the piriformis muscle and gemellus superior were open where concerning superior gluteal nerve and artery were found.

This extra slip of muscle were passing overlying the superior gluteal artery and nerve. This thin belly were taken its origin along with the main piriformis muscle with one slip over sacral attachment of main muscle. Passing its belly laterally through the two division of sciatic nerve in between to its two branches tibial and common peroneal nerve. Usually this division is seen in upper angle of popliteal fossa but presence of accessory slip make it divides into its two component superiorly than usual position. On convergence of accessory slip of fleshy fiber, whitish thin slip of tendon were taking insertion with tendon of superior gemellus by passing.

Finding are shown into figure A & B. This course of accessory slip of piriformis is rare found only in 17% objects according to data.⁷

III. DISCUSSION

Anatomy forms the base upon which specific function persists. These structures can access through the dissection in cadaver and via the MRI in living body. Myology is one of segment of anatomy which carries a lot of individuality in terms of variation in human body which lead to specific outcomes in form of discomfort or sometimes non-symptomatically. Structural variations those are reveals during the dissection, may only give an idea of any functional discomforts of person in living status, through this segment, anatomists cannot predict the actual result of any variation regarding to its physiological importance. For that concern previous available data based upon imaging techniques are better way to find out the specific clinical importance of variation in terms of its variation in its function.

Clinically structural variation of piriformis muscle can cause of piriformis syndrome where back pain is very common feature. Presence of accessory slip of muscle cause the stretching of sciatic nerve specially when the slip of fibers are pierces the two division of sciatic nerve. Piriformis syndrome is a rare cause of low backache and sciatica and is due to sciatic nerve entrapment at the greater sciatic notch.

The causes include hypertrophy, inflammation, infection, reflex spasm or contracture of the piriformis muscle, anatomical variants, such as accessory piriformis muscle or tendon.⁸ Presence of Accessory slip with any muscle may rare in case of piriformis muscle but whenever it present it is associated with the common peroneal nerve only. it is frequently pierced by the common peroneal nerve and thus divided more or less parts.

It may be united with the Gluteus medius, or send fibers to the Gluteus minimus or receive from the Gemellus superior. It may have only one or two sacral attachments or be inserted in to the of the hip-joint. It may be absent.⁹ In 17% of people, the piriformis muscle is pierced by parts or all of the sciatic nerve. Several variations occur, but the most common type of anomaly (81% of anomalies) is the Beaton's type B which is when the common peroneal nerve pierces the piriformis muscle.¹⁰

The piriformis muscle is frequently traversed by the common peroneal nerve, which may divide it. The sciatic nerve also varies in relation to the piriformis, in 168 dissection lee & Tsai (1974) observed variation in almost 30%, the nerve emerged above the muscle in 2.98%, through in it 1.8%, with its divisions above and below in 4.2%, one division between heads of a divided muscle above and one division above (1.2%) or below (19.6%), the last being commonest variation.¹¹

IV. CONCLUSION

Unilateral presence of accessory slip of piriformis, merging its tendon with superior gemellus muscle on its insertion site in between passing through the two division of sciatic nerve is one of variation associated with main piriformis muscle. Presence of accessory slip causes higher division of sciatic nerve into its two component. These structural changes may associated with stretching of sciatic nerve leading to pressure pain to nerve course but these kind of functionally changes cannot predict only on the cadaveric dissection. Functional relation with structural changes always requires the study on living object through an imaging techniques.

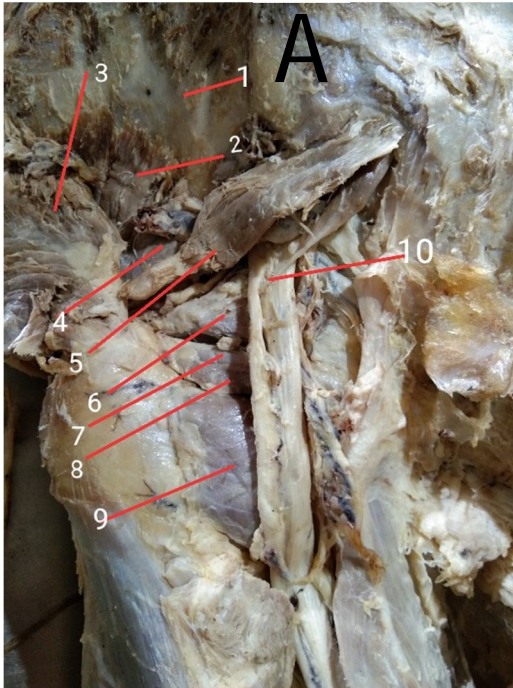


Fig. . Posterior gluteal region (R) showing muscle of region in relation with the bifurcation point of sciatic nerve

1. Iliac fossa
2. Gluteus minimus
3. Gluteus maximus
4. Gluteus medius
5. Piriformis muscle
6. Superior gemelli
7. Obturator internus
8. Inferior gemelli
9. Quadratus femoris
10. Tendon of accessory piriformis muscle passing through in between the two

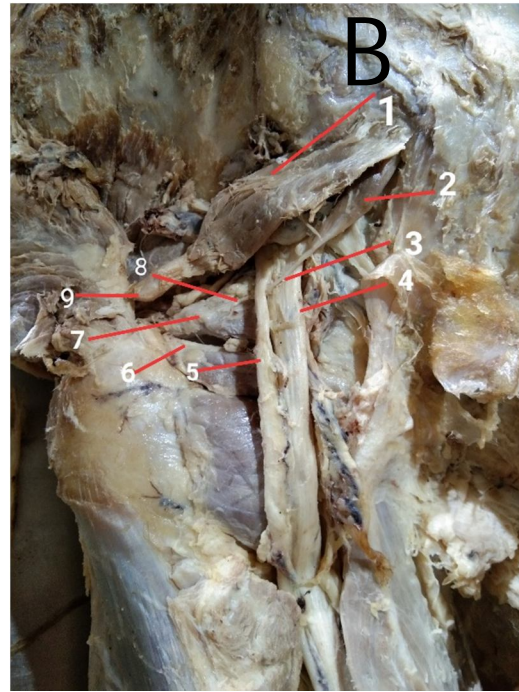


Fig. B. Posterior gluteal region (R) showing Accessory slip of piriformis muscle and its relation with adjacent structures

1. Piriformis muscle main belly (superficial)
2. Accessory slip of Piriformis muscle
3. Tendon of Accessory slip of Piriformis muscle
4. Tibial component of sciatic nerve
5. Common peroneal nerve
6. Tendon of obturator internus with inferior gemelli (inferior)
7. Common tendon of Superior gemelli and accessory slip of Piriformis muscle
8. Tendon of accessory slip just getting entering into the fibers of superior gemelli
9. Tendon of Primary Piriformis muscle

REFERENCES

- [1] Dutta A.K, essentials of human anatomy vol 1, cuerents books international, kolkatta fourth edition May 2009 pg 187
- [2] Moore K.L, dalley A.F, Agur A.M.R clinically orientated anatomy, published by wolters Kluwer pvt.ltd.new delhi.seventh edition 2014 pg no. 569.
- [3] Grays H., Gray's anatomy, edited by Williams peter l, dyson mary, ELBS publication 1992, 37 edition, Pg no.642
- [4] Grays H., Gray's anatomy, edited by Williams peter l, dyson mary, ELBS publication 1992, 37 edition, Pg no.643
- [5] Dutta A.K, essentials of human anatomy vol 1, cuerents books international, kolkatta fourth edition May 2009 pg 187
- [6] Grays H., Gray's anatomy, edited by Williams peter l, dyson mary, ELBS publication 1992, 37 edition, Pg no.643
- [7] Grays H., Gray's anatomy of human body, 2 edition 1860, Pg no.543
- [8] Sen A, Rajesh S. Accessory piriformis muscle : An esily Identifiable cause of piriformis syndrome on magnetic resonance imaging. Neurol India 2011;59:769-71
- [9] Grays H., Gray's anatomy of human body, 2 edition 1860, Pg no.543
- [10] Smoll NR (January 2010). "Variations of the piriformis and sciatic nerve with clinical consequence: a review". Clinical Anatomy. 23 (1): 8-. Doi 10.1002/ca.20893.PMID 19998490
- [11] Grays H., Gray's anatomy, edited by Williams peter l, dyson mary, ELBS publication 1992, 37 edition, Pg no.643



10.22214/IJRASET



45.98



IMPACT FACTOR:
7.129



IMPACT FACTOR:
7.429



INTERNATIONAL JOURNAL FOR RESEARCH

IN APPLIED SCIENCE & ENGINEERING TECHNOLOGY

Call : 08813907089  (24*7 Support on Whatsapp)