



# IJRASET

International Journal For Research in  
Applied Science and Engineering Technology



---

# INTERNATIONAL JOURNAL FOR RESEARCH

IN APPLIED SCIENCE & ENGINEERING TECHNOLOGY

---

**Volume: 8**

**Issue: IV**

**Month of publication: April 2020**

**DOI:**

[www.ijraset.com](http://www.ijraset.com)

Call:  08813907089

E-mail ID: [ijraset@gmail.com](mailto:ijraset@gmail.com)

# Survey on Detecting Exudates in Fundus Images

Pushpalatha R<sup>1</sup>, Shweta M Angadi<sup>2</sup>

<sup>1,2</sup>Department of Computer Science and Engineering, VTU University

**Abstract:** *Diabetic Retinopathy is a medical condition associated with high blood sugar. One of the indicators of this condition is the presence of exudates in the retinal areas of the eyes. Though exudates do exist even in a normal patient, the extent of the disease is usually associated with the area of the spread of these exudates. This paper deals with the survey conducted over the techniques that provide automated detection of exudates for the references of the ophthalmologists, which can be used in diagnosis and treatment of this condition.*

**Keywords:** *Diabetic retinopathy, exudates, fundus, survey, ophthalmologists.*

## I. INTRODUCTION

Diabetes is the disease which refers to sugar present in the blood. When the sugar in the blood increases it leads to eye problem and they are called diabetic eyes. Without diagnosis and treatment, diabetic eye disease can cause immutable vision loss or even blindness. Patients with diabetes are a greater risk for several different eye problems there is a greater risk for cataracts like clouding of the vision, clouding of the lens in the eye glaucoma, high pressure in the eye and of course the most dreaded complication of the eye is diabetic retinopathy (DR) [1]. DR is the unexceptional diabetic eye disease and it is foremost of getting blindness. Change in the blood vessels of the retina is the main spring. Retina is the light sensitive tissue at the back of the eye. A healthy retina is necessary for good vision. In some people with DR blood vessels of the retina may swell and leak fluid or blood. In other people with diabetes, abnormal new blood vessels grow on the surface of the retina. The normal and diabetic retina is shown in the figure 1.

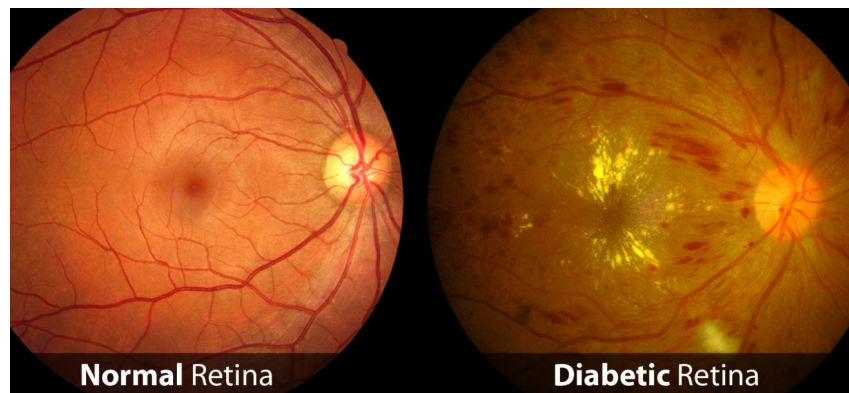


Fig. 1 Normal and diabetic retinopathy retinal image

At first diabetic retinopathy may not germ any changes to your vision. But over time, diabetic retinopathy can get inadequate. Initially, a person might see spots floating in their vision, or may notice a general blurring of vision. In due course DR may cause vision loss and even blindness. Early on patients may have no symptoms and by the time they have symptoms it's already to late because the damage is already extensive. So the early treatment of diabetes helps preserve vision and early treatment of DR to keep viewing.

One form of diabetic retinopathy is called Non proliferative diabetic retinopathy or NPDR, it occurs when diabetes damages small blood vessels within the retina, these vessels start to leak both fluid and blood gradually causing the retina to thicken or swell over time the swelling or edema thickens the retina causing the vision to become blurred. One more form of diabetic retinopathy is called Proliferative diabetic retinopathy PDR[2], it occurs when new and fragile blood vessels grow abnormally from the retina into the vitreous this can result in bleeding, scarring and contraction of the vitreous which may lead to retinal detachment. PDR can cause severe vision problems and it can even lead to blindness, it must be treated as soon as possible.

Fundus is nothing but capturing the rear part of the eye using the specialized camera called fundus cameras. The parts which are seen on the fundus photo are the central and peripheral retina, optic disk and macula. Usually fundus photos are colour filters [3]. The images captured through the fundus camera are called fundus images and these images are used for the research.

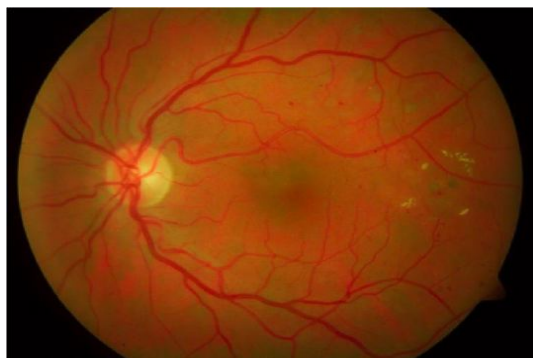


Fig. 2 Retinal image having exudates

In the people who have DR, exudates form in the retina of the eye. Exudates is the fluid that leaks out of the blood vessels into nearby tissues. This fluid is nothing but made up of the cells, proteins and solid materials. Exudates may ooze from cuts or from areas of infection or inflammation. It is known as pus. The exudates may be of 2 forms soft and hard exudates. Hard exudates are the one which are small white or yellowish white deposits with margins sharp. Often they are shiny and waxy. Soft exudates are nerve fiber layer infarcts or pre capillary arterial occlusions and they are referred as cotton-wool spots[4]. Usually these exudates are similar to that of the optic disk present in the fundus images because both optic disc and exudates have the same color intensity as shown in the figure 2. The differentiating between the exudates and optic disk is hard. Hence detecting the exudates from that of the optic disk is the critical part so the detection of the exudates are being researched from 2000 and its going on still now.

## II. LITERATURE SURVEY

DiaRetDB0, DiaRetDb1 and HRF database for detecting hard exudates, he initially normalizes the image using 9\*9 median filter and gamma correction. And he selected green channel for further process and used CLAHE technique to enhance the contrast of image. Global threshold is found based on peaks of histogram and to detect the OD (optic disc) 3\*3 median filter was used and OD was masked by binary mask. then only exudates were remained. The region growing algorithm is used to detect the bigger exudates. Finally specificity 88.46% and sensitivity 94.59% was found for the gamma value 0.49.

Anitha Gnanaselvi J [2], here the author used STARE database where 50 images is present. Gaussian filtering method is used for contrast enhancement. For segmentation, the three ways are used namely edge detection, thresholding and region based segmentation. Later for feature extraction, texture feature extraction technique is used which combines both histogram of gradient with gray level occurrence matrix. For classification, KNN and CNN are used. The accuracy of 98% is seen in CNN method compared with other methods.

Kranthi kumar Palavalasa[3], in this paper the author has used DiaretDb1 database 89 images and DiaretDb0 database 130 images, at first HSV is selected, median filter was applied to remove the noise, then the images are normalized using gamma values. To detect the exudates, initially intensity level of green channel histogram of normalized image was considered. Then the OD is detected using CLAHE method, using morphological operation the non-exudates is suppressed then using region growing algorithm the exudates are detected. Finally the sensitivity they found is 87%.

Ravi M. Kamble [4], he used delta-rank transform, In this paper, E-Ophtha and DiaretDb1 are the 2 datasets with 148 and 89 images having the resolution 512\*512 used. The dark and bright lesions edges from fundus images having a different intensity against the background, so the local rank transform(LRT) is defined. Here the detection of exudates is done using Retinal anatomic structure removal where the OD is detected automatically using the line scanning based localization method then its removed and in Final exudates detection the noise is removed using median filter operation and the delta value is assumed to be 15. finally the accuracy detected was 95.44%(e-ophtha and 97%(diaretDb1) dataset. The loophole of this method is sensitive to noise in the color picture.

Adeel M. Syed [5] here the dataset used are DRIVE, DIARETDB1, MESSIDOR, AFIOS(Armed forces institute of ophthalmology). The initial step used here is the thresholding followed by morphological operation for separating the foreground from that of background region, the next step is making the contrast enhancement using histogram equalization and to cater the noise CLAHE is used and next to detect the exudates segmentation is done and OSTU's algorithm is used to remove the OD. In extraction of the features, the green component and red component with mean, maximum and minimum intensity. Finally the classification used here is SVM and later after detection of exudates the ALBASR named embedded real time system is implemented.



Sangita Bharkad [6], here author used DIARETDB0 and DIARETDB1 database with 30 and 49 images. Initially the green component is selected for color processing. Since there is no proper intensity classification between OD and hard exudates, the OD is removed using morphological operators and masking of the OD. Then feature is extracted using neural network and finally the accuracy he got is 97.46%.

Z.A.Omar [7], here the author used DIARETDB1 database in which there were 130 images in that 89 images are trained and 49 images are tested, He used Median filter on 5\*5 kernel for noise reduction, CLAHE(Contrast limited adaptive histogram equalization) method was used to improve the image contrast, for segmentation top-hat operation and closing operation are used, For feature extraction the optic disc is located using contour detection method, and then the OD is removed based on the shape and size. Later the detection of exudates is based on radius of the contour which is having the OD radius greater than 30 pixel and the exudates are detected using morphological closing operation. So finally the exudates were detected 100%, but the main limitation is that he has used manual screening.

Santhakumar R [8], here the author initially removes optic disc and background region using fundus mask by segmenting the OD region. The feature is extracted for patches from all the color channels using histogram, statistical measure, color model and texture features. Later PCA is used for visualizing the feature. Patch level classification is used for classification and regression, it uses multiclass SVM classifier algorithm maps the feature vector using kernel. Exudates are detected with 94% accuracy.

Enrique V. Carrera [9], here the author uses 400 retinal images for detecting the exudates, initially for blood vessels M component is selected from CMY, Microaneurysms G component is selected, hardexudates M component is selected and OD is found using M component therefore histogram matching is used to find OD, for segmentation threshold is found manually. For feature extraction green component entropy is found. And finally the accuracy of SVM and decision tree is found where finally SVM is found better than others.

Ambaji S.Jadhav[10], in this the author has used STARE dataset and he has proposed the system which starts from inputting the dataset. The image is converted to grayscale, then the noise removal is done using non-linear digital filter called median filter, then the segmentation is done using adaptive histogram equalization later the blood vessel segmentation is detected using wavelet transform, OD is detected using the area thresholding and the exudates are detected by morphological closing operator.

Pranjali Kokare [11], she used dataset DIARETDB0 which contains 130 images, the proposed method is that the image divided into 3\*3 equal size of non overlapping blocks and each block is decomposed using wavelet transform to spatial frequency. In turn to detect exudates the wavelet coefficient threshold evaluation function and the median filter is applied using 7\*7 window to remove noise in the image. Finally the sensitivity and specificity is 86.66% and 83.05% respectively.

Shuang Yu [12], here, the database used is E-Ophtha EX which contains 82 images with 1440\*960 to 2544\*1696 pixels. Initially the images are converted to green component in order to remove the optic disc and blood vessels using image processing and finally an algorithm called seed points is used to obtain the exudates. Then these points are sent to the deep learning model to identify the exudates. The sensitivity is increased by 91.92% from 74%.

Kittipol Wisaeng [13], he used the database used is DIARETDB1. Initially the images are normalized using histogram specification method, for contrast enhancement local contrast enhancement is used, for noise removal the median filtering operation is used, finally the OD is removed by binary masking using 0.68 value as threshold, for the segmentation purpose the Mean shift with node weights(MSA) to detect the exudates. Finally the proposed method has accuracy 98.40%.

Dinial Utami Nurul Qomariah and Handayani Tjandrasa [14], here author used DIARETDB1 database which had 89 images. He proposed method which uses thresholding adaptively for segmentation of exudates for determining the values in retinal images. Initially the image is converted to LUV channel, then segmentation is done using the morphological transform where initial detection of exudates is done where the threshold is found using renyi entropy thresholding to get the final segmented exudates, using the rho value threshold was detected. Once exudates are detected the OD is eliminated using dilation morphology method. Finally the accuracy of proposed method was 99.54%. Here the disadvantage was that rho value was annually calculated.

Worapan Kusakunniran [15], he used e\_ophtha and DIARETDB1 datasets which has 82 images. He proposed framework which had 3 stages. First step is preprocessing, where color channels selection is done using mean and standard deviation. Second stage is used to detect hard exudates based on shape, size and color using threshold value. And finally exudates segmentation is done using graph cut method. Therefore the proposed method outperforms measurement in both pixel and image level than other method.

Mohammed shafeeq Ahmed and Baddam Indira[16], here the author used 26 images were taken as the database from Basaveshwar teaching and general hospital. Here eliminate the OD through transform method is used, then the color adjustment is done to enhance the exudates in the image. Manually the exudates intensity is calculated for red and green component, then 3\*3 value is calculated

where the range is used to specify exudates and non-exudates pixel, and this method is used to train 15 images. Therefore here manual calculation is more which leads to disadvantage.

W. Zhou [17], he used two public database DIARETDB1 and e-optha EX having 47 retinal images with exudates. He used SMFC method for detection of exudates where he initially processed image to normalization illumination, then he used SLIC method to extract candidate, FDA issued as linear classifier to classify exudates candidates, finally exudates and non exudates candidate is distinguish using post processing. He got the result of accuracy 0.97 and 0.965 for the 2 database used.

### III.COMPARISON OF EXISTING ALGORITHMS

The success of algorithms in detecting exudates and the different algorithm are compared and briefly shown in table 1. As we can see below in the table1 that authors have used many algorithms and techniques and got result in terms of accuracy, sensitivity and specificity. Here we can see the accuracy varies as algorithm changes. The algorithms used are usually image processing and Machine learning and technique used are SVM, Neural network, Mean shift, Renyi entropy threshold and so on. They even have drawbacks as mentioned in the table I.

Let's have a look on each algorithm used in the comparison table. Firstly image processing is an algorithm which is used to enhance the image and to get the information of image. Here the processing of image is easier and quite faster. It is implemented with computer algorithms where the image sensors are converted to digital image and enhance the image clarity and removal of noise. And here many of the papers have used image processing for detecting exudates.

As image processing has many techniques like, image acquiring, color conversion, background extraction, enhancement of image, histogram analysis, segmentation, feature extraction, image filtration and transition. Kittipol Wisaeng et.al,[13] used morphology mean shift algorithm while performing segmentation technique, its good that model-free, where it doesn't assume any shapes before like spherical, square, elliptical and so on but the drawback is that computationally expensive and depends on windows size. And using this technique the exudates are detected with accuracy of 98.35% as shown in figure 3(i,ii) where a is RGB color model and b is the output with exudates seen.

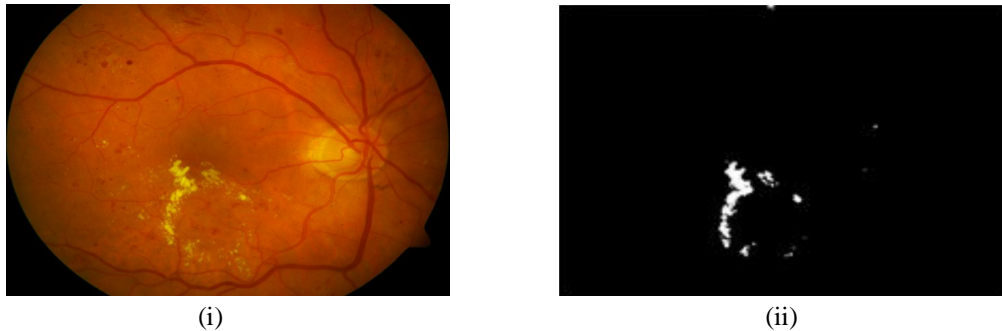


Fig. 3 (i) Retinal color image (ii) Exudates detected image

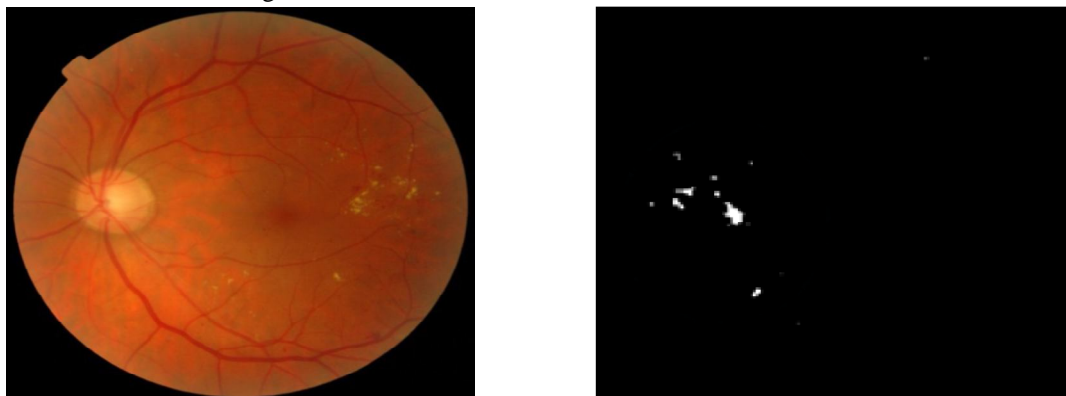
Ravi M. Kamle[4] he also used image processing technique to detect bright and dark lesions. He used local rank transform(LRT) both positive and negative delta-LRT where he chose delta value to be 15 and detected lesions with 97% but the drawback in this paper is that robustness against the noise.. the output image is shown in figure 4(i,ii) using delta transform.

Enrique et.al[9] he used Machine learning technique to find exudates automatically, he used linear kernel function in the SVM algorithm to detect Diabetic retinopathy non-proliferative (DRNP) with accuracy of 95% but the drawback is that Choosing kernel function is complex and it drastically slow down the speed of training data and the output is shown in figure 5(i,ii).

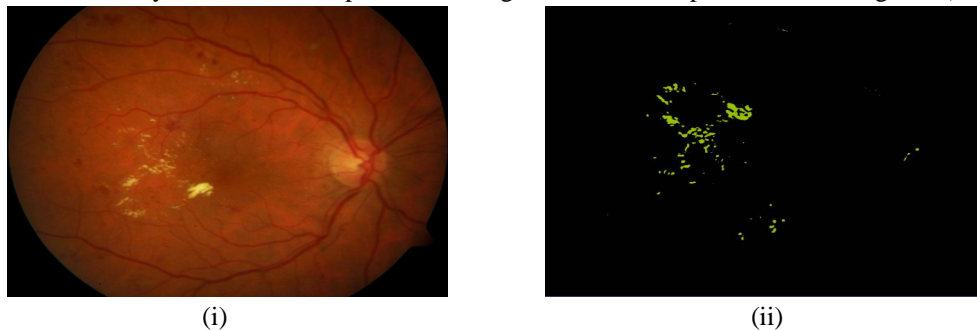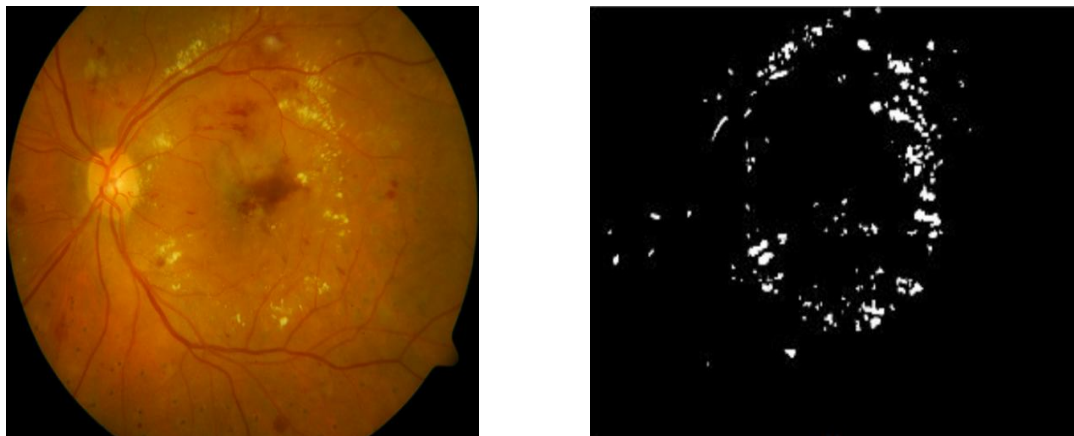


Fig. 4 (i) Retinal color image (ii) Exudates detected image

Dinial Utami Nurul et.al,[14] , he used image processing technique with combination of morphology and renyi entropy threshold algorithm to get optimal threshold value so to detect exudates automaticall with 99% accuracy shown in figure 6(i,ii) and drawback of this paper is Rho value for thresholding is not automatic.

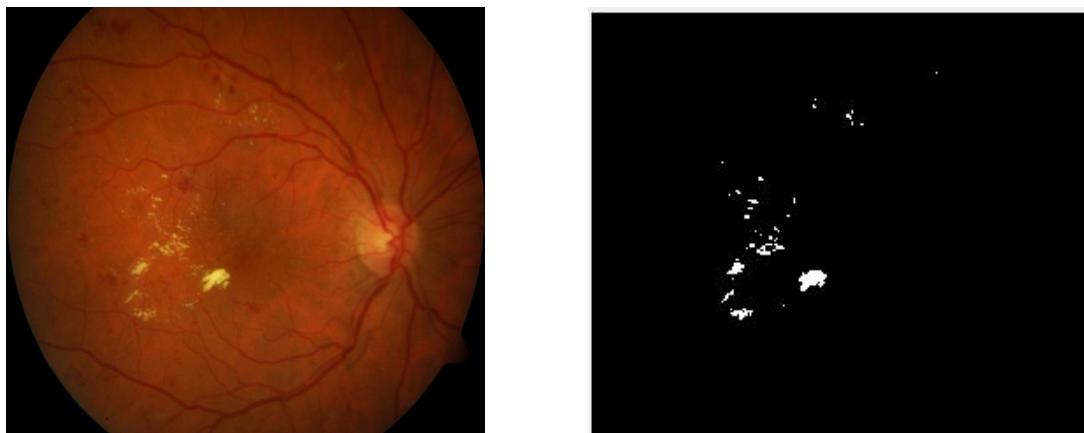


(i) (ii)  
Fig. 5 (i) Retinal color image (ii) Exudates detected image



(i) (ii)  
Fig. 6 (i) Retinal color image (ii) Exudates detected image

Dulanji Lokuarachchi et.al[1], he used image processing technique with gamma correction in preprocessing step and got sensitivity 94.59% taking gamma value as 0.49 shown in figure 7(i,ii) and the drawback of this paper is accuracy is less.



(i) (ii)  
Fig. 7 (i) Retinal color image (ii) Exudates detected image

#### IV. PROPOSED IDEA

As in the comparison, on algorithms research were done using image processing and machine learning algorithms. There we saw that using only image processing with different techniques like Gamma correction, Combination of morphology and renyi thresholding, delta-transform, morphology mean shift and so on had some drawbacks like less in accuracy, manual threshold values, window size is trivial and so on. These are some drawbacks with the image processing alone. When it comes to machine learning algorithm which is known for best algorithm for detection. In machine learning there are different algorithm or technique used like SVM, KVM, Neural network, CNN and so on. Here using machine learning alone as a classifier as some disadvantages like Choosing kernel function is complex and it drastically slow down the speed of training data so the accuracy goes down.

Hence using machine learning alone like a classifier sometimes gives less accuracy value and image processing alone also gives less and this SVM algorithm used in some paper are supervised learning. Therefore using both this algorithm that is image processing and machine learning algorithm together where in machine learning only regression is used might give the better result in terms of accuracy and reduce false negative results. Here to achieve the result, datasets used are DiaRetDB0, DiaRetDB1, MESSIDOR and IDRiD. And will be done using Python IDE software with system requirements Pentium dual core, hard disk of 120 GB and ram of 2 GB.

TABLE I  
COMPARISON OF ALGORITHM

Sl.No	Algorithm-Technique	Result	Drawback
1	Image processing - Gamma Correction technique[1]	Gamma value- 0.49 Specificity- 88.46%. Sensitivity- 94.59%	Accuracy is less
2	Image processing - Morphology mean shift algorithm[13]	Accuracy – 98.35% Specificity- 98.13%. Sensitivity- 98.40%	Window size is not trivial
3	Image processing – Delta-Rank Transform[4]	Accuracy – 97%	Robustness against the noise
4	Image processing and Machine learning – SVM[9]	Accuracy -95% Sensitivity – 85%	Choosing kernel function is complex and it drastically slow down the speed of training data.
5	Image processing- mathematical morphology and entropy threshold [14]	Accuracy – 99.54% Specificity- 99.63%. Sensitivity- 85.06%	Rho value for thresholding is not automatic.

#### V. CONCLUSIONS

The papers surveyed here provide highest accuracy possible. However, it seems that most of the papers reviewed have worked on similar contrast based images. Thus the need of the day would be to devise an algorithm which can learn the contrast of the images and adjust its parameter by itself. This helps in increasing the accuracy and in turn reducing the out coming false negatives.

#### REFERENCES

- [1] Dulanji Lokuarachchi, Kasun Gunarathna, Lahiru Muthumal and Tharindu Gamag,e“Automatic detection of exudates in retinal images”, IEEE 15th International Colloquium on Signal Processing & its Applications (CSPA 2019), Penang, Malaysia ,8 -9 March 2019.
- [2] Anitha Gnanaselvi J and MariaKalavathy G, “Detecting hard exudates in retinal fundus image using convolution neural networks”, IEEE International Conference on Current Trends toward Converging Technologies, Coimbatore, India, Proceeding of 2018.
- [3] Kranthi Kumar Palavalsa and Bhavani Sambaturu, “Automatic diabetic retinopathy detection using digital image processing”, International Conference on Communication and Signal Processing, April 3-5, 2018, India.
- [4] Ravi M. Kamle, Bukhari Aujith, Manesh Kokare and Fabrice Meriaudeau, “Detection of bright and dark lesions from color fundus images using Delta- Rank Transform”, International Conference on Intelligent and Advanced System (ICIAS) 2018.
- [5] Adeel M. Syed et al. “Robust detection of exudates using fundus images”, 2018 IEEE
- [6] Sangita Bharkad, “Morphological and neural network based approach for detection of exudates in fundus images” Proceedings of the Second International Conference on Computing Methodologies and Communication (ICCMC 2018).
- [7] Z. A. Omar, M.Hanafi, et al.“Automatic Diabetic Retinopathy Detection and classification system” 2017 7th IEEE International Conference on System Engineering and Technology (ICSET 2017).



- [8] Santhakumar R, Megha Tandur et al. "Machine learning algorithm for retinal image analysis" IEEE Region 10 Conference (TENCON) — Proceedings of the International Conference 2016.
- [9] Enrique V. Carrera, Angres Gonzalez and Ricardo Carrera "Automatic detection of diabetic retinopathy using SVM" IEEE K. Elissa, "Title of paper if known," unpublished, 2017.
- [10] Ambaji S. Jadhav and Pushpa B. Patil, "Detection of exudates for diabetic retinopathy using wavelet transform", IEEE International Conference on Power, Control, Signals and Instrumentation Engineering (ICPCSI-2017).
- [11] Pranjali Kokare, "Wavelet based automatic exudates detection in diabetic retinopathy", IEEE WiSPNET conference 2017.
- [12] Shuang Yu, DI Xiao and Yogensa Kanagasingam, "Exudate detection for diabetic retinopathy with convolution neural networks" IEEE 2017.
- [13] Kittipol Wisaeng and Worawat SA-NGIAMVIBOOL "Exudates detection using Morphology mean shift algorithm in retinal images" 10.1109/ACCESS.2018.2890426, IEEE Access
- [14] Dinial Utami Nurul Qomariah and Handayani Tjandrasa, "Exudate detection in retinal fundus images using combination of mathematical morphology and renyi entropy thresholding", International Conference on Information & Communication Technology and System (ICTS) 2017.
- [15] Worapan Kusakunniran, Qiang Wu, Panrasee Rittipravat and Jian Zhang, "Three-stages hard exudates segmentation in retinal images", 9th International Conference on Information Technology and Electrical Engineering (ICITEE), Phuket, Thailand 2017.
- [16] Mohammed shafeeq Ahmed and Baddam Indira "Detection of exudates from RGB fundus images using 3 $\square$  control method " IEEE WiSPNET Conference 2017
- [17] Wei Ahou, Chengdong Wu, Yugen Yi and Wenyou Du, "Automatic detection of exudates in digital color fundus images using superpixel multi- feature classification", 2169-3536 2017.





10.22214/IJRASET



45.98



IMPACT FACTOR:  
7.129



IMPACT FACTOR:  
7.429



# INTERNATIONAL JOURNAL FOR RESEARCH

IN APPLIED SCIENCE & ENGINEERING TECHNOLOGY

Call : 08813907089  (24\*7 Support on Whatsapp)