



IJRASET

International Journal For Research in
Applied Science and Engineering Technology



INTERNATIONAL JOURNAL FOR RESEARCH

IN APPLIED SCIENCE & ENGINEERING TECHNOLOGY

Volume: 8 Issue: VI Month of publication: June 2020

DOI: <http://doi.org/10.22214/ijraset.2020.6244>

www.ijraset.com

Call:  08813907089

E-mail ID: ijraset@gmail.com

Periodontal Ligament: Role of Fibroblast in Periodontal Healing

Dr. Kousain Sehar¹, Dr. Navneet kour², Dr. Nadia Irshad³, Dr. Mir Tabish Syeed⁴, Dr. Hilal Ahmad Hela⁵, Dr. Manju Verma⁶

^{1,2}MDS Dept of Periodontology and Implantology, BRS Dental College and Hospital Sultanpur Panchkula.

^{3,6}MDS Dept of Paedontics and Preventive Dentistry, BRS Dental College and Hospital Sultanpur Panchkula.

⁴MDS Dept of Paedontics and Preventive Dentistry, Swami Devi Dayal Hospital and Dental College, Barwala,

⁵MDS Dept. of Prosthodontics, Govt Dental College and General Hospital, Srinagar.

Abstract: *The periodontium is a connective tissue organ, covered by epithelium that attaches the teeth to the bones of the jaws and provides the continually adapting apparatus for support of teeth during function. The periodontium comprises four connective tissues, two mineralized and two fibrous. The two mineralized are cementum and alveolar bone; the two fibrous are: periodontal ligament and lamina propria of gingiva.*

Keywords: *Connective tissue, lamina propria, Periodontium*

I. INTRODUCTION

FIBROBLASTS are the principal cell type in the fibrous connective tissues of the periodontium. They perform important functions in development, physiology, disease and treatment of the fibrous connective tissues of the periodontium.

Fibroblasts have important roles in the development, structure, and function of the tooth support apparatus.¹ Fibroblasts synthesize and remodel extracellular matrices including collagen and elastin fibres and a large complement of nonfibrillar glycoproteins. These cells also exhibit contractility and motility, functions that contribute to the structural organization of the tissue, especially during development of the periodontal ligament. As the fibroblast is the major cell type in the periodontal connective tissues, it plays a significant role in normal turnover, repair, and regeneration. In connective tissue remodeling, fibroblasts are capable of the synthesis and phagocytosis of collagen and components of extracellular matrix and also produce cytokines with the capacity to mediate tissue destruction and to stimulate osteoclastic bone resorption. For example, matrix metalloproteinase - 1 is a fibroblast/macrophage derived enzyme with the ability to degrade extracellular matrix collagen at physiological pH and temperature.² Fibroblasts and other tissues of mesodermal origin are also capable of secreting tissue inhibitors of metalloproteinases. Collagenolytic inhibitors in periodontal tissues may have a regulatory role in modulating connective tissue degradation and are found in high concentrations at healthy periodontal sites. These examples underline the central role that fibroblasts play in remodelling of periodontal tissues including the PDL.

In soft connective tissues such as healthy periodontal ligament or gingiva, fibroblasts are by far the most numerous stromal cell types.³ Fibroblasts are cells of mesenchymal origin and play a major role in the development, maintenance and repair of the periodontal connective tissues. An emerging concept is that fibroblasts are not homogenous, but instead consist of subsets of cells which can regulate bone marrow derived cells such as lymphocytes. Though evidence indicates many different subtypes of fibroblasts, the principal function of these cells is to synthesize and maintain the components of the extracellular matrix of the connective tissue. This feature seems to be consistent for all types of fibroblasts⁴, with variation in the types and amounts of matrix proteins synthesized occurring according to the tissue of origin, as well as localized functions of the cells within the tissues. These cells and their extracellular matrix products play pivotal roles in maintaining the structural integrity of connective tissues, in healing process, and in pathological alterations. Following injury to the tissues, wound healing requires the recruitment of cells with regenerative capacity to the site in order for tissue repair or regeneration to occur. The ability of fibroblasts to proliferate, migrate, elongate, adhere, immobilize itself and commence matrix synthesis is critical for cell function and tissue integrity.⁴

It is also possible that the periodontal ligament fibroblasts are motile contractile cells and that they are capable of generating a force for tooth eruption.⁵ In vitro, periodontal fibroblasts can organize a fibrous network and can generate significant forces.⁶

While gingival fibroblasts maintain the synthesis and integrity of the gingival connective tissue, periodontal ligament fibroblasts have specialized functions which are concerned with the formation and maintenance of the periodontal ligament including its repair or regeneration following damage.⁷

A. General Structure Of Fibroblasts

The principal cell in the lamina propria of oral mucosa and the periodontal ligament is the fibroblast, which is responsible for the elaboration and the turnover of fibres and ground substance. The fibroblast thus plays a key role in maintaining tissue integrity.

Under the light microscope, the fibroblasts are cigar-shaped (fusiform) or star shaped (stellate) with long processes that tend to lie parallel to bundles of collagen fibers and are not easily visible with the light microscope. Fibroblast nuclei contain one or more prominent nucleoli.

Ultrastructurally the fibroblasts have the characteristics of active synthetic cells, including numerous mitochondria, an extensive granular endoplasmic reticulum, a prominent golgi complex and numerous membrane bound vesicles. Fibroblasts have a low rate of proliferation in adult mucosa except in wound healing, when their numbers increase because of cell division in the adjacent uninjured tissues.

The periodontal ligament fibroblasts are large cells with an extensive cytoplasm containing abundance of organelles associated with protein synthesis and secretion. They have a well developed cyto-skeleton. They also show cell - cell contacts of the adherens and gap junctions types. They are aligned along the general direction of the fiber bundles and have extensive processes that wrap around the bundles.

B. Functions of The Fibroblasts

- 1) Synthesis and deposition of the extracellular matrix¹
- 2) Tissue turnover and remodeling during various physiological and pathological processes¹
- 3) Tissue integrity and homeostasis⁸
- 4) Wound healing- fibroblasts can become contractile and participate in wound contraction, in which case they develop intracytoplasmic actin filaments.
- 5) Chemotaxis and phagocytosing foreign objects and ingesting cross-linked collagen; Regulating local inflammatory responses⁹
- 6) Modulating behavior of neighbouring tissues and cells i.e., cell-cell interactions with epithelium¹⁰ and lymphocytes¹¹
- 7) Periodontal Regeneration

In addition to well-described structural and functional similarities (e.g., collagen and fibronectin synthesis, vimentin intermediate filaments, t_3 -actin), fibroblasts exhibit considerable variation of cytoskeletal proteins (e.g., α -smooth muscle actin expression¹²), surface markers (e.g., Clq receptors), and size¹³ that suggest the existence of discrete cellular subsets. Variants have been described both within a localized site (e.g., gingiva)^{14, 15} and between sites from different anatomical locations. It has been previously suggested that regulation of fibroblast populations in both steady-state and pathological conditions is essential for a profound understanding of basic processes involved in health and disease.¹⁶

The development of the periodontal ligament fibroblasts is mainly from the dental follicle cells while the majority of fibroblasts of the gingiva develop from the embryonic ridge mucosa.

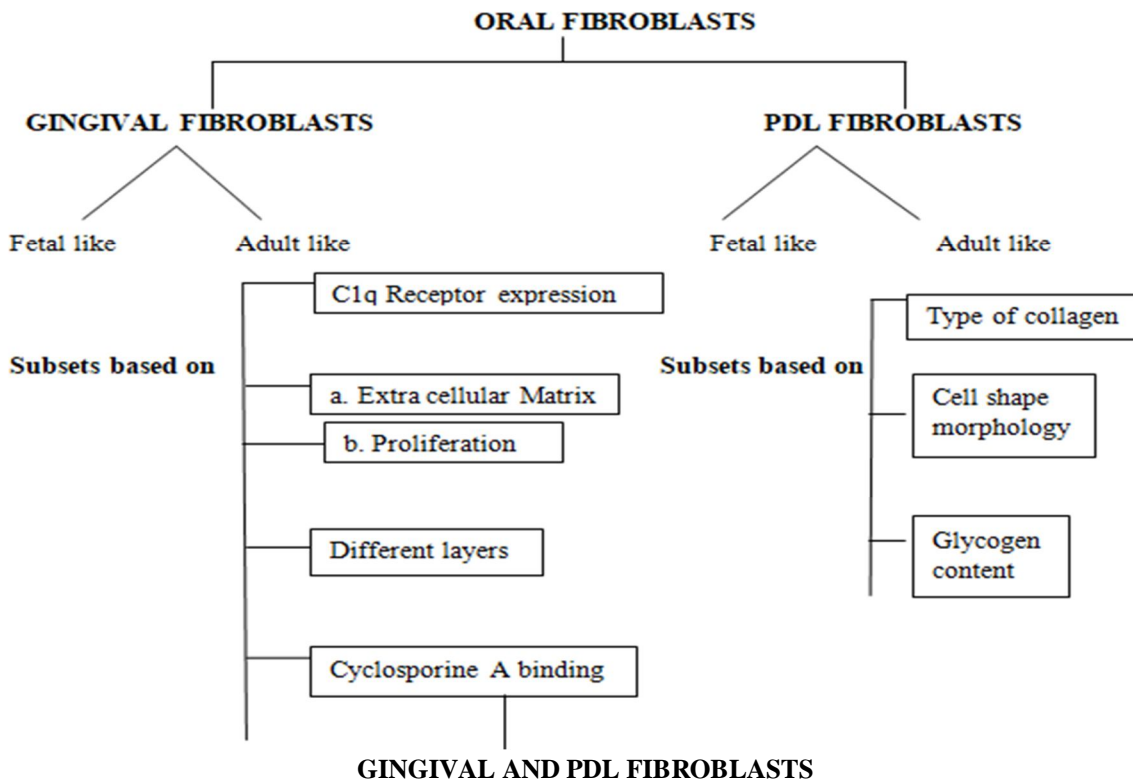
Gingival Fibroblasts originate from the vessels of the gingival plexus, seep through the connective tissue, and pass through the junctional epithelium.

There are essentially two types of periodontal fibroblasts by their tissue localization.

- a) The GINGIVAL FIBROBLASTS construct the soft connective tissue which surrounds the alveolar bone. These fibroblasts produce and maintain the extracellular components which provide for the integrity of the tissue.
- b) The PERIODONTAL LIGAMENT FIBROBLASTS produce the connective tissue attachment which firmly anchors the tooth to the alveolus. Collagen is the main structural component and the periodontal ligament fibroblast is responsible for the rapid and extensive remodeling of the attachment fibers.

In earlier years, periodontal fibroblasts had been thought to be static cells with a common spindle-shaped morphology. It is now appreciated that the periodontal fibroblasts are heterogenous and dynamic. This was first described by Hassel and Stanek¹⁷ in 1983 in healthy human gingiva, where fibroblasts grown from the single biopsy of the papilla tip displayed differences in size, proliferation rate and replicative life-span in vitro. Since then two major themes are generally considered in analysis of fibroblasts from periodontal tissue.

- i) Fibroblasts from different areas of the periodontium, namely PDL and gingiva, are different.
- ii) Within each of these specialized tissue there are likely to be multiple subsets of fibroblasts.



RESTING FIBROBLASTS

Elongated Cell
 Little cytoplasm
 Flattened nucleus
 Condensed chromatin

ACTIVE FIBROBLASTS

Oval cell
 Greater amount of cytoplasm
 Pale staining nucleus
 Numerous cell organelles

Gingival fibroblasts	Periodontal ligament fibroblasts	Authors /year
Smaller in size. Poorly developed cytoskeleton. Less/no actin Filaments	Large cells with extensive cytoplasm and cell organelles. Well developed cytoskeleton. 3-fold higher F- actin and smooth muscle myosin.	Pender and McCulloch 1991 ¹⁸ Rose et al 1987 ¹⁹
Healthy cells showed greater proliferative activity	Lesser proliferative activity	Larjava et al., 1989 ²⁰
Low rate of production of collagen type I and III Healthy cells show no EGF receptors	Greater rate of production of collagen type I and III EGF receptors present	Hou and Yaeger, 1993 ²¹ Matsuda et a., 1993 ²²
Release larger amounts of PGE ₂ in response to histamine and bradykinin	Minimal amounts of PGE ₂ in response to histamine and bradykinin	Okada et al 1995 ²³
Alkaline phosphatase activity not found	Alkaline phosphatase activity found in larger fraction which respond to cemental derived mitogens differently.	Giannopoulou and Cimasoni, 1996 ²⁴ , Groeneveld et al., 1995 ²⁵
Propagated cells unable to regenerate PDL	Active regeneration	Boyko G , Melcher A et al 1981 ²⁶
Osteopontin and guanidine/EDTA extracts preferentially promote attachment of GF	Cemental attachment protein promotes greater migration and attachment to roots with PLF	Pitaru et al 1995 ²⁷ Somerman et al 1989 ²⁸

C. Fetal And Adult Fibroblasts²⁹

Fibroblasts, functioning in their dual capacity as structural component and modulator of tissue function, play a key role in determining developmentally-dependent and site-specific differences in wound healing. For example, dermal wound healing in the adult is commonly accompanied by scar formation, which on occasion, may be excessive and disfiguring. In contrast to this reparative process, wound healing in the early gestation fetus is generally not accompanied by scarring and essentially regenerative in nature.³⁰ Fetal and adult fibroblasts display a number of differences in phenotype which are consistent with their contribution to these distinct modes of wound healing. Fibroblasts isolated from adult tissues display considerable site-specific heterogeneity in phenotype which may again be causally related to corresponding inter-site differences in wound healing. In this regard, dental surgeons have long recognised that the oral mucosa appears to be a privileged site in the adult in that it tends to display a ‘fetal-like’ pattern of regenerative and scarless wound healing.³¹

FETAL FIBROBLASTS	ADULT FIBROBLASTS	AUTHOR
Fewer Myofibroblasts	Greater proportion of Myofibroblasts transdifferentiation	Estes et al 1994 ³²
TGF β_3 isoform of cytokine secreted – reduced scar formation	TGF β_1 and TGF β_2 isoform of cytokine secreted	Sullivan et al 1993 ³³
Hyaluronan abundant – scarless nature of wound healing	Transient increase in Hyaluronan during healing	Krummel et al, 1987 ³⁴
The coordinated movement of fetal epidermal cells and fibroblasts to close the wound involves the contraction of a ‘purse string’ of actin cables which form within a single row of basal cells encircling the periphery of the wound	Epithelial movement during the closure of adult wounds involves the formation of lamellipodia of fibroblasts	Martin and Lewis, 1992 ³⁵
Produces soluble Migration Stimulating Factor (MSF)	Not produced	Schor et al, 1988 ³⁶

Taken together, these various observations have led to speculation that developmentally-regulated changes in fibroblast phenotype (with respect to such parameters as matrix synthesis and cytokine response) may play a central role in defining differences in the modes of fetal and adult wound healing.³⁷

Studies have indicated that the periodontal ligament and gingiva display a number of fetal-like characteristics^{38, 39}; these include a high rate of collagen turnover, unimodal collagen fibre diameter, the relative abundance of type III collagen and glucuronate-rich proteoglycans, high cellularity and the presence of numerous intercellular contacts between fibroblasts.

D. Sub-Populations of Fibroblasts (Fibroblast Heterogeneity)

According to Leblond et al., 1959⁴⁰ cell populations have been tentatively categorized as expanding, static and renewing. Renewing cell systems contain populations of stem cells which, upon mitosis, produce more differentiated progeny. The daughter cells have a more limited repertoire of protein expression and ultimately undergo a series of cell divisions to produce a functionally specialized cell. The stem cells of a particular tissue undergo self-renewal at mitosis to maintain their own numbers and to generate more specialized cells that maintain the essential characteristics of the tissue phenotype. Thus, the more differentiated progeny of stem cells both amplify cell number and exhibit more delineated, specialized functions. Since the periodontium is a complex structure that requires diverse cell populations to provide ongoing function, including remodeling for functional adaptation and repair, it is perhaps not surprising that the fibroblasts of the periodontium are part of a renewing, steady-state cell population. Since steady-state renewal cell systems must have a built-in system to maintain a constant number of cells, it is notable that the periodontium also contains apoptotic fibroblasts in numbers comparable with those generated by proliferation. In periodontal tissues, the deletion of cells by apoptosis provides a balancing mechanism to maintain the numbers of specific cell types at constant levels. In the periodontium, the most primitive progenitor cells are found in paravascular sites of the periodontal ligament^{41, 42} and in gingiva.⁴³ The progeny of these cells migrate to extravascular sites, where they presumably contribute to tissue turnover and repair. In addition, the periodontal ligament may be enriched with progenitors from adjacent endosteal spaces of alveolar bone. Migration of fibroblasts in the periodontal ligament seems to be directed from the central progenitor zone toward both bone and tooth and in an

apico-coronal direction. Notably, a putative cemental attachment protein promotes preferential migration of human periodontal ligament fibroblasts toward root surfaces when compared with human gingival fibroblasts, suggesting a general mechanism to induce selective migration. Although migration patterns have yet to be established for gingival tissue, they may be similar to those of periodontal ligament. Consistent with the notion that paravascular sites are enriched with primitive precursors exhibiting the characteristics of stem cells, the paravascular cells exhibit slow cell-cycle times, clonal proliferation, and migration of labeled cell clusters to extravascular sites both in the periodontal ligament and in gingiva. The observed clonal proliferation, label dilution, and migration to extravascular sites suggest that these transit cell populations are indeed amplifying and may be undergoing differentiation as the cells migrate away from blood vessels. In gingiva, the slowly cycling population appears limited to the supracrestal region. However, it is evident that mixed populations of progenitors may be present at the tip of the interdental papilla, since human gingival fibroblasts grown from biopsies at this site show large variations of proliferative capacity *in vitro*: indeed, the variations in proliferation rates between mass cultures from one subject and from pairs of monozygotic and dizygotic twins indicate that there is as much heterogeneity of the progenitor populations within sites as between sites. This supposition is supported by evidence from a double labeling study of hamster gingiva in which at least 2 different classes of progenitor cells were identified on the basis of proliferative capacity *in vivo* and *in vitro*.⁴⁴ Collectively, these data indicate that fibroblasts in the periodontium are renewed continuously by several different classes of cells. These different classes can be distinguished on the bases of proliferative capacity, location within the tissue structure, and likelihood of undergoing cell death.

II. FIBROBLASTS IN TREATMENT

A. Wound Healing⁴⁵

Traumatic injury causes capillary damage and hemorrhage and, as a result, a blood clot is formed. The formation of a clot is the immediate response to any trauma. The clot has two functions: it temporarily protects the denuded tissues; and it serves as a provisional matrix for cell migration. The blood clot consists of all cellular components of blood (including red and white blood cells and platelets) in a matrix of fibrin, plasma fibronectin, vitronectin, and thrombosporin. Clot formation is followed by an early stage of inflammation. Within hours of injury, inflammatory cells (predominantly neutrophils and monocytes) populate the clot. These cells cleanse the wound of bacteria and necrotic tissue through phagocytosis and release of enzymes and toxic oxygen products. Within 3 days, the inflammatory reaction moves into its late phase. Macrophages migrate into the wound area and, in addition to wound debridement, secrete polypeptide mediators targeting cells involved in the wound-healing process. The macrophage plays an important role in the formation of granulation tissue. Growth factors and cytokines secreted by macrophages are involved in the proliferation and migration of fibroblasts, endothelial cells, and smooth muscle cells into the wound area. The cell-rich granulation tissue next undergoes maturation and remodeling. Fibroblasts responsible for the replacement of the provisional extracellular matrix produce a new collagen-rich matrix. Approximately 1 week following wounding, and once the collagen matrix has been synthesized, some fibroblasts undergo transformation into myofibroblasts and express α -smooth muscle actin. This transformation and synthesis is responsible for wound contraction. Endothelial cells, responsible for angiogenesis, migrate into the provisional wound matrix to form vascular tubes and loops, and as the provisional matrix matures, the endothelial cells undergo programmed cell death (apoptosis) and the number of vascular units is reduced. Epithelization of the wound is initiated within hours of injury. Epithelial cells from the basal layer proliferate and migrate through the fibrin clot and eventually the breach in the epithelium is sealed. The epithelial cells in normal gingival tissues use surface receptors, known as integrins, to bind to laminin in the basal lamina. In order to initiate migration, the keratinocytes dissolve this attachment to start expressing integrins suitable for the wound environment.

B. Periodontal Wound Healing⁴⁵

A complex situation presents when a mucoperiosteal flap is apposed to an instrumented root surface which is deprived of periodontal attachment. In such case, wound margins are not opposing vascular gingival margins but comprise its rigid non vascular mineralized tooth surface, and on the one hand, the connective tissue and epithelium of the gingival flap. The periodontal wound also includes tissue resources from the formation at the interface between the tooth and a gingival flap is initiated as blood elements are imposed onto the root surface during surgery in a random manner representing the first healing event at the tooth–gingival flap interface followed by a fibrin clot attached to the root surface is developed. Within hours, the early phase of inflammation as inflammatory cells, predominantly neutrophils and monocytes, accumulate on the root surface, and within 3 days the late phase of inflammation dominates the healing picture as macrophages migrate into the wound followed by the formation of granulation tissue.

At 7 days, a connective tissue attachment may be seen at the root surface; however, areas of the fibrin clot in various stages of maturation may also be observed.

Hiatt et al examined the tensile strength of the tooth–gingival flap interface following reconstructive surgery of relatively small surgical dehiscence defects over the maxillary canine teeth in the dog. They found that the tensile strength increases from 200 g at 3 days postsurgery to 340 g at 5–7 days postsurgery, and to >1700 g at 2 weeks postsurgery.

This process of wound healing progresses through three phases which overlap each other and are interdependent⁴⁶

- 1) *Phase Of Inflammation*: It is characterized by increased vascular permeability and cellular infiltration of the wound site. Platelets are the first cells to be involved. Activation of platelets lead to the formation of the blood clot. This fibrin clot provides the provisional matrix for cell migration, which is further enhanced by the degradation of fibrin clot which are chemotactic to various cells involved in wound healing.
- 2) *Phase Of Demolition*: Poly morphonuclear neutrophils (PMN's) migrate into the clot by the process of chemotaxis within 24 hours. They remove dead and damaged tissues and foreign matter by phagocytosis within 24 hours. Keratinocytes migrate from the edges of the wound to form a fine covering over the wound area. During this process epithelial cells modify themselves to become migratory.
- 3) *Phase Of Formation Of Granulation Tissue Organization And Contraction*: Granulation tissue serves as an intermediate tissue, helps in angiogenesis and fibroplasia. It also prevents epithelial migration. Fibroblasts begin to migrate into the wound after day 1 and are transformed into myofibroblasts. These fibroblasts synthesize new matrix components and this conversion of fibrin clot is commonly referred to as organization. Wound contraction is brought about by the myofibroblasts residing in the granulation tissue. It reduces the wound to approximately 5% to 10%.

III. PHASE OF REMODELING

Newly formed granulation tissue matures and the connective tissue is remodeled. Apoptosis of endothelial cells and myofibroblasts accompany the granulation tissue remodeling.

A. Periodontal Regeneration

Regenerative periodontal therapy comprises procedures which are specially designed to restore those parts of the tooth supporting apparatus which have been lost by periodontitis. Regeneration is defined as a reproduction or reconstruction of a lost/injured part in such a way that the architecture and function of the lost or injured tissues are completely restored. The term “NEW ATTACHMENT” was preferred in the situation where the fibrous attachment was restored on a root surface deprived of its connective tissue attachment due to progression of periodontitis.

Periodontal regeneration has been reported following a variety of surgical approaches involving root surface biomodification, often combined with coronally advanced flap procedures, the placement of bone grafts or bone substitute implants or the use of organic or synthetic barrier membranes (GTR). There is evidence that the progenitor cells for the reformation of the lost periodontal attachment are present in the periodontal ligament. Consequently, a periodontal regenerative procedure needs to encourage the repopulation of the previous periodontitis affected root surface with cells from the periodontal ligament. These cells differentiate to form the fibroblasts which in turn form the new attachment. Thus for both wound healing and regeneration, the role of fibroblasts is inevitable.

B. Orthodontic Tooth Movement And Treatment Relapse³

In spite of precise diagnoses and the use of sophisticated mechanical systems, the response of the periodontium to force application varies between patients. Orthodontic treatments frequently lead to post-treatment relapse, particularly rotational relapse. In this context, we note that the collagen fibers of the periodontium are remodeled by fibroblasts in response to applied force. Following significant tooth rotation, the re-orientation of the collagen fibers in the gingival and transseptal region is histologically and clinically slower than that of periodontal ligament collagen fibers, perhaps reflecting the much slower collagen turnover that is exhibited by gingiva. Therefore, within the collagenous matrices of the periodontium of an individual tooth, there is a heterogeneous remodeling response. This has led to the practice of sectioning the circumferential gingival fibers as a means of reducing, by up to 50%, the amount of rotational relapse experienced in the correction of severe rotations. The differences between tissue responses in the gingival and periodontal ligament/bone tissue compartments are also exemplified by studies of glycosaminoglycans in gingival crevicular fluid.

Glycosaminoglycan components from the extracellular matrix, possible representative markers of bone matrix turnover, are augmented by orthodontic tooth movement and reduced by prolongation of fixed retention at the end of orthodontic treatment. The heterogeneity of matrix synthesis by various fibroblast subpopulations may be a consequence of signals from extracellular matrix component. Therefore, one possible consequence of force application during orthodontic treatment in the absence of adequate retention programs may be to increase the variation of the tissue response that is already in place. Consequently, a more detailed understanding of the effects of force on discrete cell populations could strengthen the rationale of retention programs and thereby improve orthodontic post-treatment management.

C. Role Of Fibroblasts In Drug Distribution

- 1) *Ciprofloxacin and Minocycline*⁴⁷: Human gingival fibroblasts express saturable transporters that allow them to take up extracellular fluoroquinolones and tetracyclines and act as reservoirs for these agents in the gingiva. Although the affinity is relatively low, fibroblasts do accumulate remarkable amount of minocycline and ciprofloxacin. The observed cellular/extracellular concentration (C/E) ratios was 60 for minocycline and more than 8 for ciprofloxacin. Consistent with these observations, the efficiency of minocycline transport (assessed by V_{max}/K_m) is about six times higher than for ciprofloxacin. Minocycline's K_m for transport is half that of ciprofloxacin and its transport velocity is approximately three times higher. Transporters are capable of moving their substrates in the forward or reverse direction to maintain equilibrium between intracellular and extracellular concentrations. For this reason, intracellular stores of ciprofloxacin and minocycline move out of gingival fibroblasts when their concentrations decrease in the extracellular medium. During antimicrobial therapy *in vivo*, forward transport predominates during periods in which these agents are increasing or peaking in the blood (typically 2 to 3 hrs after administration). The existence of a drug reservoir in the gingiva could explain why tetracycline ([Gordon et al., 1981](#)), doxycycline ([Pascale et al., 1986](#)), minocycline ([Ciancio et al., 1980](#)), and ciprofloxacin ([Conway et al., 2000](#)) appear to reach higher levels in GF than in blood serum *after* blood levels have receded their peak values. It could also account for the findings of [Sakellari et al. \(2000\)](#), who found higher levels of tetracycline, doxycycline, and minocycline in blood than in GF. Their blood and GF samples were obtained 2 hrs after oral administration, which coincides with or precedes the time of peak blood levels. Gingival fibroblasts has an ability to accumulate high levels of these agents may enhance their redistribution from the bloodstream to the gingiva and contribute to increased antibiotic levels in GF.
- 2) *Non-steroidal Anti-inflammatory Drugs*⁴⁸: Gingival fibroblasts express cyclo-oxygenase and produce prostaglandins, so they are a logical target for the treatment of gingival pain and inflammatory periodontitis. Gingival fibroblasts possess a transport system that takes up and concentrates NSAIDs inside these cells. This transporter could be a member of the organic anion transporter family. Its activity is significantly upregulated by TNF- α , through a mechanism that could potentially involve protein kinase C. Fibroblasts comprise a relatively small fraction of healthy gingival connective tissue, and the K_m of NSAID transport is relatively high. Thus, the impact of this transport system on peak NSAID levels may be somewhat limited in healthy gingiva. In inflamed gingiva, the volume of the fibroblast compartment is three times larger, and NSAID accumulation by fibroblasts may be significantly up-regulated by TNF- α . It is therefore feasible that fibroblast NSAID transport could materially influence NSAID levels attained at inflamed periodontal sites.
- 3) *Metronidazole*⁴⁹: Metronidazole concentrations in the GCF, uterus, pancreas, peritoneal fluid, and saliva are about equal to the plasma level and it can penetrate the blood-brain barrier, with a ratio of metronidazole concentration in cerebrospinal fluid to plasma >90%. The ratio of the intracellular concentration of metronidazole to the extracellular concentration reached 0.85:1 within 1 minute after the PMNs were incubated with metronidazole solution; the intracellular concentration of metronidazole was about equal to the extracellular concentration within 15 minutes. These phenomena suggest that metronidazole enters other tissues and cells by simple diffusion as well. Clinical and microbiologic resistance to metronidazole has rarely been described. This suggests that the strong penetrability of metronidazole and the simple diffusion of metronidazole entering pathogens are the reasons for the rare resistance because there are no transporters in cellmembranes to limit its entry. HGFs take up metronidazole in an unsaturable manner, and intracellular metronidazole concentrations increased linearly with increases in extracellular levels. This finding shows that the uptake of metronidazole by HGFs was consistent with a first-order kinetic process. Metronidazole rapidly enters HGFs by simple diffusion. It is easy for metronidazole to reach the minimal inhibitory concentration (MIC) in fibroblasts and gingiva when the metronidazole concentration in plasma reaches the MIC. Thus, metronidazole is a preferred drug in the treatment of gingivitis and periodontal diseases.

IV. RECEPTORS ON FIBROBLASTS FOR SEX HORMONES

Specific nuclear localization of [3H] estradiol was found predominantly in basal and spinous layers of gingival epithelium, stromal connective tissue cells (fibroblasts), and endothelial cells and pericytes of small blood vessels in the lamina propria. These results provide the direct evidence that human gingiva may function as a target organ for estrogens.⁵⁰

V. STUDIES ON FIBROBLASTS ATTACHMENT AND PROLIFERATION

The biocompatibility of the root surface after any periodontal treatment is the key issue for adequate periodontal healing. Hence, the attachment of fibroblasts on to the root surface after various treatments was evaluated to assess the rate of healing after that particular treatment.

Studies assessing the attachment of fibroblasts on to the root surface after scaling and root planning with hand instruments⁵¹ in the early 1980's to the attachment of fibroblasts on to the root surface after LASER treatment (Nd: YAG⁵², Er: YAG⁵³) in early 21 century have consistently shown the prime importance of the attachment of fibroblasts to the root surface for adequate healing and regeneration. Various studies^{54,55,56} on the attachment of fibroblasts on to the root surface after treatment with a variety of root conditioning agents have shown the advantages of root conditioning after SRP in terms of better periodontal healing. However studies^{57,58} testing the biocompatibility of root surfaces after treatment with various mouthrinses have consistently shown the toxic effects of these antiseptics on the host cells. The fibroblast attachment and proliferation on root surfaces were also observed with collagen binding peptide P-15 and hydroxyapatite as bone replacement graft materials.^{59,60} The effects of cemental matrix⁶¹ and cementum attachment protein⁶² on PDL cell and fibroblast were also evaluated. The toxic effects of nicotine on fibroblasts⁶³ were also studied.

VI. CONCLUSION

The principal cell in the lamina propria of oral mucosa and the periodontal ligament is the fibroblast, which is responsible for the elaboration and the turnover of fibres and ground substance. The fibroblast thus plays a key role in maintaining tissue integrity. The fibroblasts are cigar-shaped (fusiform) or star shaped (stellate) with long processes that tend to lie parallel to bundles of collagen fibers and are not easily visible with the light microscope. Ultrastructurally the fibroblasts have the characteristics of active synthetic cells, including numerous mitochondria, an extensive granular endoplasmic reticulum, a prominent golgi complex and numerous membrane bound vesicles.

REFERENCES

- [1] Ten Cate AR. Oral Histology: Development, Structure and Form 1994 Mosby-Year Book: St Louis, pp 7-8,61,109
- [2] Birkadel-Hansen H. Role of matrix metalloproteinases in human periodontal diseases. J Periodontol 1993 64: 474-484.
- [3] P.C.Lekic, N.Pender C.A.G, McCulloch. Is fibroblast heterogeneity relevant to the health, diseases and treatments of periodontal tissues? Crit Rev Oral Biol Med 1997;8(3):253-268
- [4] P.Mark Bartold, Laurence J. Walsh and A. Sampath Narayanan. Molecular and cell biology of gingiva. Periodontology 2000, 2000; vol 24:28-55.
- [5] Berkowitz,B.M.B. Holland,G.R. and Moxham,B.J. A colour atlas and textbook of oral anatomy, histology and embryology, 2 ed .London: Wolfe publishing Ltd, 1992, pp 172-174,182-183.
- [6] B.M.Eley and J.D.Manson. Periodontics (textbook) 5 ed. Toronto 2004, Wright publishers, printed in china pp 7,13,69,75
- [7] Berkowitz,B.M.B, Moxham,B.J. and Newman,H.N. Periodontal ligament in health and disease , 2 ed,1995,Barcelona:Mosby-Wolfe pp 4
- [8] Angelo M. The extracellular matrix of the periodontium: dynamic and interactive tissues. Periodontology 2000, 1993; 3:39-63.
- [9] Iribe H, Koga T, Kotani S, Kusumoto S, Shiba T. Stimulating effect of MDP and its adjuvant-active analogues on guinea pig fibroblasts for the production of thymocyte-activating factor. J Exp Med 1983, 157:2190-2195.
- [10] Mackenzie I. Epithelial-mesenchymal interactions in the development and maintenance of epithelial tissues. In: Leigh IM, Lane EB, Watt FM, eds. The keratinocyte handbook.1994 Anbridge University Press: Cambridge, pp 243-258.
- [11] S.Murakami and H.Okada. Lymphocyte- Fibroblasts Interactions Crit Rev oral biol Med 1997;8(1):40-50
- [12] Sappino AP, Schurch W, Gabbiani G. Differentiation repertoire of fibroblastic cells: expression of cytoskeletal proteins as a marker of phenotypic modulations. Lab Invest 1990, 63: 144- 161.
- [13] Roberts WE, Chamberlain JG. Scanning electron microscopy of the cellular elements of rat periodontal ligament. Arch Oral Biol 1978, 23: 587-589.
- [14] Cockey GH, Boughman JA, Harris EL et al. Genetic control of variation in human gingival fibroblast proliferation rate. In Vitro Cellul Dev 1989, 15: 255-258.
- [15] Irwin CR, Picardo M, Ellis et al. Inter- and intra-site heterogeneity in the expression of fetal-like phenotypic characteristics by gingival fibroblasts: potential significance for wound healing. J Cell Sci 1994, 107: 1333-1346.
- [16] Bordin S, Page RC, Narayanan AS. Heterogeneity of normal human diploid fibroblasts: isolation and characterization of one phenotype. Science 1984, 223: 171-173.
- [17] Hassell TM, Stanek EJ. Evidence that healthy human gingiva contains functionally heterogeneous fibroblast subpopulations. Arch Oral Biol 1983, 28:617-625.
- [18] Pender N, McCulloch CAG. Quantitation of actin polymerization in two human fibroblast sub-types responding to mechanical stretching. J Cell Sci 1991, 100:187-193.
- [19] Rose GG, Yamasaki A, Pinerio G, Mahan CI .Human periodontal ligament cells in vitro. J Periodont Res 1987, 22:20-28.

- [20] Larjava H, Sandberg M, Vuorio E. Altered distribution of type I collagen mRNA in periodontal disease. *J Periodont Res* 1989, 24:171-177.
- [21] Hou L-T, Yaeger JA. Cloning and characterization of human gingival and periodontal ligament fibroblasts. *J Periodontol* 1993, 64:1209-1218.
- [22] Matsuda N, Kumar NM, Ramakrishnan PR, Lin W-L, Genco RJ, Cho MI. Evidence for up-regulation of epidermal growth-factor receptors on rat periodontal ligament fibroblastic cells associated with stabilization of phenotype in vitro. *Arch Oral Biol* 1993, 38:559-569.
- [23] Okada H, Kida T, Yamagami H. Identification and distribution of immunocompetent cells in inflamed gingiva of human chronic periodontitis. *Infect Immun* 1983, 41:365-374.
- [24] Giannopoulou C, Cimasoni G. Functional characteristics of gingival and periodontal ligament fibroblasts. *J Dent Res* 1996, 75:895-902.
- [25] Groeneveld MC, Everts V, Beertsen W. Alkaline phosphatase activity in the periodontal ligament and gingiva of the rat molar: its relation to cementum formation. *J Dent Res* 1995, 74:1374-1381.
- [26] Boyko G, Melcher AH, Brunette DM. Formation of new periodontal ligament by periodontal ligament cells implanted in vivo after culture in vitro. *J Periodont Res* 1981, 16:73-88.
- [27] Pitaru S, Narayanan AS, Olson S, Savion N, Hekmati H. Specific cementum attachment protein enhances selectively the attachment and migration of periodontal cells to root surfaces. *J Periodont Res* 1995,30:360-368.
- [28] Somerman MI, Foster RA, Imm GR, Sauk JI, Archer SY. Periodontal ligament cells and gingival fibroblasts respond differently to attachment factors in vitro. *J Periodontol* 1989, 60:73-77.
- [29] SL Schor', I Ellis', CR Irwin2, J Banyard', K Seneviratne', C Dolman', AD Gilbert', DM Chisholm. Proceedings of the Symposium at University College Cork, September 1995 "Cell Biology of the Periodontium in Health and Disease" Subpopulations of fetal-like gingival fibroblasts: characterisation and potential significance for wound healing and the progression of periodontal disease *Oral Diseases* 1996, 2: 155-166
- [30] Mast BA, Diegelmann RF, Krummel TM et al. Scarless wound healing in the mammalian fetus. *Surg Gynecol Obstet* 1992, 174: 441-451.
- [31] Shafer WG, Hine MK, Levy BM (1974). A textbook of oral pathology. WB Saunders: Philadelphia, pp 542-563.
- [32] Estes JM, VandeBerg JS, Adzick NS et al. Phenotypic and functional features of myofibroblasts in sheep fetal wounds. *Differenriation* 1994, 56: 173- 181.
- [33] Sullivan KM, Lorenz HP, Adzick NS. The role of transforming growth factor beta in human fetal wound healing. *Surg F o r m* 1993, 44: 625-627.
- [34] Krummel TM, Nelson JM, Diegelmann RF et al. Fetal response to injury in the rabbit. *J Pediatr Surg* 1987, 22: 640-644.
- [35] Martin P, Lewis J. Actin cables and epidermal movement in embryonic wound healing. *Nature* 1992, 360: 179-183.
- [36] Schor SL, Schor AM, Grey AM et al. Fetal and cancer patient fibroblasts produce an autocrine migration stimulating factor not made by normal adult cells. *J Cell Sci* 1988, 90: 391-399.
- [37] Lorenz HP, Longaker MT, Perkocha LA et al.. Scarless wound repair: a human fetal skin model. *Development* 1992, 114:253-259
- [38] Moxham BJ, Berkovitz BKB, Shore RC. Is the periodontal ligament a foetal connective tissue? *INSERM* 1984,125: 557-564.
- [39] Moxham BJ, Grant DA. Development of the periodontal ligament. In: Berkovitz BKB, Moxham BJ, Newman HN, eds. *The periodontal ligament in health and disease*. Mosby-Wolfe: London, 1995, pp 161-181.
- [40] Leblond CP, Messier B, Kopriwa B. Thymidine-H3 as a tool for the investigation of the renewal of cell populations. *Lab Invest* 1959, 8:296-306.
- [41] Gould TRL, Melcher AH, Brunette DM. Migration and division of progenitor cell populations in periodontal ligament after wounding. *Periodont Res* 1980, 15:20- 42.
- [42] McCulloch CAG, Melcher AM. Cell migration in the periodontal ligament of mice. *J Periodont Res* 1983, 18:339-352.
- [43] Pender N, Heaney TG. Cell generation within the interdental gingival septum of the rat. *J Periodont Res* 1994, 29 17-24.
- [44] McCulloch CAG, Knowles G. Discrimination of two fibroblast progenitor populations in early explant cultures of hamster gingiva. *Cell Tissue Res* 1991, 264:87-94.
- [45] Giuseppe Polimeni, Andreas V. Xiropaidis & Ulf M. E. Wikesjo. Biology and principles of periodontal wound healing/regeneration *Periodontology* 2000, Vol. 41, 2006, 30-47
- [46] Clark RAF Wound Repair. In Clark RAF (ed):*The molecular and cell biology of wound repair*, 2nd ed, New York, Plenum Press, 1996, Pg. 3-50 .
- [47] Q. Yang, R.J. Nakkula, and J.D. Walters. Accumulation of Ciprofloxacin and Minocycline by Cultured Human Gingival Fibroblasts *J dent res* December 2002, 81: 836-840.
- [48] M.M. Zavarella, O. Gbemi, and J.D. Walters Accumulation of Non-steroidal Anti-inflammatory Drugs by Gingival Fibroblasts *J dent res* May 2006, 85: 452-45.
- [49] Liqiang Yu, Hongchen Liu, Lingling E, Xia Wu, Dongsheng Wang. Uptake of Metronidazole by Human Gingival Fibroblasts *Journal of Periodontology* 13 Feb 2009: 993-998.
- [50] Vitteck J, Hernandez MR, Wenk EJ, Rappaport SC, Southren AL. Specific estrogen receptors in human gingiva. *J Clin Endocrinol Metab.* 1982 Mar;54(3):608-12
- [51] Nishimura K, Takada K, Noguchi Y, Yamaoka A. Gingival fibroblasts and tissues attachment to curretted cementum surface in periodontally involved teeth. *J Electron Microscop (Tokyo)*. 1989; 38(1):16-23.
- [52] Trylovich DJ, Cobb CM, Pippin DJ, Spencer P, Killoy WJ. The effects of the Nd:YAG laser on in vitro fibroblast attachment to endotoxin-treated root surfaces. *J Periodontol.* 1992 Jul; 63(7):626-32.
- [53] Crespi R, Romanos GE, Cassinelli C, Gherlone E. Effects of Er:YAG laser and ultrasonic treatment on fibroblast attachment to root surfaces: an in vitro study. *J Periodontol.* 2006 Jul; 77(7):1217-22.
- [54] Chandra RV, Jagetia GC, Bhat KM. The attachment of V79 and human periodontal ligament fibroblasts on periodontally involved root surfaces following treatment with EDTA, citric acid, or tetracycline HCL: an SEM in vitro study. *J Contemp Dent Pract.* 2006 Feb 15; 7(1):44-59.
- [55] Babay N, Mokeem S. The effect of two different demineralization methods with saturated tetracycline hydrochloride on the attachment and growth of gingival fibroblasts. A scanning electron microscopic study. *Odontostomatol Trop.* 2005 Mar; 28(109):33-8.
- [56] Gamal AY, Mailhot JM. The effects of EDTA gel conditioning exposure time on periodontitis-affected human root surfaces: surface topography and PDL cell adhesion. *J Int Acad Periodontol.* 2003 Jan; 5(1):11-22.
- [57] Alleyn CD, O'Neal RB, Strong SL, Scheidt MJ et al. The effects of Chlorhexidine treatment of root surfaces on the attachment of the human gingival fibroblasts in vitro. *J Periodontology* 1991; 62:434-438.



- [58] Cline NV, Layman DL. The effects of Chlorhexidine on the attachment and growth of cultured human periodontal cells. *J Periodontol* 1992; 63:598-602.
- [59] Lallier TE, Palaiologou AA, Yukna RA, Layman DL. The putative collagen-binding peptide P-15 promotes fibroblast attachment to root shavings but not hydroxyapatite. *J Periodontol*. 2003 Apr; 74(4):458-67.
- [60] Lallier TE, Yukna R, St Marie S, Moses R. The putative collagen binding peptide hastens periodontal ligament cell attachment to bone replacement graft materials. *J Periodontol*. 2001 Aug; 72(8):990-7.
- [61] Davenport DR, Mailhot JM, Wataha JC, Billman MA, Sharawy MM, Shrout MK. Effects of enamel matrix protein application on the viability, proliferation, and attachment of human periodontal ligament fibroblasts to diseased root surfaces in vitro. *J Clin Periodontol*. 2003 Feb; 30(2):125-31.
- [62] Pitaru S, Narayanan SA, Olson S, Savion N, Hekmati H, Alt I, Metzger Z Specific cementum attachment protein enhances selectively the attachment and migration of periodontal cells to root surfaces. *J Periodontal Res*. 1995 Sep; 30(5):360-8.
- [63] Tanur E, McQuade MJ, McPherson JC, Al-Hashimi IH, Rivera-Hidalgo F. Effects of nicotine on the strength of attachment of gingival fibroblasts to glass and non-diseased human root surfaces. *J Periodontol* 2000 May; 71(5):717-22.



10.22214/IJRASET



45.98



IMPACT FACTOR:
7.129



IMPACT FACTOR:
7.429



INTERNATIONAL JOURNAL FOR RESEARCH

IN APPLIED SCIENCE & ENGINEERING TECHNOLOGY

Call : 08813907089  (24*7 Support on Whatsapp)